

PATIENT

Star Beach

SPECIES

Feline

BREED

DSH

SEX

Spayed Female

AGE

~ 7 Years

WEIGHT

10.8 pounds

INTERPRETED BY

Sara Brethel, DVM,
 DACVIM (Cardiology)

IMAGING PERFORMED BY

Sara Hansen

HOSPITAL NAME

VCA McKenzie Animal
 Hospital

REFERRING VET

Dr. Michlanski

INVOICE

14580

DATE

03/24/26

PRESENTING CLINICAL SIGNS

Clinical Exam Findings: Exam WNL aside from minimal dander, slightly overweight. No murmur or arrhythmia. P presented for routine dental on 3/18/26. Pre-op ECG WNL. Pre-medicated with dexmedetomidine and methadone, induced anesthesia with propofol. VPCs began to occur frequently during initial anesthesia monitoring. Initially 3-5 VPCs in a row broken up by 5-10 normal sinus beats, then progressed to almost entirely VPCs. No response to antisedan. Blood pressure began to drop rapidly, P woken up from anesthesia and recovered quickly, blood pressure had normalized within 5 minutes of waking from anesthesia.

ABNORMAL Labwork Values: Cholesterol 296 (75-220), mild lymphopenia (1196)

For ECHO Only: Blood Pressure: 151/103 (111)

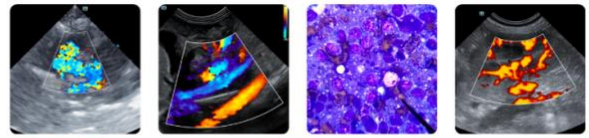
HR/RR/BP: Will obtain at time of echo

ULTRASONOGRAPHIC EXAMINATION OF THE HEART

FELINE CARDIAC PARAMETERS	BODY WEIGHT (kg)	HR (BPM)	IVSd (cm)	LVIDd (cm)	LVWd (cm)	FS (%)	EF (%)
NORMAL PARAMETER	-----	150-240	0.3-0.6	1.0-2.1	0.25-0.6	35-67	80-100
PATIENT	4.9	NM	0.36	1.2	0.46	46.66	--
FELINE CARDIAC PARAMETERS	LA/AO (M-mode)	LA/AO HEART BASE (Sisson)	LAD LA MAX 4 Chamber	LVOT VEL. (m/s)	RVOT VEL. (m/s)	LVIDs (m/)	
NORMAL PARAMETER	<1.5	1.6	0.7-1.7	<1.6	<1.3		
PATIENT	1.2	1.47	NM	0.71	0.95	0.64	
Adapted from June Boon, Veterinary Echocardiography, 1998 Sisson D et al. JVIM 1991; 5: 232, Jacobs et al. Am J Vet Res 1985; 46:1705							

Cardiac Presentation

The mitral valve leaflets are normal and there is no mitral regurgitation. The left atrial size is normal. There is no evidence of systolic anterior motion of the mitral valve and no evidence of a left ventricular outflow tract obstruction. Left ventricular systolic and diastolic function is within normal limits. There is no evidence of left ventricular concentric hypertrophy. There is normal right atrial size without evidence of tricuspid regurgitation. There is no prolapse of the tricuspid valve leaflets and no evidence of pulmonary hypertension on the images provided. The right ventricle appears normal in structure and function subjectively. The aortic and pulmonic valves have normal morphology and the corresponding outflow velocities are within normal limits. There is no evidence of pulmonic or aortic insufficiency. The aorta appears normal. The pulmonary artery and associated branches appear normal. There is no evidence of pleural effusion, pericardial effusion, or intracardiac masses.



PATIENT

Star Beach

SPECIES

Feline

BREED

DSH

SEX

Spayed Female

AGE

~ 7 Years

WEIGHT

10.8 pounds

INTERPRETED BY

Sara Brethel, DVM,
DACVIM (Cardiology)

IMAGING PERFORMED BY

Sara Hansen

HOSPITAL NAME

VCA McKenzie Animal
Hospital

REFERRING VET

Dr. Michlanski

INVOICE

14580

DATE

03/24/26

ECG

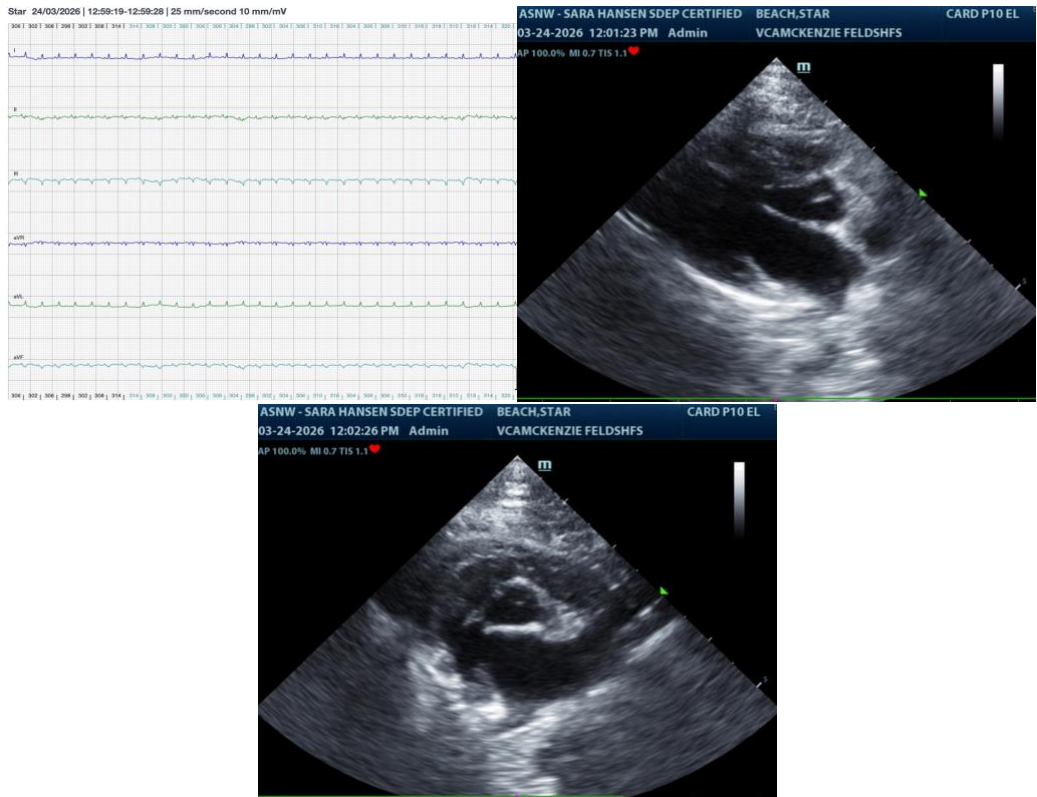
Normal sinus rhythm.

ULTRASONOGRAPHIC FINDINGS

- Structurally and functionally normal heart.

INTERPRETATION OF THE FINDINGS & FURTHER RECOMMENDATIONS

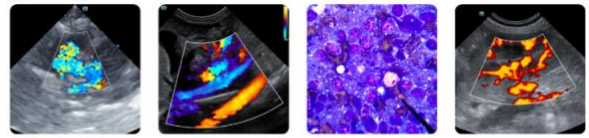
The heart is structurally normal. The cause of the ventricular premature complexes identified under anesthesia is unknown. In the future I would recommend avoiding dexmedetomidine for this patient, propofol can sometimes also cause ventricular premature complexes. Recommend ensuring the patient is euthyroid and normotensive as well. Recheck echo is not needed unless the patient develops persistent arrhythmias or develops a heart murmur or develops signs of cardiovascular disease.



The information and recommendations provided are based on the images presented by the referring veterinarian/sonographer. No evaluation can be communicated regarding pathology that was not visible in the image/video clips provided.

Thank you for this referral. If the clinical or image interpretation does not parallel your findings or if I can be of any further assistance please contact me.

Sara Brethel, DVM, DACVIM (Cardiology)



PATIENT

info@SonoPath.com

Star Beach

SPECIES

Feline

BREED

DSH

SEX

Spayed Female

AGE

~ 7 Years

WEIGHT

10.8 pounds

INTERPRETED BY

Sara Brethel, DVM,
DACVIM (Cardiology)

**IMAGING
PERFORMED BY**

Sara Hansen

HOSPITAL NAME

VCA McKenzie Animal
Hospital

REFERRING VET

Dr. Michlanski

INVOICE

14580

DATE

03/24/26