

PATIENT

Lillian Boyd

SPECIES

Canine

BREED

Chihuahua

SEX

Intact Female

AGE

5 Months

WEIGHT

5.6 pounds

INTERPRETED BY

Sara Brethel DVM,
DACVIM (Cardiology)

IMAGING PERFORMED BY

Sara Hansen

HOSPITAL NAME

Faithful Friends Animal
Clinic

REFERRING VET

Dr. Rideout

INVOICE

14579

DATE

03/24/26

PRESENTING CLINICAL SIGNS

On presentation for vaccines, a low-grade murmur was noted. Initial grading was 1/6, subsequent grading here by another DVM was 2-3/6

Breeder requested second opinion, and pup was taken to E-clinic where murmur was graded as 1/6. Otherwise, pup is BAR, healthy

Is there a Heart Murmur? If so, please grade: 1/6

Current Medications: Flea control, dewormer

Notes to Specialist (if any): We are planning for OHE anesthesia. Suspect VSD?

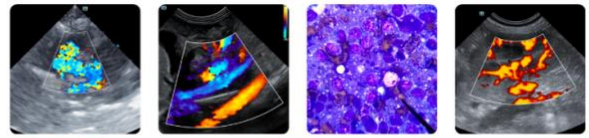
ULTRASONOGRAPHIC EXAMINATION OF THE HEART

| CANINE CARDIAC PARAMETERS | MR VMAX (m/s) | TR VMAX (m/s) | LA/AO (M-Mode) | LA/AO (Heart Base; Swe) | FS (%) | EF (%) | EPSS (cm) |
|----------------------------------|----------------------|----------------------|-----------------------|--------------------------------|-----------------------------|---|---|
| NORMAL PARAMETER | 4.5-5.5 | <2.7 | 1.3 | Up to 1.6 | 28-40 | 40-100 | <0.6 |
| PATIENT | -- | -- | 1.18 | 1.29 | 38.88 | -- | NM |
| CANINE CARDIAC PARAMETERS | HR (BPM) | AV VMAX (m/s) | PV MAX (m/s) | BODY WEIGHT (kg) | LAD LA MAX 4 Chamber | LVIDd Avg; 2D and m-mode short axis (cm) | LVIDs Avg; 2D and m-mode short axis (cm) |
| NORMAL PARAMETER | 50-100 | 0.7-1.7 | 0.7-1.6 | | | | |
| PATIENT | NM | 1.41 | 1.57 | 2.54 | -- | 1.8 | 1.1 |

Cardiac Presentation

The mitral valve leaflets are normal and there is no mitral regurgitation. There is no prolapse of the mitral valve leaflets. The left atrial size is normal. Left ventricular systolic and diastolic function is within normal limits. There is normal right atrial size without evidence of tricuspid regurgitation. There is no prolapse of the tricuspid valve leaflets and no evidence of pulmonary hypertension on today's evaluation. The right ventricle subjectively appears normal in structure and function. The aortic and pulmonic valves have normal morphology and the corresponding outflow velocities are within normal limits. There is no evidence of pulmonic or aortic insufficiency. The aorta appears normal. The pulmonary artery and associated branches appear normal. There is no evidence of pleural effusion, pericardial effusion, or intracardiac masses.

ECG



PATIENT

Normal sinus rhythm.

Lillian Boyd

ULTRASONOGRAPHIC FINDINGS

SPECIES

- Structurally normal heart.

Canine

INTERPRETATION OF THE FINDINGS & FURTHER RECOMMENDATIONS

BREED

The heart appears structurally normal. No congenital defects are identified in the images provided. No cause of the murmur is seen. If the murmur persists for when the patient is full grown in a year of age, a recheck echo would be recommended at that time.

Chihuahua

SEX

There does not appear to be any contraindications to anesthesia. To be cautious, I would recommend avoiding alpha 2 agonists such as Dexmedetomidine and ketamine for this patient.

Intact Female

AGE

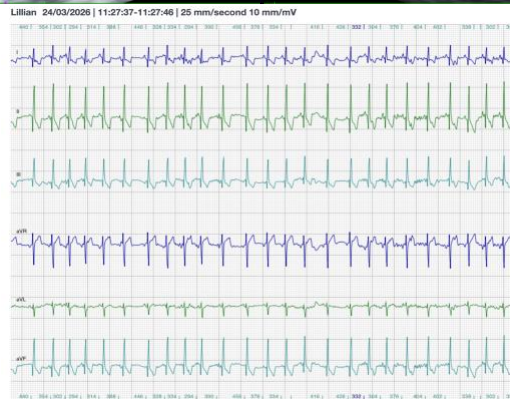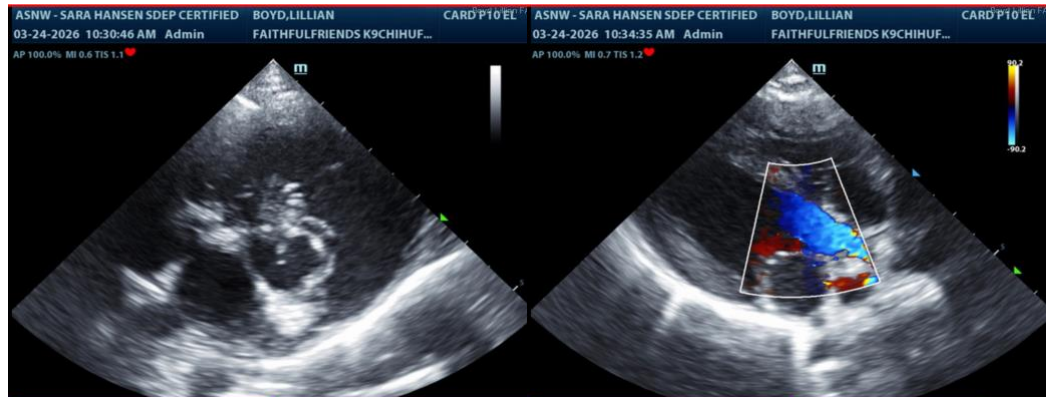
5 Months

WEIGHT

5.6 pounds

INTERPRETED BY

Sara Brethel DVM,
 DACVIM (Cardiology)



IMAGING PERFORMED BY

Sara Hansen

HOSPITAL NAME

Faithful Friends Animal
 Clinic

REFERRING VET

Dr. Rideout

INVOICE

14579

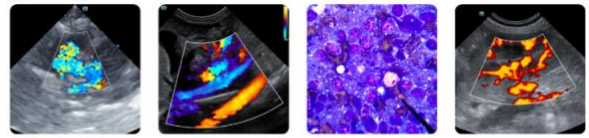
The information and recommendations provided are based on the images presented by the referring veterinarian/sonographer. No evaluation can be communicated regarding pathology that was not visible in the image/video clips provided.

DATE

03/24/26

Thank you for this referral. If the clinical or image interpretation does not parallel your findings or if I can be of any further assistance please contact me.

Sara Brethel DVM, DACVIM (Cardiology)



PATIENT

info@SonoPath.com

Lillian Boyd

SPECIES

Canine

BREED

Chihuahua

SEX

Intact Female

AGE

5 Months

WEIGHT

5.6 pounds

INTERPRETED BY

Sara Brethel DVM,
DACVIM (Cardiology)

**IMAGING
PERFORMED BY**

Sara Hansen

HOSPITAL NAME

Faithful Friends Animal
Clinic

REFERRING VET

Dr. Rideout

INVOICE

14579

DATE

03/24/26