



PATIENT

Cheddarbob Van Lier

SPECIES

Feline

BREED

DSH

SEX

Neutered Male

AGE

4 Years

WEIGHT

9.68 Pounds

INTERPRETED BY

Sara Brethel DVM,
 DACVIM (Cardiology)

IMAGING PERFORMED BY

Sara Hansen

HOSPITAL NAME

Hello Vet for Pets WC

REFERRING VET

Dr. Christensen

INVOICE

36272

DATE

3/17/26

PRESENTING CLINICAL SIGNS

Clinical Exam Findings:

- Cardiovascular: Regular rhythm; grade 3 systolic murmur
- Hx of HCM

ABNORMAL Labwork Values:

- Elevated ProBNP from 10/13/2025 (356)

HR/RR/BP:

- HR: 160 RR: 24

Is there a Heart Murmur? If so, please grade:

- 3/6

Current Medications:

- Gabapentin

ULTRASONOGRAPHIC EXAMINATION OF THE HEART

FELINE CARDIAC PARAMETERS	BODY WEIGHT (kg)	HR (BPM)	IVSd (cm)	LVIDd (cm)	LVWd (cm)	FS (%)	EF (%)
NORMAL PARAMETER	-----	150-240	0.3-0.6	1.0-2.1	0.25-0.6	35-67	80-100
PATIENT	4.4	NM	0.46	1.25	0.66	52	--
FELINE CARDIAC PARAMETERS	LA/AO (M-mode)	LA/AO HEART BASE (Sisson)	LAD LA MAX 4 Chamber		LVOT VEL. (m/s)	RVOT VEL. (m/s)	IVRT (m/)
NORMAL PARAMETER	<1.5	1.6	0.7-1.7		<1.6	<1.3	40-60
PATIENT	1.05	1.03	--		Underest	0.75	NM

Adapted from June Boon, Veterinary Echocardiography, 1998
 Sisson D et al. JVIM 1991; 5: 232, Jacobs et al. Am J Vet Res 1985; 46:1705

LVIDs: 0.6 ****No other measurements obtained.**

ECG Interpretation



PATIENT

Sinus rhythm

Cheddarbob Van Lier

Cardiac Presentation

SPECIES

Feline

BREED

DSH

SEX

Neutered Male

AGE

4 Years

WEIGHT

9.68 Pounds

The mitral valve leaflets are normal and there is mild mitral regurgitation. There is no prolapse of the mitral valve leaflets. The left atrial size is within normal limits. Left ventricular systolic function appears preserved. Left ventricular diastolic dimensions are within normal limits. There is evidence of systolic anterior motion of the mitral valve and there is a discrete step up in velocities through the left ventricular outflow tract. There is evidence of a kissing lesion at the level of SAM, and the left ventricular myocardium appears hyperechoic in some regions. Left ventricular walls measure hypertrophied. There is normal right atrial size without evidence of tricuspid regurgitation. There is no prolapse of the tricuspid valve leaflets and no evidence of pulmonary hypertension on the images provided. The right ventricle appears normal in structure and function subjectively. The aortic and pulmonic valves have normal morphology and the corresponding outflow velocities are within normal limits. There is no evidence of pulmonic or aortic insufficiency. The aorta appears normal. The pulmonary artery and associated branches appear normal. There is no evidence of pleural effusion, pericardial effusion, or intracardiac masses.

ULTRASONOGRAPHIC FINDINGS

- Hypertrophic obstructive cardiomyopathy
- Normal left atrial size,

INTERPRETED BY

Sara Brethel DVM,
DACVIM (Cardiology)

IMAGING PERFORMED BY

Sara Hansen

HOSPITAL NAME

Hello Vet for Pets WC

REFERRING VET

Dr. Christensen

INVOICE

36272

DATE

3/17/26

INTERPRETATION OF THE FINDINGS & FURTHER RECOMMENDATIONS

The patient has evidence of left ventricular concentric hypertrophy and is classified as a stage B1 due to the normal left atrial size. If not already performed, it is recommended to ensure that patients' blood pressure is normal, and the patient is euthyroid. If the patient is euthyroid and normotensive, then the patient has underlying hypertrophic cardiomyopathy. No cardiac medications are indicated at this time as the patient is at a low risk for complications associated with this condition. Since this can be a progressive condition, serial monitoring is recommended. It's recommended to recheck an echocardiogram in 6 months, sooner if the patient develops cardiovascular clinical signs.

The patient has a mild obstructive component. Aortic outflow velocities appear underestimated, but in the absence of clinical signs, no therapies are recommended. Elective anesthetic procedures should be well-tolerated.

Standard perioperative fluid rates should be well-tolerated. Medications like dexmedetomidine and other alpha 2 agonists are best avoided. Ketamine is also best avoided. Anticholinergics can be used in the case of a clinically significant bradyarrhythmia (i.e., bradycardia with concurrent hypotension). If the patient is on an ACEi, recommend not giving this therapy the day of anesthesia.



PATIENT

Cheddarbob Van Lier

SPECIES

Feline

BREED

DSH

SEX

Neutered Male

AGE

4 Years

WEIGHT

9.68 Pounds

INTERPRETED BY

Sara Brethel DVM,
DACVIM (Cardiology)

IMAGING PERFORMED BY

Sara Hansen

HOSPITAL NAME

Hello Vet for Pets WC

REFERRING VET

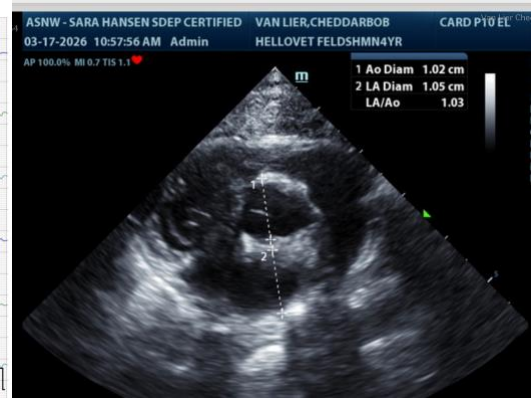
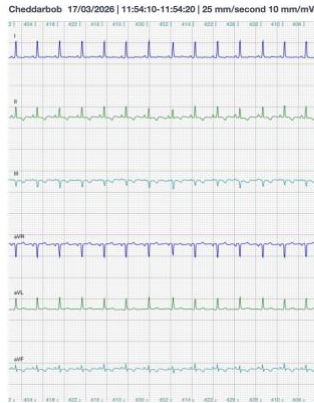
Dr. Christensen

INVOICE

36272

DATE

3/17/26



The information and recommendations provided are based on the images presented by the referring veterinarian/sonographer. No evaluation can be communicated regarding pathology that was not visible in the image/video clips provided.

Thank you for this referral. If the clinical or image interpretation does not parallel your findings or if I can be of any further assistance please contact me.

Sara Brethel DVM, DACVIM (Cardiology)

info@SonoPath.com