

PATIENT

Sydney Andrews

SPECIES

Feline

BREED

DMH

SEX

Spayed Female

AGE

15 Years

WEIGHT

10.63 Pounds

INTERPRETED BY

Sara Brethel DVM,
 DACVIM (Cardiology)

IMAGING PERFORMED BY

Andrea Nicastro, DVM,
 DACVIM

HOSPITAL NAME

Waterway AH

REFERRING VET

Dr. Walker

INVOICE

36811

DATE

2/11/26

PRESENTING CLINICAL SIGNS

- Elevated pro BNP, no murmur
- Meds: Solensia Injection, revolution plus, Terramycin ophth ointment
- Abnormal PE/Chem/CBC/UA Results: HR- 180. RR-20. BP- not recorded

ULTRASONOGRAPHIC EXAMINATION OF THE HEART

FELINE CARDIAC PARAMETERS	BODY WEIGHT (kg)	HR (BPM)	IVSd (cm)	LVIDd (cm)	LVWd (cm)	FS (%)	EF (%)
NORMAL PARAMETER	-----	150-240	0.3-0.6	1.0-2.1	0.25-0.6	35-67	80-100
PATIENT	4.83	NM	0.61	1.23	0.59	51.21	--
FELINE CARDIAC PARAMETERS	LA/AO (M-mode)	LA/AO HEART BASE (Sisson)	LAD LA MAX 4 Chamber		LVOT VEL. (m/s)	RVOT VEL. (m/s)	IVRT (m/)
NORMAL PARAMETER	<1.5	1.6	0.7-1.7		<1.6	<1.3	40-60
PATIENT	1.06	0.8	--		~1.0	~1.0	NM

Adapted from June Boon, Veterinary Echocardiography, 1998
 Sisson D et al. JVIM 1991; 5: 232, Jacobs et al. Am J Vet Res 1985; 46:1705

LVIDs: 0.6

Cardiac Presentation

The left atrium is within normal limits. The mitral valve leaflets are normal and there is no mitral regurgitation. There is no evidence of systolic anterior motion of the mitral valve and no evidence of a left ventricular outflow tract obstruction. There is concentric hypertrophy of the left ventricle. The right atrium is normal. The tricuspid valve is normal without evidence of tricuspid regurgitation. The right ventricle appears to have preserved systolic function subjectively. The aortic and pulmonic valves are normal without evidence of insufficiency. Aortic and pulmonic outflow velocities are within normal limits. The aorta and PA are normal along with the associated PA branches. There is no evidence of pleural effusion, pericardial effusion, or intracardiac masses.

ULTRASONOGRAPHIC FINDINGS

- Left ventricular concentric hypertrophy
- Normal left atrial size

INTERPRETATION OF THE FINDINGS & FURTHER RECOMMENDATIONS



PATIENT

Sydney Andrews

SPECIES

Feline

BREED

DMH

SEX

Spayed Female

AGE

15 Years

WEIGHT

10.63 Pounds

INTERPRETED BY

Sara Brethel DVM,
 DACVIM (Cardiology)

IMAGING PERFORMED BY

Andrea Nicastro, DVM,
 DACVIM

HOSPITAL NAME

Waterway AH

REFERRING VET

Dr. Walker

INVOICE

36811

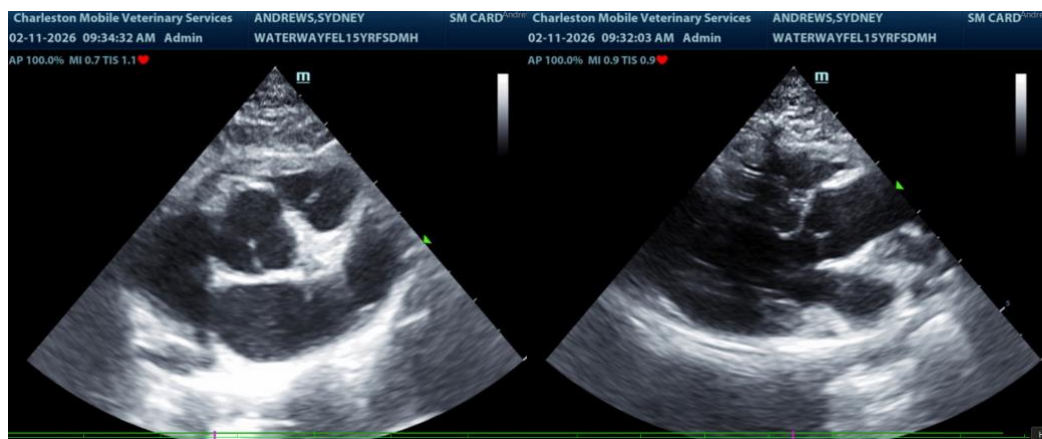
DATE

2/11/26

The patient has evidence of left ventricular concentric hypertrophy and is classified as a stage B1 due to the normal left atrial size. If not already performed, it is recommended to ensure that patient's blood pressure is normal, and the patient is euthyroid. If the patient is euthyroid and normotensive, then the patient has underlying hypertrophic cardiomyopathy. No cardiac medications are indicated at this time as the patient is at a low risk for complications associated with this condition. Since this can be a progressive condition, serial monitoring is recommended. It's recommended to recheck an echocardiogram in 6 months, sooner if the patient develops cardiovascular clinical signs.

Recommend obtaining a blood pressure on the patient to ensure it is <160mmHg. If the blood pressure is elevated recommend following ACVIM guidelines for systemic hypertension and treating if indicated.

Standard perioperative fluid rates should be well-tolerated. Medications like dexmedetomidine and other alpha 2 agonists are best avoided. Ketamine is also best avoided. Anticholinergics can be used in the case of a clinically significant bradyarrhythmia (i.e., bradycardia with concurrent hypotension). If the patient is on an ACEi, recommend not giving this therapy the day of anesthesia.



The information and recommendations provided are based on the images presented by the referring veterinarian/sonographer. No evaluation can be communicated regarding pathology that was not visible in the image/video clips provided.

Thank you for this referral. If the clinical or image interpretation does not parallel your findings or if I can be of any further assistance please contact me.

Sara Brethel DVM, DACVIM (Cardiology)

info@SonoPath.com