



**PATIENT**

Shelby Wofford

**SPECIES**

Canine

**BREED**

Australian Shepherd X

**SEX**

Spayed Female

**AGE**

12 Years

**WEIGHT**

42 Pounds

**INTERPRETED BY**

Sara Brethel, DVM,  
DACVIM (Cardiology)

**IMAGING PERFORMED BY**

Sara Hansen

**HOSPITAL NAME**

Timbers VS

**REFERRING VET**

Dr. White

**INVOICE**

35815

**DATE**

2/11/26

**PRESENTING CLINICAL SIGNS**

- Clinical Exam Findings: \*Heart murmur-grade 4-5/6
- ABNORMAL Labwork Values: None
- HR/RR/BP: 120/pant
- Is there a Heart Murmur? If so, please grade: 1-5/6
- Current Medications: Gab 200-300mg BID

**ULTRASONOGRAPHIC EXAMINATION OF THE HEART**

CANINE CARDIAC PARAMETERS	MR VMAX (m/s)	TR VMAX (m/s)	LA/AO (M-Mode)	LA/AO (Heart Base; Swe)	FS (%)	EF (%)	EPSS (cm)
NORMAL PARAMETER	4.5-5.5	<2.7	1.3	Up to 1.6	28-40	40-100	<0.6
PATIENT	NM	--	1.89	1.68	54.39	--	--
CANINE CARDIAC PARAMETERS	HR (BPM)	AV VMAX (m/s)	PV MAX (m/s)	BODY WEIGHT (kg)	LAD LA MAX 4 Chamber	LVIDd Avg; 2D and m-mode short axis (cm)	LVIDs Avg; 2D and m-mode short axis (cm)
NORMAL PARAMETER	50-100	0.7-1.7	0.7-1.6				
PATIENT	--	1.9	0.82	19.1	5.56	4.67	2.13

**Cardiac Presentation**

The mitral valve leaflets are moderately thickened with moderate mitral regurgitation posteriorly directed. There is moderate prolapse of the mitral valve leaflets. The left atrial size is significantly increased. Left ventricular internal dimensions during diastole are increased and systolic function is preserved in the face of mitral regurgitation. There is normal right atrial size with mild tricuspid regurgitation. There is no prolapse of the tricuspid valve leaflets and no evidence of pulmonary hypertension based upon tricuspid regurgitant velocities. The right ventricle subjectively appears normal in structure and function. The aortic and pulmonic valves have normal morphology and the corresponding outflow velocities are within normal limits. There is no evidence of pulmonic or aortic insufficiency. The aorta appears normal. The pulmonary artery and associated branches appear normal. There is no evidence of pleural effusion, pericardial effusion, or intracardiac masses.

**ULTRASONOGRAPHIC FINDINGS**



**PATIENT**

- Degenerative valve disease, ACVIM stage B-2
- Significant left atrial enlargement

Shelby Wofford

**SPECIES**

Canine

**BREED**

Australian Shepherd X

**SEX**

Spayed Female

**AGE**

12 Years

**WEIGHT**

42 Pounds

**INTERPRETED BY**

Sara Brethel, DVM,  
DACVIM (Cardiology)

**IMAGING PERFORMED BY**

Sara Hansen

**HOSPITAL NAME**

Timbers VS

**REFERRING VET**

Dr. White

**INVOICE**

35815

**DATE**

2/11/26

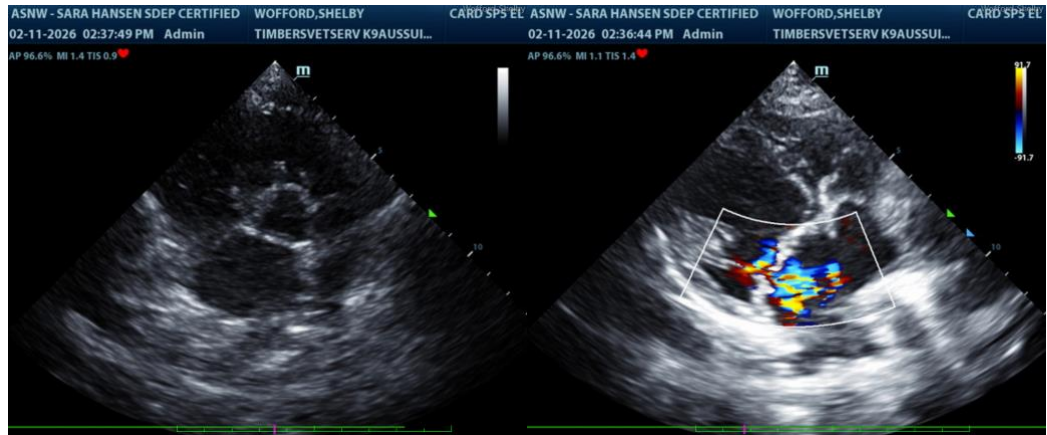
**INTERPRETATION OF THE FINDINGS & FURTHER RECOMMENDATIONS**

The patient has degenerative valve disease ACVIM stage B2 and pimobendan therapy at 0.27-0.32mg/kg PO q12 is recommended. This will be a lifelong therapy. A recheck echocardiogram is recommended in 4-6 months to monitor the condition since starting pimobendan. A sooner recheck is recommended if the patient develops cardiovascular clinical signs or the heart murmur is worsening in intensity. The client should start monitoring respiratory rate and effort at home if not already doing so. The resting respiratory rate should be < 35-40 breathes/minute when the patient is resting or sleeping. If the breathing rates are increasing, then chest radiographs are recommended.

Recommend obtaining a blood pressure on the patient to ensure it is <160mmHg. If the blood pressure is elevated recommend following ACVIM guidelines for systemic hypertension and treating if indicated.

The patient is at an increased risk for elective anesthetic procedures. If anesthesia is needed, ideally the patient would be on pimobendan for at least 1-3 weeks prior to these elective procedures.

Judicious perioperative fluids are recommended due to the increased left atrial size. Medications like dexmedetomidine and other alpha 2 agonists are best avoided. Ketamine is also best avoided. If needed, anticholinergics can be used in the face of a clinically significant bradyarrhythmia (i.e., bradycardia with concurrent hypotension). If the patient is on an ACEi, recommend not giving this therapy the day of anesthesia.



**The information and recommendations provided are based on the images presented by the referring veterinarian/sonographer. No evaluation can be communicated regarding pathology that was not visible in the image/video clips provided.**

Thank you for this referral. If the clinical or image interpretation does not parallel your findings or if I can be of any further assistance please contact me.



**PATIENT**

Sara Brethel DVM, DACVIM (Cardiology)

Shelby Wofford

[info@SonoPath.com](mailto:info@SonoPath.com)

**SPECIES**

Canine

**BREED**

Australian Shepherd X

**SEX**

Spayed Female

**AGE**

12 Years

**WEIGHT**

42 Pounds

**INTERPRETED BY**

Sara Brethel, DVM,  
DACVIM (Cardiology)

**IMAGING  
PERFORMED BY**

Sara Hansen

**HOSPITAL NAME**

Timbers VS

**REFERRING VET**

Dr. White

**INVOICE**

35815

**DATE**

2/11/26