

PATIENT

Louie Gardenier

SPECIES

Feline

BREED

DSH

SEX

Neutered Male

AGE

14 Years 11 Months

WEIGHT

9 pounds

INTERPRETED BY

Sara Brethel, DVM,
 DACVIM (Cardiology)

IMAGING PERFORMED BY

Kerri Becker

HOSPITAL NAME

Bergen County VC

REFERRING VET

Dr. Shiffman

INVOICE

13711

DATE

02/11/26

PRESENTING CLINICAL SIGNS

- New HM, BNP-792, pre dental eval. all other labs WNL

ULTRASONOGRAPHIC EXAMINATION OF THE HEART

FELINE CARDIAC PARAMETERS	BODY WEIGHT (kg)	HR (BPM)	IVSd (cm)	LVIDd (cm)	LVWd (cm)	FS (%)	EF (%)
NORMAL PARAMETER	-----	150-240	0.3-0.6	1.0-2.1	0.25-0.6	35-67	80-100
PATIENT	4.09	209	0.42	1.25	0.65	NM	NM
FELINE CARDIAC PARAMETERS	LA/AO (M-mode)	LA/AO HEART BASE (Sisson)	LAD LA MAX 4 Chamber		LVOT VEL. (m/s)	RVOT VEL. (m/s)	IVRT (m/)
NORMAL PARAMETER	<1.5	1.6	0.7-1.7		<1.6	<1.3	40-60
PATIENT	1.14	1.42	NM		NM	~1.0	NM
Adapted from June Boon, Veterinary Echocardiography, 1998 Sisson D et al. JVIM 1991; 5: 232, Jacobs et al. Am J Vet Res 1985; 46:1705							

Cardiac Presentation

The left atrium is within normal limits. The mitral valve leaflets are normal and there is trivial to mild mitral regurgitation. There is no evidence of systolic anterior motion of the mitral valve and no evidence of a left ventricular outflow tract obstruction. There is concentric hypertrophy of the left ventricle.

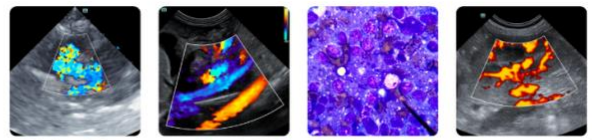
The right atrium is normal. The tricuspid valve is normal without evidence of tricuspid regurgitation. The right ventricle appears to have preserved systolic function subjectively. The aortic and pulmonic valves are normal without evidence of insufficiency. Aortic and pulmonic outflow velocities are within normal limits. The aorta and PA are normal along with the associated PA branches. There is no evidence of pleural effusion, pericardial effusion, or intracardiac masses.

ULTRASONOGRAPHIC FINDINGS

- Left ventricular concentric hypertrophy.
- Mild mitral regurgitation.

INTERPRETATION OF THE FINDINGS & FURTHER RECOMMENDATIONS

The patient has evidence of left ventricular concentric hypertrophy and is classified as a stage B1 due to the normal left atrial size. If not already performed, it is recommended to ensure that patients blood pressure is normal and the patient is euthyroid. If the patient is euthyroid and normotensive, then the patient has underlying hypertrophic cardiomyopathy. No cardiac medications are indicated at this time as the patient is at a low risk for complications associated with this condition. Since this can be a



PATIENT

Louie Gardenier

SPECIES

Feline

BREED

DSH

SEX

Neutered Male

AGE

14 Years 11 Months

WEIGHT

9 pounds

INTERPRETED BY

Sara Brethel, DVM,
DACVIM (Cardiology)

IMAGING PERFORMED BY

Kerri Becker

HOSPITAL NAME

Bergen County VC

REFERRING VET

Dr. Shiffman

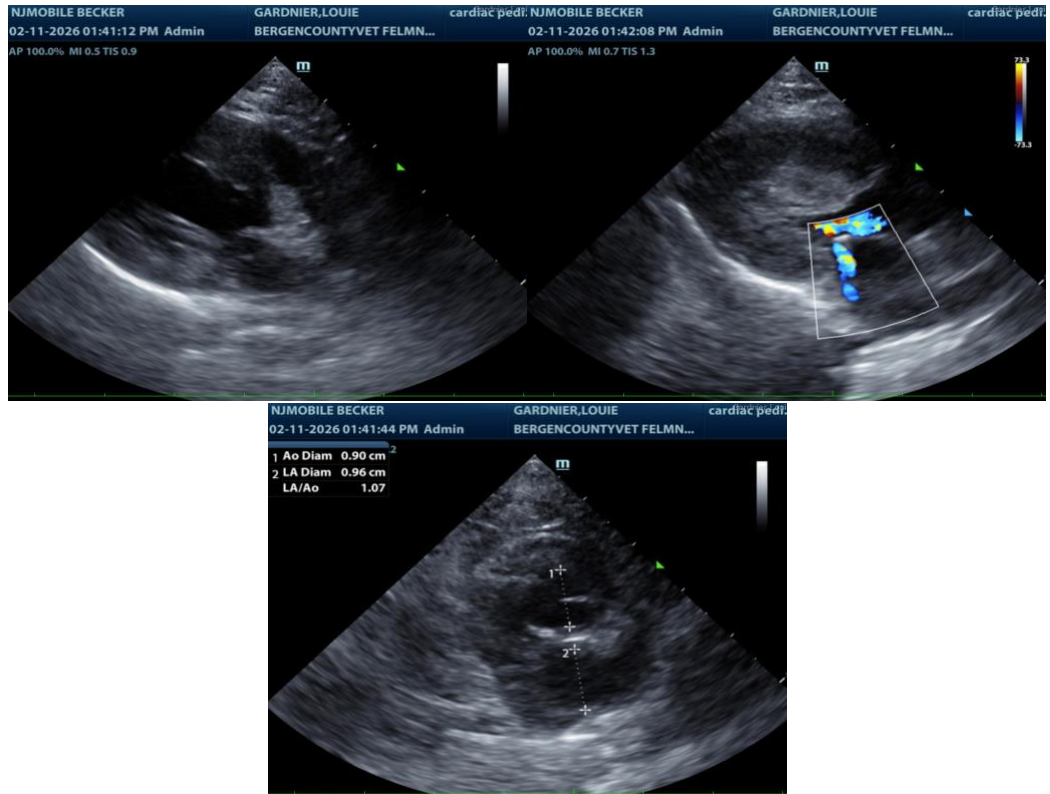
INVOICE

13711

DATE

02/11/26

progressive condition, serial monitoring is recommended. It's recommended to recheck an echocardiogram in 6 months, sooner if the patient develops cardiovascular clinical signs. Standard perioperative fluid rates should be well-tolerated. Medications like dexmedetomidine and other alpha 2 agonists are best avoided. Ketamine is also best avoided. Anticholinergics can be used in the case of a clinically significant bradyarrhythmia (i.e., bradycardia with concurrent hypotension). If the patient is on an ACEi, recommend not giving this therapy the day of anesthesia.



The information and recommendations provided are based on the images presented by the referring veterinarian/sonographer. No evaluation can be communicated regarding pathology that was not visible in the image/video clips provided.

Thank you for this referral. If the clinical or image interpretation does not parallel your findings or if I can be of any further assistance, please contact me.

Sara Brethel, DVM, DACVIM (Cardiology)

info@SonoPath.com