



PATIENT

Henry Pontius

SPECIES

Canine

BREED

Cavapoo

SEX

Neutered Male

AGE

3 Years 10 Months

WEIGHT

11.3 Pounds

INTERPRETED BY

Sara Brethel, DVM,
DACVIM (Cardiology)

IMAGING PERFORMED BY

Dr. Kristen Carpenter

HOSPITAL NAME

Pennridge AH

REFERRING VET

Dr. Kristen Carpenter

INVOICE

35814

DATE

2/11/26

PRESENTING CLINICAL SIGNS

History:

- Patient was not sedated
- Previous history of pancreatitis and patient has frequent exams.
- Sudden new Grade III L systolic heart murmur ausculted at last exam and owner noted that patient has been intermittently coughing. Lungs clear and eupnic on exam.

Diagnostics:

- Bloodwork 2/6/26: NSF except proBNP 1,097 (0-900)
- Thoracic Rads: Cardiac silhouette WNL. VHS - 9.9 VLAS - 1.53 Pulm vasculature normal. No pulm edema or pleural effusion. No obvious collapsing trachea.
- Blood Pressure: 160 mm HG systolic

ULTRASONOGRAPHIC EXAMINATION OF THE HEART

CANINE CARDIAC PARAMETERS	MR VMAX (m/s)	TR VMAX (m/s)	LA/AO (M-Mode)	LA/AO (Heart Base; Swe)	FS (%)	EF (%)	EPSS (cm)
NORMAL PARAMETER	4.5-5.5	<2.7	1.3	Up to 1.6	28-40	40-100	<0.6
PATIENT	4.84	~2.0	1.51	1.21	33.62	--	0.16
CANINE CARDIAC PARAMETERS	HR (BPM)	AV VMAX (m/s)	PV MAX (m/s)	BODY WEIGHT (kg)	LAD LA MAX 4 Chamber	LVIDd Avg; 2D and m-mode short axis (cm)	LVIDs Avg; 2D and m-mode short axis (cm)
NORMAL PARAMETER	50-100	0.7-1.7	0.7-1.6				
PATIENT	NM	1.76	1.11	5.13	2.0	2.26	1.5

Chest Radiographic Interpretation

The cardiac silhouette is within normal limits. The pulmonary vasculature is normal. The pulmonary parenchyma appears unremarkable. There is no evidence of cardiogenic pulmonary edema. A reason for the patient's coughing is not identified based upon the thoracic imaging provided.



PATIENT

Henry Pontius

SPECIES

Canine

BREED

Cavapoo

SEX

Neutered Male

AGE

3 Years 10 Months

WEIGHT

11.3 Pounds

INTERPRETED BY

Sara Brethel, DVM,
DACVIM (Cardiology)

IMAGING PERFORMED BY

Dr. Kristen Carpenter

HOSPITAL NAME

Pennridge AH

REFERRING VET

Dr. Kristen Carpenter

INVOICE

35814

DATE

2/11/26

Cardiac Presentation

The mitral valve leaflets are mildly thickened with mild mitral regurgitation posteriorly directed. There is no prolapse of the mitral valve leaflet. The left atrial size is normal. Left ventricular internal dimensions during diastole are within normal limits and systolic function is preserved in the face of mitral regurgitation. There is normal right atrial size with mild tricuspid regurgitation. There is no prolapse of the tricuspid valve leaflets and no evidence of pulmonary hypertension based upon tricuspid regurgitant velocities. The right ventricle subjectively appears normal in structure and function. The aortic and pulmonic valves have normal morphology and the corresponding outflow velocities are within normal limits. There is no evidence of pulmonic or aortic insufficiency. The aorta appears normal. The pulmonary artery and associated branches appear normal. There is no evidence of pleural effusion, pericardial effusion, or intracardiac masses.

ULTRASONOGRAPHIC FINDINGS

- Degenerative valve disease, ACVIM stage B-1

INTERPRETATION OF THE FINDINGS & FURTHER RECOMMENDATIONS

The patient has degenerative valve disease ACVIM stage B1 and no cardiac medications are indicated at this time. Since this can be a progressive condition, serial monitoring is recommended. A recheck echocardiogram is recommended in 10-12 months. A sooner recheck is recommended if the patient develops cardiovascular clinical signs or the heart murmur is worsening in intensity. Elective anesthetic procedures should be well tolerated.

Recommend obtaining a blood pressure on the patient to ensure it is <160mmHg. If the blood pressure is elevated recommend following ACVIM guidelines for systemic hypertension and treating if indicated. The reported blood pressure is at the upper limits of normal and recommend monitoring this every 3-4 months.

Standard perioperative fluid rates should be well-tolerated. Medications like dexmedetomidine and other alpha 2 agonists are best avoided. Ketamine is also best avoided. Anticholinergics can be used in the case of a clinically significant bradyarrhythmia (i.e., bradycardia with concurrent hypotension). If the patient is on an ACEi, recommend not giving this therapy the day of anesthesia.



PATIENT

Henry Pontius

SPECIES

Canine

BREED

Cavapoo

SEX

Neutered Male

AGE

3 Years 10 Months

WEIGHT

11.3 Pounds

INTERPRETED BY

Sara Brethel, DVM,
DACVIM (Cardiology)

IMAGING PERFORMED BY

Dr. Kristen Carpenter

HOSPITAL NAME

Pennridge AH

REFERRING VET

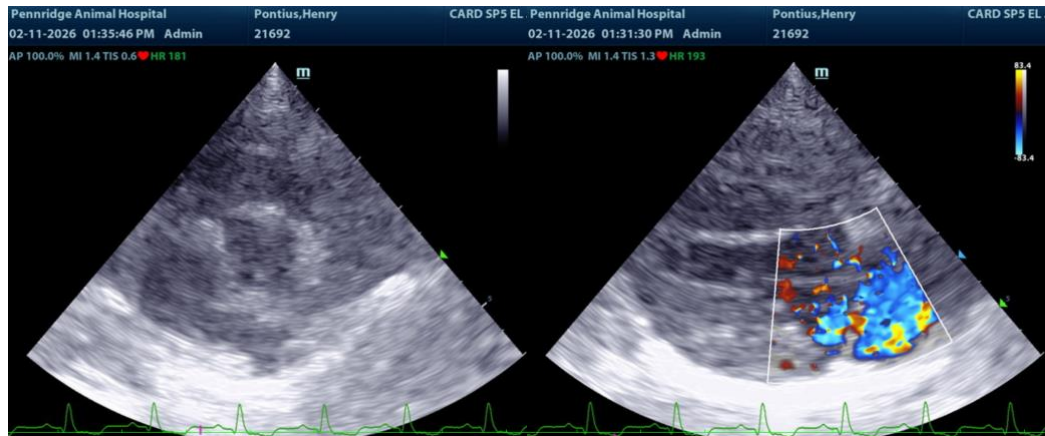
Dr. Kristen Carpenter

INVOICE

35814

DATE

2/11/26



The information and recommendations provided are based on the images presented by the referring veterinarian/sonographer. No evaluation can be communicated regarding pathology that was not visible in the image/video clips provided.

Thank you for this referral. If the clinical or image interpretation does not parallel your findings or if I can be of any further assistance please contact me.

Sara Brethel DVM, DACVIM (Cardiology)

info@SonoPath.com