

PATIENT

Jade Linville

SPECIES

Canine

BREED

Doberman Pinscher

SEX

Spayed Female

AGE

5 Years

WEIGHT

60 pounds

INTERPRETED BY

Sara Brethel DVM,
 DACVIM (Cardiology)

IMAGING PERFORMED BY

Kathleen Byrnes

HOSPITAL NAME

Animal Clinic Madison
 Mayodan

REFERRING VET

Dr. Flanagan

INVOICE

13678

DATE

02/10/26

PRESENTING CLINICAL SIGNS

- P presented for echo with brother Amos. Owner doing screening due to breed and genetic testing concerning for DCM

ULTRASONOGRAPHIC EXAMINATION OF THE HEART

CANINE CARDIAC PARAMETERS	MR VMAX (m/s)	TR VMAX (m/s)	LA/AO (M-Mode)	LA/AO (Heart Base; Swe)	FS (%)	EF (%)	EPSS (cm)
NORMAL PARAMETER	4.5-5.5	<2.7	1.3	Up to 1.6	28-40	40-100	<0.6
PATIENT	--	1.73	1.14	1.4	33.09	62.19	NM
CANINE CARDIAC PARAMETERS	HR (BPM)	AV VMAX (m/s)	PV MAX (m/s)	BODY WEIGHT (kg)	LAD LA MAX 4 Chamber	LVIDd Avg; 2D and m-mode short axis (cm)	LVIDs Avg; 2D and m-mode short axis (cm)
NORMAL PARAMETER	50-100	0.7-1.7	0.7-1.6				
PATIENT	89	2.04	1.51	27.27	4.6	4.05	2.71

Cardiac Presentation

The mitral valve leaflets are normal and there is no mitral regurgitation. There is no prolapse of the mitral valve leaflets. The left atrial size is normal. Left ventricular systolic and diastolic function is within normal limits. There is normal right atrial size with evidence of tricuspid regurgitation. There is no prolapse of the tricuspid valve leaflets and no evidence of pulmonary hypertension on today's evaluation. The right ventricle subjectively appears normal in structure and function. The aortic and pulmonic valves have normal morphology and the corresponding outflow velocities are within normal limits. There is no evidence of pulmonic or aortic insufficiency. The aorta appears normal. The pulmonary artery and associated branches appear normal. There is no evidence of pleural effusion, pericardial effusion, or intracardiac masses.

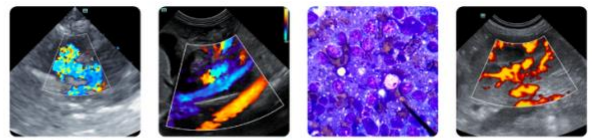
ECG

Sinus rhythm.

ULTRASONOGRAPHIC FINDINGS

- Trivial tricuspid regurgitation.
- Normal sinus rhythm.

INTERPRETATION OF THE FINDINGS & FURTHER RECOMMENDATIONS



PATIENT

Jade Linville

SPECIES

Canine

BREED

Doberman Pinscher

SEX

Spayed Female

AGE

5 Years

WEIGHT

60 pounds

INTERPRETED BY

Sara Brethel DVM,
 DACVIM (Cardiology)

IMAGING PERFORMED BY

Kathleen Byrnes

HOSPITAL NAME

Animal Clinic Madison
 Mayodan

REFERRING VET

Dr. Flanagan

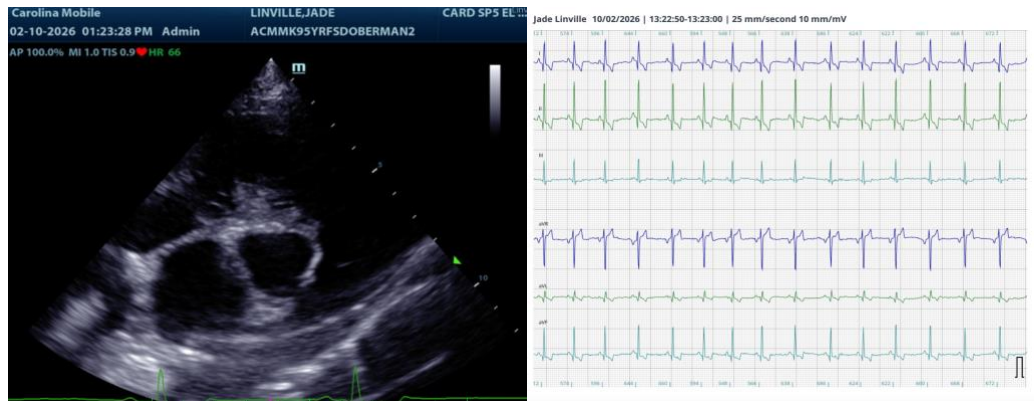
INVOICE

13678

DATE

02/10/26

The patient's heart is largely normal. There is trivial tricuspid regurgitation. This is likely innocent versus physiologic. There is no evidence of dilated cardiomyopathy. Despite the normal ECG provided, a Holter monitor is still recommended for the patient due to the breed. Additionally, a recheck echo and Holter is recommended in 10 to 12 months.



The information and recommendations provided are based on the images presented by the referring veterinarian/sonographer. No evaluation can be communicated regarding pathology that was not visible in the image/video clips provided.

Thank you for this referral. If the clinical or image interpretation does not parallel your findings or if I can be of any further assistance please contact me.

Sara Brethel DVM, DACVIM (Cardiology)

info@SonoPath.com