

PATIENT

Cy Bachtel

SPECIES

Canine

BREED

Labrador X

SEX

Neutered Male

AGE

12 Years

WEIGHT

82.4 Pounds

INTERPRETED BY

Sara Brethel DVM,
 DACVIM (Cardiology)

IMAGING PERFORMED BY

Sara Hansen

HOSPITAL NAME

West Hills AH

REFERRING VET

Dr. Pospichal

INVOICE

36806

DATE

12/8/25

PRESENTING CLINICAL SIGNS

History: Clinical Exam Findings: Grade 3 left basilar systolic murmur - historic. Previously documented arrhythmia. Otherwise, asymptomatic ABNORMAL Labwork Values Elevated ProBNP For ECHO Only: Blood Pressure pending HR/RR/BP: 90/30/pending Is there a Heart Murmur? If so, please grade. grade 3 Current Medications none, Radiographic Findings n/a, Notes to Specialist (if any) Primary question to be answered: Source of murmur/elevated ProBNP. Severity.

ULTRASONOGRAPHIC EXAMINATION OF THE HEART

CANINE CARDIAC PARAMETERS	MR VMAX (m/s)	TR VMAX (m/s)	LA/AO (M-Mode)	LA/AO (Heart Base; Swe)	FS (%)	EF (%)	EPSS (cm)
NORMAL PARAMETER	4.5-5.5	<2.7	1.3	Up to 1.6	28-40	40-100	<0.6
PATIENT	6.9	2.59	NM	1.21	33.33	--	NM
CANINE CARDIAC PARAMETERS	HR (BPM)	AV VMAX (m/s)	PV MAX (m/s)	BODY WEIGHT (kg)	LAD LA MAX 4 Chamber	LVIDd Avg; 2D and m-mode short axis (cm)	LVIDs Avg; 2D and m-mode short axis (cm)
NORMAL PARAMETER	50-100	0.7-1.7	0.7-1.6				
PATIENT	--	1.93	1.03	37.45	5.2	3.6	2.4

ECG Interpretation

There is significant baseline artifact in the middle of the ECG. There appears to be a premature beat. Zooming in, there does appear to be a p wave present, however, an atrial premature complex cannot be ruled out. Can consider obtaining a longer ECG and troubleshooting to reduce the artifact that is present.

Cardiac Presentation

The mitral valve leaflets are mildly thickened with mild mitral regurgitation posteriorly directed. There is no prolapse of the mitral valve leaflet. The left atrial size is normal. Left ventricular internal dimensions during diastole are within normal limits and systolic function is preserved in the face of mitral regurgitation. There is normal right atrial size with mild tricuspid regurgitation. There is no prolapse of the tricuspid valve leaflets and mild pulmonary hypertension based upon tricuspid regurgitant velocities. The right ventricle subjectively appears normal in structure and function. The aortic and pulmonic valves have normal morphology and the corresponding outflow velocities are within normal limits. There is no evidence of pulmonic or aortic insufficiency. The aorta appears



PATIENT

Cy Bachtel

SPECIES

Canine

BREED

Labrador X

SEX

Neutered Male

AGE

12 Years

WEIGHT

82.4 Pounds

INTERPRETED BY

Sara Brethel DVM,
DACVIM (Cardiology)

IMAGING PERFORMED BY

Sara Hansen

HOSPITAL NAME

West Hills AH

REFERRING VET

Dr. Pospichal

INVOICE

36806

DATE

12/8/25

normal. The pulmonary artery and associated branches appear normal. There is no evidence of pleural effusion, pericardial effusion, or intracardiac masses.

ULTRASONOGRAPHIC FINDINGS

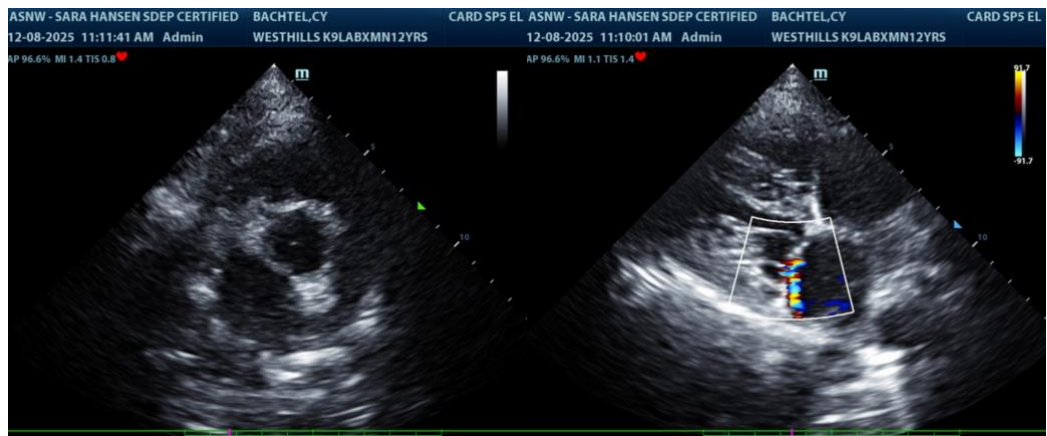
- Degenerative valve disease, ACVIM stage B-1
- Mild tricuspid regurgitation
- Mild pulmonary hypertension
- Possible atrial premature complex

INTERPRETATION OF THE FINDINGS & FURTHER RECOMMENDATIONS

The patient has degenerative valve disease ACVIM stage B1 and no cardiac medications are indicated at this time. Since this can be a progressive condition, serial monitoring is recommended. A recheck echocardiogram is recommended in 6 months. A sooner recheck is recommended if the patient develops cardiovascular clinical signs or the heart murmur is worsening in intensity. Elective anesthetic procedures should be well tolerated.

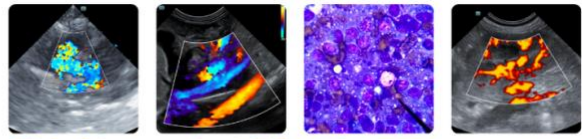
Recommend obtaining a blood pressure on the patient to ensure it is <160mmHg. If the blood pressure is elevated recommend following ACVIM guidelines for systemic hypertension and treating if indicated.

Standard perioperative fluid rates should be well-tolerated. Medications like dexmedetomidine and other alpha 2 agonists are best avoided. Ketamine is also best avoided. Anticholinergics can be used in the case of a clinically significant bradyarrhythmia (i.e., bradycardia with concurrent hypotension). If the patient is on an ACEi, recommend not giving this therapy the day of anesthesia.



The information and recommendations provided are based on the images presented by the referring veterinarian/sonographer. No evaluation can be communicated regarding pathology that was not visible in the image/video clips provided.

Thank you for this referral. If the clinical or image interpretation does not parallel your findings or if I can be of any further assistance please contact me.



PATIENT

Sara Brethel DVM, DACVIM (Cardiology)

Cy Bachtel

info@SonoPath.com

SPECIES

Canine

BREED

Labrador X

SEX

Neutered Male

AGE

12 Years

WEIGHT

82.4 Pounds

INTERPRETED BY

Sara Brethel DVM,
DACVIM (Cardiology)

**IMAGING
PERFORMED BY**

Sara Hansen

HOSPITAL NAME

West Hills AH

REFERRING VET

Dr. Pospichal

INVOICE

36806

DATE

12/8/25