



PATIENT

Rosa Jasper

SPECIES

Canine

BREED

Terrier X

SEX

Spayed Female

AGE

10 Years

WEIGHT

5 kg

INTERPRETED BY

Sara Brethel, DVM,
DACVIM (Cardiology)

IMAGING PERFORMED BY

Dr. Iacovides

HOSPITAL NAME

Tuxedo AH

REFERRING VET

Dr. Buchanan

INVOICE

35131

DATE

12/29/25

PRESENTING CLINICAL SIGNS

History: Noticed 3-4 weeks ago with heavy panting and anxious behavior - on Saturday (48 hours ago) was heavy panting with abdominal breathing - went to emerg 48 hours ago - x-rays done, heart enlarged - sent home with diuretic and pimobendan b/c of possibility for CHF based on rads. However, this am, owner noticed shaking a lot in clinic with increased breathing. Appetite ok. Activity level normal. No cough at any point in the history SRR at home is 25/m as highest number Meds: Vetmedin 1.25 MG (per CAP): Give 1 tablet q12 hours for 7 days furosemide 10mg/ml: 0.5ml BID for 7 days (1mg/kg BID).

Abnormal PE/Chem/CBC/UA Results: Pulse is 120 grade 2/6 murmur Resp normal with a bit increased sounds bilaterally BCS 5/9 Rads: Cardiomegaly.

ULTRASONOGRAPHIC EXAMINATION OF THE HEART

CANINE CARDIAC PARAMETERS	MR VMAX (m/s)	TR VMAX (m/s)	LA/AO (M-Mode)	LA/AO (Heart Base; Swe)	FS (%)	EF (%)	EPSS (cm)
NORMAL PARAMETER	4.5-5.5	<2.7	1.3	Up to 1.6	28-40	40-100	<0.6
PATIENT	4.98	3.14	NM	1.48	35.51	--	NM
CANINE CARDIAC PARAMETERS	HR (BPM)	AV VMAX (m/s)	PV MAX (m/s)	BODY WEIGHT (kg)	LAD LA MAX 4 Chamber	LVIDd Avg; 2D and m-mode short axis (cm)	LVIDs Avg; 2D and m-mode short axis (cm)
NORMAL PARAMETER	50-100	0.7-1.7	0.7-1.6				
PATIENT	--	1.2	0.88	5	2.5	2.45	1.58

Chest Radiographic Interpretation

Based upon the images provided, there does not appear to be evidence of cardiogenic pulmonary edema.

Cardiac Presentation

The mitral valve leaflets are mildly thickened with mild mitral regurgitation posteriorly directed. There is no prolapse of the mitral valve leaflet. The left atrial size is normal. Left ventricular internal dimensions during diastole are within normal limits and systolic function is preserved in the face of mitral regurgitation. There is normal right atrial size with mild tricuspid regurgitation. There is no prolapse of the tricuspid valve leaflets and no evidence of pulmonary hypertension based upon tricuspid regurgitant velocities. The right ventricle subjectively appears normal in structure and



PATIENT

Rosa Jasper

SPECIES

Canine

BREED

Terrier X

SEX

Spayed Female

AGE

10 Years

WEIGHT

5 kg

INTERPRETED BY

Sara Brethel, DVM,
DACVIM (Cardiology)

IMAGING PERFORMED BY

Dr. Iacovides

HOSPITAL NAME

Tuxedo AH

REFERRING VET

Dr. Buchanan

INVOICE

35131

DATE

12/29/25

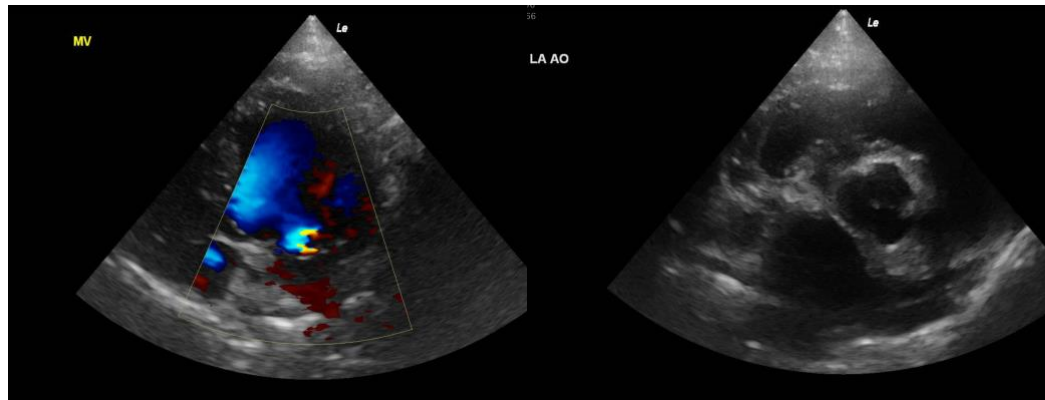
function. The aortic and pulmonic valves have normal morphology and the corresponding outflow velocities are within normal limits. There is no evidence of pulmonic or aortic insufficiency. The aorta appears normal. The pulmonary artery and associated branches appear normal. There is no evidence of pleural effusion, pericardial effusion, or intracardiac masses.

ULTRASONOGRAPHIC FINDINGS

- Degenerative valve disease, ACVIM stage B-1
- Normal left atrial size
- No evidence of significant pulmonary hypertension

INTERPRETATION OF THE FINDINGS & FURTHER RECOMMENDATIONS

The patient does have degenerative valve disease, however, there is no evidence of significant left atrial enlargement. A cause for the heavy panting and anxious behavior is not identified from a cardiac perspective. I would recommend discontinuation of the furosemide therapy. The left atrium is normal, and technically, Vetmedin is not indicated at this time. To be cautious, can stop furosemide, wait 2-3 days, as long as the patient's clinical signs are not worsening and the respiratory rate remains normal, then stop Vetmedin. I do recommend a sooner recheck just to monitor for any progression of the cardiac disease, while off of therapy, with a recheck echo in 3-4 months. The cause of the patient's behavior is unknown. Recommend further investigation. Also recommend ensuring the patient's blood pressure is normal. Can consider abdominal imaging with radiographs +/- an abdominal ultrasound.



The information and recommendations provided are based on the images presented by the referring veterinarian/sonographer. No evaluation can be communicated regarding pathology that was not visible in the image/video clips provided.

Thank you for this referral. If the clinical or image interpretation does not parallel your findings or if I can be of any further assistance please contact me.

Sara Brethel DVM, DACVIM (Cardiology)



PATIENT

info@SonoPath.com

Rosa Jasper

SPECIES

Canine

BREED

Terrier X

SEX

Spayed Female

AGE

10 Years

WEIGHT

5 kg

INTERPRETED BY

Sara Brethel, DVM,
DACVIM (Cardiology)

**IMAGING
PERFORMED BY**

Dr. Iacovides

HOSPITAL NAME

Tuxedo AH

REFERRING VET

Dr. Buchanan

INVOICE

35131

DATE

12/29/25