



PATIENT

Eva Cornes

SPECIES

Boston Terrier

BREED

Boston Terrier

SEX

Spayed Female

AGE

10 Years 9 Months

WEIGHT

12.2 kg

INTERPRETED BY

Sara Brethel DVM,
DACVIM (Cardiology)

IMAGING PERFORMED BY

Dr. Sammi Fuller

HOSPITAL NAME

Hart Family VC

REFERRING VET

Dr. Sammi Fuller

INVOICE

35413

DATE

11/6/25

PRESENTING CLINICAL SIGNS

History: Grade 3/6 murmur asymptomatic at this time suspect early MVI no indication for LA enlargement average of 5 BP readings: 146/73 (97) Baseline echo and cardiac workup done today. Abnormal PE/Chem/CBC/UA Results: Chest Xrays: no cardiomegaly no pulm edema Previous BW done- mildly elevated ALP and ALT otherwise unremarkable.

ULTRASONOGRAPHIC EXAMINATION OF THE HEART

CANINE CARDIAC PARAMETERS	MR VMAX (m/s)	TR VMAX (m/s)	LA/AO (M-Mode)	LA/AO (Heart Base; Swe)	FS (%)	EF (%)	EPSS (cm)
NORMAL PARAMETER	4.5-5.5	<2.7	1.3	Up to 1.6	28-40	40-100	<0.6
PATIENT	NM	--	NM	1.86	40	--	NM
CANINE CARDIAC PARAMETERS	HR (BPM)	AV VMAX (m/s)	PV MAX (m/s)	BODY WEIGHT (kg)	LAD LA MAX 4 Chamber	LVIDd Avg; 2D and m-mode short axis (cm)	LVIDs Avg; 2D and m-mode short axis (cm)
NORMAL PARAMETER	50-100	0.7-1.7	0.7-1.6				
PATIENT	--	Underest	~1.0	12.2	--	3.5	2.1

ECG Interpretation

Normal sinus rhythm

Cardiac Presentation

The mitral valve leaflets are mildly thickened with mild mitral regurgitation posteriorly directed. There is no prolapse of the mitral valve leaflets. The left atrial size is moderately increased. Left ventricular internal dimensions during diastole are within normal limits and systolic function is preserved in the face of mitral regurgitation. There is normal right atrial size without tricuspid regurgitation. There is no prolapse of the tricuspid valve leaflets and no evidence of pulmonary hypertension based upon tricuspid regurgitant velocities. The right ventricle subjectively appears normal in structure and function. The aortic and pulmonic valves have normal morphology and the corresponding outflow velocities are within normal limits. There is no evidence of pulmonic or aortic insufficiency. The aorta appears normal. The pulmonary artery and associated branches appear normal. There is no evidence of pleural effusion, pericardial effusion, or intracardiac masses.

ULTRASONOGRAPHIC FINDINGS

- Degenerative valve disease, ACVIM stage B-2



PATIENT

- Normal sinus rhythm

Eva Cornes

SPECIES

Boston Terrier

BREED

Boston Terrier

SEX

Spayed Female

AGE

10 Years 9 Months

WEIGHT

12.2 kg

INTERPRETED BY

Sara Brethel DVM,
DACVIM (Cardiology)

IMAGING PERFORMED BY

Dr. Sammi Fuller

HOSPITAL NAME

Hart Family VC

REFERRING VET

Dr. Sammi Fuller

INVOICE

35413

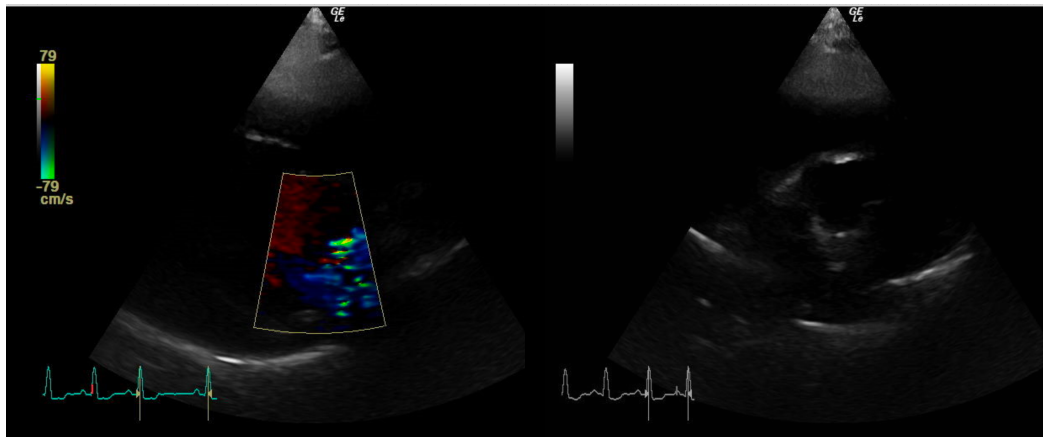
DATE

11/6/25

INTERPRETATION OF THE FINDINGS & FURTHER RECOMMENDATIONS

The patient has degenerative valve disease ACVIM stage B2 and pimobendan therapy at 0.27-0.32mg/kg PO q12 is recommended. This will be a lifelong therapy. A recheck echocardiogram is recommended in 4-6 months to monitor the condition since starting pimobendan. A sooner recheck is recommended if the patient develops cardiovascular clinical signs or the heart murmur is worsening in intensity. The client should start monitoring respiratory rate and effort at home if not already doing so. The resting respiratory rate should be < 35-40 breathes/minute when the patient is resting or sleeping. If the breathing rates are increasing, then chest radiographs are recommended.

The reported blood pressure readings are within normal limits. Note, it is recommended to increase the gray scale for future examinations. The images provided are very dark.



The information and recommendations provided are based on the images presented by the referring veterinarian/sonographer. No evaluation can be communicated regarding pathology that was not visible in the image/video clips provided.

Thank you for this referral. If the clinical or image interpretation does not parallel your findings or if I can be of any further assistance please contact me.

Sara Brethel DVM, DACVIM (Cardiology)

info@SonoPath.com