



PATIENT PRESENTING CLINICAL SIGNS

Rosie Braun 10-year-old Chihuahua with severe dental disease, finding a Grade II/IV systolic heart murmur with a possible arrhythmia. Owner reports daily coughing at home. Recommend cardiac work-up prior to GA for dental surgery.

SPECIES

Canine Current Medications 25 mg Atopica capsule every 48 hours

BREED

Abnormal PE/Chem/CBC/UA Results: N/A ECG attached

Chi X

ULTRASONOGRAPHIC EXAMINATION OF THE HEART

SEX

Spayed Female

AGE

11 Years

WEIGHT

4.7 kg

INTERPRETED BY

Sara Brethel DVM, DACVIM (Cardiology)

IMAGING PERFORMED BY

Amanda Stewart

HOSPITAL NAME

Woodstock VH

REFERRING VET

Dr. Duschinsky

INVOICE

12112

DATE

11/05/25

CANINE CARDIAC PARAMETERS	MR VMAX (m/s)	TR VMAX (m/s)	LA/AO (M-Mode)	LA/AO (Heart Base; Swe)	FS (%)	EF (%)	EPSS (cm)
NORMAL PARAMETER	4.5-5.5	<2.7	1.3	Up to 1.6	28-40	40-100	<0.6
PATIENT	4.09	--	NM	1.3	47.61	--	0.16
CANINE CARDIAC PARAMETERS	HR (BPM)	AV VMAX (m/s)	PV MAX (m/s)	BODY WEIGHT (kg)	LAD LA MAX 4 Chamber	LVIDd Avg; 2D and m-mode short axis (cm)	LVIDs Avg; 2D and m-mode short axis (cm)
NORMAL PARAMETER	50-100	0.7-1.7	0.7-1.6				
PATIENT	102	1.0	0.79	4.7	2.4	2.1	1.1

ECG

Sinus rhythm with a sinus arrhythmia.

Cardiac Presentation

The mitral valve leaflets are mildly thickened with mild mitral regurgitation posteriorly directed. There is no prolapse of the mitral valve leaflets. The left atrial size is normal. Left ventricular internal dimensions during diastole are within normal limits and systolic function is preserved in the face of mitral regurgitation. There is normal right atrial size without tricuspid regurgitation. There is no prolapse of the tricuspid valve leaflets and no evidence of pulmonary hypertension based upon tricuspid regurgitant velocities. The right ventricle subjectively appears normal in structure and function. The aortic and pulmonic valves have normal morphology and the corresponding outflow velocities are within normal limits. There is no evidence of pulmonic or aortic insufficiency. The aorta appears normal. The pulmonary artery and associated branches appear normal. There is no evidence of pleural effusion, pericardial effusion, or intracardiac masses.

ULTRASONOGRAPHIC FINDINGS



PATIENT

Rosie Braun

- Degenerative valve disease, ACVIM stage B1 (mitral).
- Sinus rhythm with sinus arrhythmia.

SPECIES

Canine

BREED

Chi X

SEX

Spayed Female

AGE

11 Years

WEIGHT

4.7 kg

INTERPRETED BY

Sara Brethel DVM,
 DACVIM (Cardiology)

IMAGING PERFORMED BY

Amanda Stewart

HOSPITAL NAME

Woodstock VH

REFERRING VET

Dr. Duschinsky

INVOICE

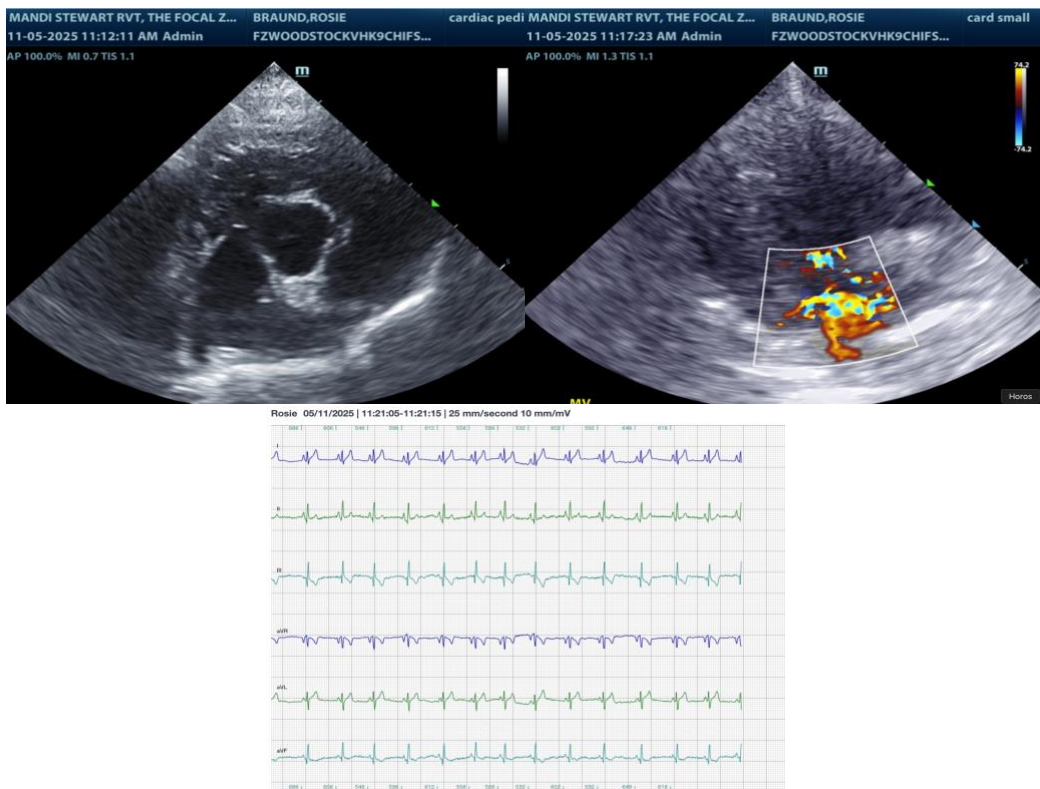
12112

DATE

11/05/25

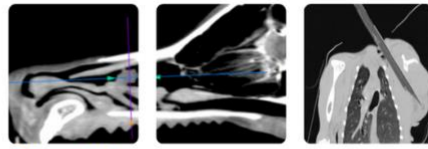
INTERPRETATION OF THE FINDINGS & FURTHER RECOMMENDATIONS

The patient has degenerative valve disease ACVIM stage B1 and no cardiac medications are indicated at this time. Since this can be a progressive condition, serial monitoring is recommended. A recheck echocardiogram is recommended in 10-12 months. A sooner recheck is recommended if the patient develops cardiovascular clinical signs or the heart murmur is worsening in intensity. Elective anesthetic procedures should be well tolerated. Recommend obtaining a blood pressure on the patient to ensure it is <160mmHg. If the blood pressure is elevated recommend following ACVIM guidelines for systemic hypertension and treating if indicated. Standard perioperative fluid rates should be well-tolerated. Medications like dexmedetomidine and other alpha 2 agonists are best avoided. Ketamine is also best avoided. Anticholinergics can be used in the case of a clinically significant bradyarrhythmia (i.e., bradycardia with concurrent hypotension). If the patient is on an ACEi, recommend not giving this therapy the day of anesthesia. With the patient's history of coughing, this is not cardiac in nature and recommend obtaining chest radiographs to ensure another cause is not identified.



The information and recommendations provided are based on the images presented by the referring veterinarian/sonographer. No evaluation can be communicated regarding pathology that was not visible in the image/video clips provided.

Thank you for this referral. If the clinical or image interpretation does not parallel your findings or if I



PATIENT

can be of any further assistance please contact me.

Rosie Braun

Sara Brethel DVM, DACVIM (Cardiology)

SPECIES

info@SonoPath.com

Canine

BREED

Chi X

SEX

Spayed Female

AGE

11 Years

WEIGHT

4.7 kg

INTERPRETED BY

Sara Brethel DVM,
DACVIM (Cardiology)

**IMAGING
PERFORMED BY**

Amanda Stewart

HOSPITAL NAME

Woodstock VH

REFERRING VET

Dr. Duschinsky

INVOICE

12112

DATE

11/05/25