

**PATIENT**

Tank Cornforth

**SPECIES**

Canine

**BREED**

Pitbull

**SEX**

Neutered Male

**AGE**

12 Years

**WEIGHT**

73 Pounds

**INTERPRETED BY**

Sara Brethel DVM,  
DACVIM (Cardiology)

**IMAGING PERFORMED BY**

Yvonna Aranda

**HOSPITAL NAME**

Countryside AC

**REFERRING VET**

Dr. Cox

**INVOICE**

35408

**DATE**

11/4/25

**PRESENTING CLINICAL SIGNS**

History: Clinical Exam Findings: Increased lung sounds, bilateral  
Abnormal PE/Chem/CBC/UA Results: HR/RR/BP: 170 HR Is there a Heart Murmur? If so, please grade.  
4/6 Current Medications Furosemide 20mg- he received 80mg last night.

**ULTRASONOGRAPHIC EXAMINATION OF THE HEART**

CANINE CARDIAC PARAMETERS	MR VMAX (m/s)	TR VMAX (m/s)	LA/AO (M-Mode)	LA/AO (Heart Base; Swe)	FS (%)	EF (%)	EPSS (cm)
<b>NORMAL PARAMETER</b>	4.5-5.5	<2.7	1.3	Up to 1.6	28-40	40-100	<0.6
<b>PATIENT</b>	~5.0	--	1.57	1.56	33.33	--	NM
CANINE CARDIAC PARAMETERS	HR (BPM)	AV VMAX (m/s)	PV MAX (m/s)	BODY WEIGHT (kg)	LAD LA MAX 4 Chamber	LVIDd Avg; 2D and m-mode short axis (cm)	LVIDs Avg; 2D and m-mode short axis (cm)
<b>NORMAL PARAMETER</b>	50-100	0.7-1.7	0.7-1.6				
<b>PATIENT</b>	133	1.87	0.72	33.18	4.8	4.5	3.0

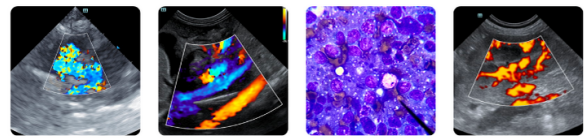
**Cardiac Presentation**

The mitral valve leaflets are mildly thickened with mild mitral regurgitation posteriorly directed. There is no prolapse of the mitral valve leaflet. The left atrial size is mildly increased. Left ventricular internal dimensions during diastole are within normal limits and systolic function is preserved in the face of mitral regurgitation. There is normal right atrial size with mild tricuspid regurgitation. There is no prolapse of the tricuspid valve leaflets and no evidence of pulmonary hypertension based upon tricuspid regurgitant velocities. The right ventricle subjectively appears normal in structure and function. The aortic and pulmonic valves have normal morphology and the corresponding outflow velocities are within normal limits. There is no evidence of pulmonic or aortic insufficiency. The aorta appears normal. The pulmonary artery and associated branches appear normal. There is no evidence of pleural effusion, pericardial effusion, or intracardiac masses.

**Review of Lateral Thoracic Image**

One lateral thoracic Image was provided for review. The entire pulmonary window is not visible. The pulmonary vasculature appears normal. The cardiac silhouette appears normal. There is no evidence of cardiogenic pulmonary edema.

**ULTRASONOGRAPHIC FINDINGS**



**PATIENT**

- Degenerative valve disease

Tank Cornforth

**INTERPRETATION OF THE FINDINGS & FURTHER RECOMMENDATIONS**

**SPECIES**

Canine

**BREED**

Pitbull

**SEX**

Neutered Male

**AGE**

12 Years

**WEIGHT**

73 Pounds

The patient continues to have degenerative valve disease and mitral regurgitation. The previous history from July reported having panting and exercise intolerance. The reported signs were consistent with ACVIM stage C or congestive heart failure. It was recommended that the patient be on furosemide, pimobendan, and then starting ace inhibitors and spironolactone. The medications reported for the patient only include furosemide at an unknown frequency. Given the current echocardiogram, and if the patient is receiving 20 mg of furosemide, it is unclear if the patient requires continued diuretic therapy. Can consider a trial off of the diuretic therapy. If the patient is not on pimobendan, then I recommend starting this therapy at a dose of 0.27 – 0.32 mg/kg twice daily. The reported kidney values are within normal limits. The patient does have elevated liver values. Recommend continued investigation and monitoring of those values. Can consider an abdominal ultrasound for further investigation. If continuing diuretic therapy, I also recommend the patient be started on an ace inhibitor and spironolactone. Ace inhibitor at a dose of 0.5 mg/kg once to twice daily, and spironolactone at a dose of 2.0 mg/kg once daily. 2-3 weeks after starting ace inhibition, recommend assessing kidney values again. If the patient remains on diuretic therapy, blood work to assess the kidney values every 4-6 months is recommended. Another echocardiogram is recommended in another 6 months time, sooner if cardiovascular clinical signs are worsening.

**INTERPRETED BY**

Sara Brethel DVM,  
DACVIM (Cardiology)

The client should start monitoring respiratory rate and effort at home if not already doing so. The resting respiratory rate should be < 35-40 breathes/minute when the patient is resting or sleeping. If the breathing rates are increasing, then chest radiographs are recommended.

**IMAGING PERFORMED BY**

Yvonna Aranda

If there is a concern for pulmonary pathology, recommend obtaining 3 view chest radiographs and submission for a radiologist evaluation.

**HOSPITAL NAME**

Countryside AC

**REFERRING VET**

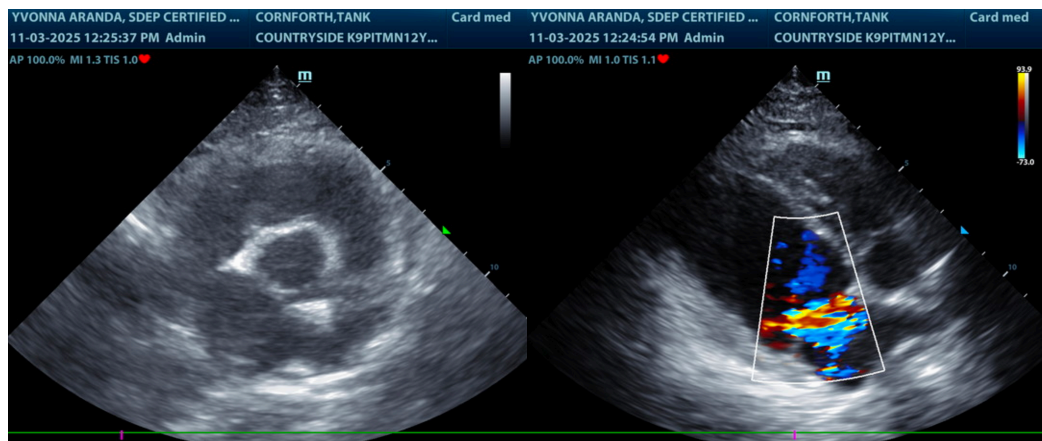
Dr. Cox

**INVOICE**

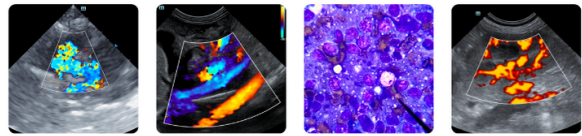
35408

**DATE**

11/4/25



**The information and recommendations provided are based on the images presented by the referring veterinarian/sonographer. No evaluation can be communicated regarding pathology**



**PATIENT**

Tank Cornforth

**SPECIES**

Canine

**BREED**

Pitbull

**SEX**

Neutered Male

**AGE**

12 Years

**WEIGHT**

73 Pounds

**INTERPRETED BY**

Sara Brethel DVM,  
DACVIM (Cardiology)

**IMAGING  
PERFORMED BY**

Yvonna Aranda

**HOSPITAL NAME**

Countryside AC

**REFERRING VET**

Dr. Cox

**INVOICE**

35408

**DATE**

11/4/25

**that was not visible in the image/video clips provided.**

Thank you for this referral. If the clinical or image interpretation does not parallel your findings or if I can be of any further assistance please contact me.

Sara Brethel DVM, DACVIM (Cardiology)

[info@SonoPath.com](mailto:info@SonoPath.com)