



PATIENT

Daisy Romeo

SPECIES

Canine

BREED

Cockapoo

SEX

Spayed Female

AGE

11 Years 4 Months

WEIGHT

28 Pounds

INTERPRETED BY

Sara Brethel DVM,
 DACVIM (Cardiology)

IMAGING PERFORMED BY

Dr. Ken Leal

HOSPITAL NAME

Plainfiled AH

REFERRING VET

Dr. Musum

INVOICE

35387

DATE

11/3/25

PRESENTING CLINICAL SIGNS

History of heart murmur - last echo (SonoPath) 11/18/24 Grade 3 heart murmur Medications: Nexgard and heartgard.

Abnormal PE/Chem/CBC/UA Results: AlkPhos = 179 TP = 7.9 PSL = 144 Albumin = 4.5

ULTRASONOGRAPHIC EXAMINATION OF THE HEART

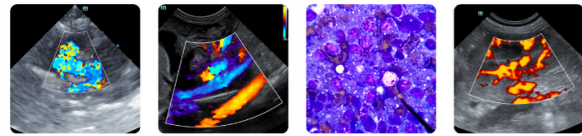
| CANINE CARDIAC PARAMETERS | MR VMAX (m/s) | TR VMAX (m/s) | LA/AO (M-Mode) | LA/AO (Heart Base; Swe) | FS (%) | EF (%) | EPSS (cm) |
|----------------------------------|-------------------------|-------------------------|--------------------------|-----------------------------------|--------------------------------|----------------------------------------------------|----------------------------------------------------|
| NORMAL PARAMETER | 4.5-5.5 | <2.7 | 1.3 | Up to 1.6 | 28-40 | 40-100 | <0.6 |
| PATIENT | Underest | ~2.0 | 1.75 | 1.51 | 43.58 | -- | 0.16 |
| CANINE CARDIAC PARAMETERS | HR (BPM) | AV VMAX (m/s) | PV MAX (m/s) | BODY WEIGHT (kg) | LAD LA MAX 4 Chamber | LVIDd Avg; 2D and m-mode short axis (cm) | LVIDs Avg; 2D and m-mode short axis (cm) |
| NORMAL PARAMETER | 50-100 | 0.7-1.7 | 0.7-1.6 | | | | |
| PATIENT | 122 | 1.74 | 0.75 | 12.72 | 3.4 | 3.9 | 2.2 |

Cardiac Presentation

The mitral valve leaflets are mildly thickened with mild mitral regurgitation posteriorly directed. There is no prolapse of the mitral valve leaflet. The left atrial size is mildly increased. Left ventricular diastolic dimensions are within normal limits but meet epic criteria and systolic function is preserved in the face of mitral regurgitation. There is normal right atrial size with mild tricuspid regurgitation. There is no prolapse of the tricuspid valve leaflets and no evidence of pulmonary hypertension based upon tricuspid regurgitant velocities. The right ventricle subjectively appears normal in structure and function. The aortic and pulmonic valves have normal morphology and the corresponding outflow velocities are within normal limits. There is evidence of pulmonic and aortic insufficiency. The aorta appears normal. The pulmonary artery and associated branches appear normal. There is no evidence of pleural effusion, pericardial effusion, or intracardiac masses.

ULTRASONOGRAPHIC FINDINGS

- Degenerative valve disease, ACVIM stage B-2
- Mild left atrial enlargement
- Mild left ventricular diastolic distention
- Aortic insufficiency



PATIENT

Daisy Romeo

- Pulmonic insufficiency
- Tricuspid regurgitation without evidence of significant pulmonary hypertension

SPECIES

Canine

BREED

Cockapoo

SEX

Spayed Female

AGE

11 Years 4 Months

WEIGHT

28 Pounds

INTERPRETED BY

Sara Brethel DVM,
DACVIM (Cardiology)

IMAGING PERFORMED BY

Dr. Ken Leal

HOSPITAL NAME

Plainfield AH

REFERRING VET

Dr. Musum

INVOICE

35387

DATE

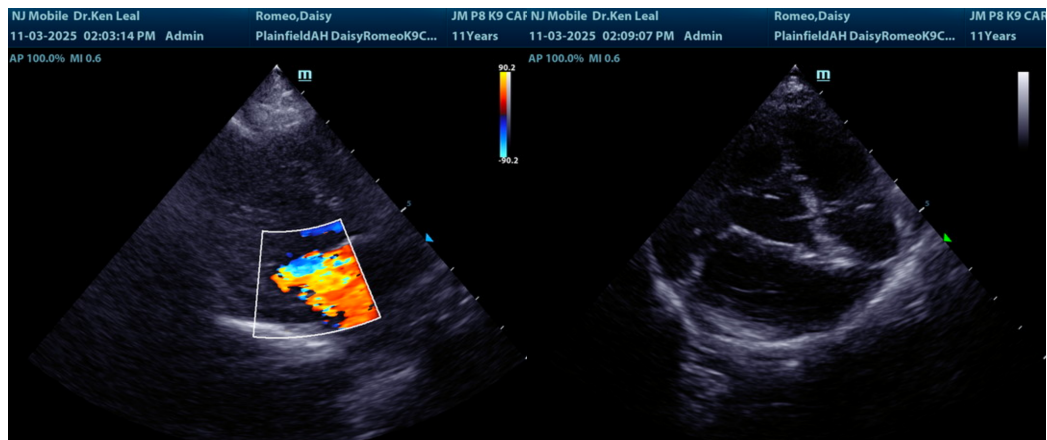
11/3/25

INTERPRETATION OF THE FINDINGS & FURTHER RECOMMENDATIONS

The patient has had some mild progression since the previous examination performed. The patient has degenerative valve disease ACVIM stage B2 and pimobendan therapy at 0.27-0.32mg/kg PO q12 is recommended. This will be a lifelong therapy. A recheck echocardiogram is recommended in 4-6 months to monitor the condition since starting pimobendan. A sooner recheck is recommended if the patient develops cardiovascular clinical signs or the heart murmur is worsening in intensity. The client should start monitoring respiratory rate and effort at home if not already doing so. The resting respiratory rate should be < 35-40 breathes/minute when the patient is resting or sleeping. If the breathing rates are increasing, then chest radiographs are recommended.

Recommend obtaining a blood pressure on the patient to ensure it is <160mmHg. If the blood pressure is elevated recommend following ACVIM guidelines for systemic hypertension and treating if indicated.

If anesthesia is needed, recommend the patient be on pimobendan for at least 1-3 weeks prior to elective anesthetic procedures. Judicious perioperative fluids are recommended due to the increased left atrial size. Medications like dexmedetomidine and other alpha 2 agonists are best avoided. Ketamine is also best avoided. If needed, anticholinergics can be used in the face of a clinically significant bradyarrhythmia (i.e., bradycardia with concurrent hypotension). If the patient is on an ACEi, recommend not giving this therapy the day of anesthesia.

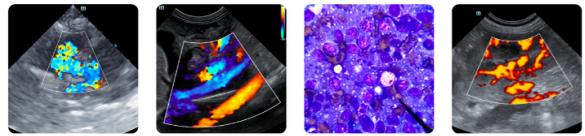


The information and recommendations provided are based on the images presented by the referring veterinarian/sonographer. No evaluation can be communicated regarding pathology that was not visible in the image/video clips provided.

Thank you for this referral. If the clinical or image interpretation does not parallel your findings or if I can be of any further assistance please contact me.

Sara Brethel DVM, DACVIM (Cardiology)

info@SonoPath.com



PATIENT

Daisy Romeo

SPECIES

Canine

BREED

Cockapoo

SEX

Spayed Female

AGE

11 Years 4 Months

WEIGHT

28 Pounds

INTERPRETED BY

Sara Brethel DVM,
DACVIM (Cardiology)

**IMAGING
PERFORMED BY**

Dr. Ken Leal

HOSPITAL NAME

Plainfiled AH

REFERRING VET

Dr. Musum

INVOICE

35387

DATE

11/3/25