

**PATIENT**

Chiquita Rodriguez

**SPECIES**

Canine

**BREED**

Chihuahua Mix

**SEX**

Spayed Female

**AGE**

10 Years

**WEIGHT**

Not Provided

**INTERPRETED BY**

Sara Brethel DVM,  
DACVIM (Cardiology)

**IMAGING PERFORMED BY**

Rebecca Hamilton

**HOSPITAL NAME**

Animal General  
Hudson

**REFERRING VET**

Dr. Lang

**INVOICE**

35633

**DATE**

11/24/25

**PRESENTING CLINICAL SIGNS**

History: Recheck echo- last performed in March 2024.

**ULTRASONOGRAPHIC EXAMINATION OF THE HEART**

<b>CANINE CARDIAC PARAMETERS</b>	<b>MR VMAX</b> (m/s)	<b>TR VMAX</b> (m/s)	<b>LA/AO</b> (M-Mode)	<b>LA/AO</b> (Heart Base; Swe)	<b>FS</b> (%)	<b>EF</b> (%)	<b>EPSS</b> (cm)
<b>NORMAL PARAMETER</b>	4.5-5.5	<2.7	1.3	Up to 1.6	28-40	40-100	<0.6
<b>PATIENT</b>	~5.5	3.4	2.47	2.35	55.26	--	NM
<b>CANINE CARDIAC PARAMETERS</b>	<b>HR</b> (BPM)	<b>AV VMAX</b> (m/s)	<b>PV MAX</b> (m/s)	<b>BODY WEIGHT</b> (kg)	<b>LAD</b> LA MAX 4 Chamber	<b>LVIDd</b> Avg; 2D and m-mode short axis (cm)	<b>LVIDs</b> Avg; 2D and m-mode short axis (cm)
<b>NORMAL PARAMETER</b>	50-100	0.7-1.7	0.7-1.6				
<b>PATIENT</b>	100	1.34	0.77	NP	4.69	3.8	1.7

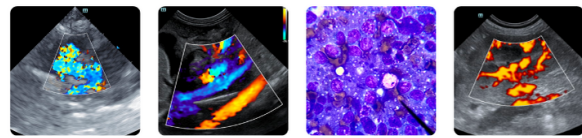
**Cardiac Presentation**

The mitral valve leaflets are moderately thickened with severe mitral regurgitation posteriorly directed. There appears to be at least a partial chordal rupture. The left atrial size is severely increased. Left ventricular internal dimensions during diastole are increased and systolic function is preserved in the face of mitral regurgitation. There is normal right atrial size with mild tricuspid regurgitation. There is billowing of the tricuspid valve leaflets and mild evidence of pulmonary hypertension based upon tricuspid regurgitant velocities. The right ventricle subjectively appears normal in structure and function. The aortic and pulmonic valves have normal morphology and the corresponding outflow velocities are within normal limits. There is no evidence of pulmonic or aortic insufficiency. The aorta appears normal. The pulmonary artery and associated branches appear normal. There is no evidence of pleural effusion, pericardial effusion, or intracardiac masses.

**ULTRASONOGRAPHIC FINDINGS**

- Degenerative valve disease, ACVIM stage B-2
- Degeneration of the tricuspid valve without evidence of clinically significant pulmonary hypertension

**INTERPRETATION OF THE FINDINGS & FURTHER RECOMMENDATIONS**



**PATIENT**

Chiquita Rodriguez

**SPECIES**

Canine

**BREED**

Chihuahua Mix

**SEX**

Spayed Female

**AGE**

10 Years

**WEIGHT**

Not Provided

**INTERPRETED BY**

Sara Brethel DVM,  
 DACVIM (Cardiology)

**IMAGING PERFORMED BY**

Rebecca Hamilton

**HOSPITAL NAME**

Animal General  
 Hudson

**REFERRING VET**

Dr. Lang

**INVOICE**

35633

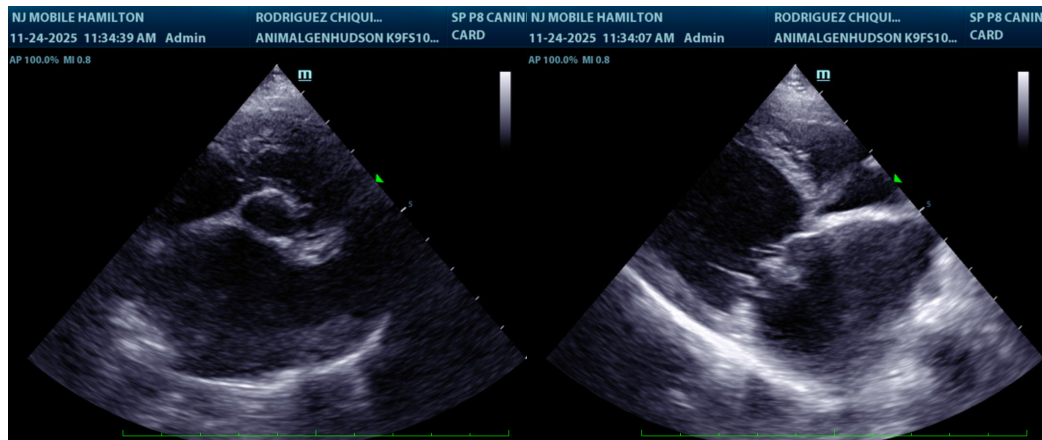
**DATE**

11/24/25

The patient continues to have degenerative valve disease, ACVIM stage B-2. Overall, the size appears to be stable when compared to the previous echocardiogram performed and left ventricular dimensions are mildly improved. In the history, it is not noted what therapies the patient is on, however, previously it was recommended for the patient to continue on pimobendan and start and ace inhibitor. Recheck echocardiogram is recommended in another 4-6 months, sooner if the patient develops cardiovascular clinical signs.

The client should start monitoring respiratory rate and effort at home if not already doing so. The resting respiratory rate should be < 35-40 breathes/minute when the patient is resting or sleeping. If the breathing rates are increasing, then chest radiographs are recommended.

Elective anesthetic procedures are not recommended for this patient.



**The information and recommendations provided are based on the images presented by the referring veterinarian/sonographer. No evaluation can be communicated regarding pathology that was not visible in the image/video clips provided.**

Thank you for this referral. If the clinical or image interpretation does not parallel your findings or if I can be of any further assistance please contact me.

Sara Brethel DVM, DACVIM (Cardiology)

[info@SonoPath.com](mailto:info@SonoPath.com)