

PATIENT

Maggie Eiseman

SPECIES

Canine

BREED

Pit bull

SEX

Spayed Female

AGE

6 Years

WEIGHT

59.4 Pounds

INTERPRETED BY

Sara Brethel DVM,
 DACVIM (Cardiology)

IMAGING PERFORMED BY

Andrea Nicastro, DVM,
 DACVIM

HOSPITAL NAME

Waterway AH

REFERRING VET

Dr. Roland

INVOICE

35491

DATE

11/12/25

PRESENTING CLINICAL SIGNS

History: New 3/6 murmur

Abnormal PE/Chem/CBC/UA Results: labs were declined. hw test negative HR/RR - 120 bpm / 24 bpm.

ULTRASONOGRAPHIC EXAMINATION OF THE HEART

| CANINE CARDIAC PARAMETERS | MR VMAX (m/s) | TR VMAX (m/s) | LA/AO (M-Mode) | LA/AO (Heart Base; Swe) | FS (%) | EF (%) | EPSS (cm) |
|---------------------------|---------------|---------------|----------------|-------------------------|----------------------|--|--|
| NORMAL PARAMETER | 4.5-5.5 | <2.7 | 1.3 | Up to 1.6 | 28-40 | 40-100 | <0.6 |
| PATIENT | ~5.0 | ~1.0 | NM | 1.46 | 38.13 | -- | NM |
| CANINE CARDIAC PARAMETERS | HR (BPM) | AV VMAX (m/s) | PV MAX (m/s) | BODY WEIGHT (kg) | LAD LA MAX 4 Chamber | LVIDd Avg; 2D and m-mode short axis (cm) | LVIDs Avg; 2D and m-mode short axis (cm) |
| NORMAL PARAMETER | 50-100 | 0.7-1.7 | 0.7-1.6 | | | | |
| PATIENT | -- | ~2.0 | -- | 27 | 4.8 | 4.3 | 2.66 |

Cardiac Presentation

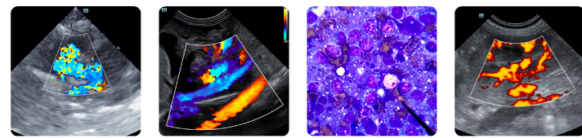
The mitral valve leaflets are mildly thickened with mild mitral regurgitation posteriorly directed. There is no prolapse of the mitral valve leaflets. The left atrial size is at the upper limits of normal to mildly increased on long axis assessment. Left ventricular internal dimensions during diastole are within normal limits and systolic function is preserved in the face of mitral regurgitation. There is normal right atrial size without tricuspid regurgitation. There is no prolapse of the tricuspid valve leaflets and no evidence of pulmonary hypertension based upon tricuspid regurgitant velocities. The right ventricle subjectively appears normal in structure and function. The aortic and pulmonic valves have normal morphology and the corresponding outflow velocities are within normal limits. There is no evidence of pulmonic or aortic insufficiency. The aorta appears normal. The pulmonary artery and associated branches appear normal. There is no evidence of pleural effusion, pericardial effusion, or intracardiac masses.

ULTRASONOGRAPHIC FINDINGS

- Degenerative valve disease, ACVIM stage B-1 (left atrium upper limits of normal to mildly increased on long axis assessment)

INTERPRETATION OF THE FINDINGS & FURTHER RECOMMENDATIONS

The patient has degenerative valve disease ACVIM stage B1 and no cardiac medications are indicated



PATIENT

Maggie Eiseman

SPECIES

Canine

BREED

Pit bull

SEX

Spayed Female

AGE

6 Years

WEIGHT

59.4 Pounds

INTERPRETED BY

Sara Brethel DVM,
 DACVIM (Cardiology)

IMAGING PERFORMED BY

Andrea Nicastro, DVM,
 DACVIM

HOSPITAL NAME

Waterway AH

REFERRING VET

Dr. Roland

INVOICE

35491

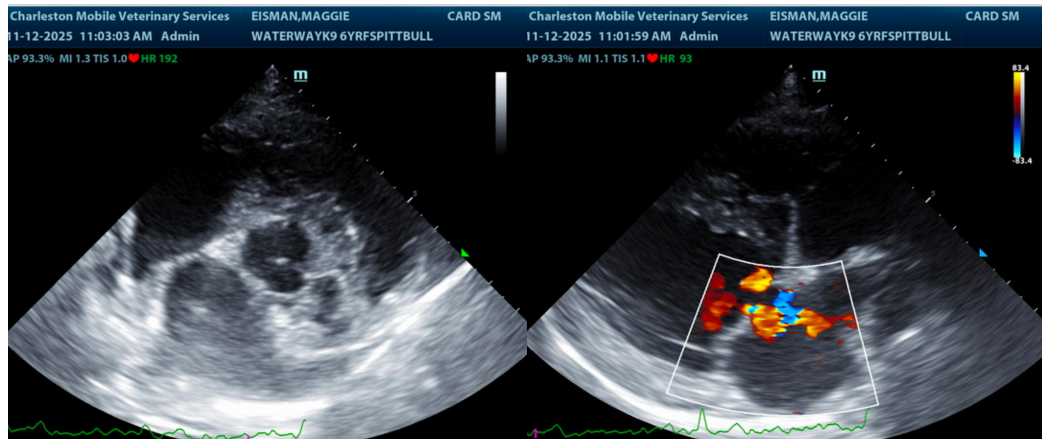
DATE

11/12/25

at this time. Since this can be a progressive condition, serial monitoring is recommended. A recheck echocardiogram is recommended in 4-6 months. A sooner recheck is recommended if the patient develops cardiovascular clinical signs or the heart murmur is worsening in intensity. Elective anesthetic procedures should be well tolerated.

Recommend obtaining a blood pressure on the patient to ensure it is <160mmHg. If the blood pressure is elevated recommend following ACVIM guidelines for systemic hypertension and treating if indicated.

Judicious perioperative fluids are recommended since the left atrial is at the upper limits of normal to mildly increased on long axis assessment. Medications like dexmedetomidine and other alpha 2 agonists are best avoided. Ketamine is also best avoided. If needed, anticholinergics can be used in the face of a clinically significant bradyarrhythmia (i.e., bradycardia with concurrent hypotension). If the patient is on an ACEi, recommend not giving this therapy the day of anesthesia.



The information and recommendations provided are based on the images presented by the referring veterinarian/sonographer. No evaluation can be communicated regarding pathology that was not visible in the image/video clips provided.

Thank you for this referral. If the clinical or image interpretation does not parallel your findings or if I can be of any further assistance please contact me.

Sara Brethel DVM, DACVIM (Cardiology)

info@SonoPath.com