

PATIENT

Disel Maracle

SPECIES

Canine

BREED

Bulldog

SEX

Intact Male

AGE

1 Year

WEIGHT

32.7 kg

INTERPRETED BY

Sara Brethel DVM,
 DACVIM (Cardiology)

IMAGING PERFORMED BY

Amanda Stewart

HOSPITAL NAME

Novel Vet

REFERRING VET

Dr. Laing

INVOICE

35234

DATE

1/5/26

PRESENTING CLINICAL SIGNS

History: entropion OS lower lid Corneal perforation corneal ulcer OS Current Medications Autogenous Serum, tobrex 0.3%, DECHRA Methadone 10 mg/mL Injectable.

Abnormal PE/Chem/CBC/UA Results: Primary Question to Be Answered in This Exam reason for abnormal T-wave.

ELECTROCARDIOGRAPHIC EXAMINATION

The rhythm appears to be sinus. There are portions with baseline artifact identified.

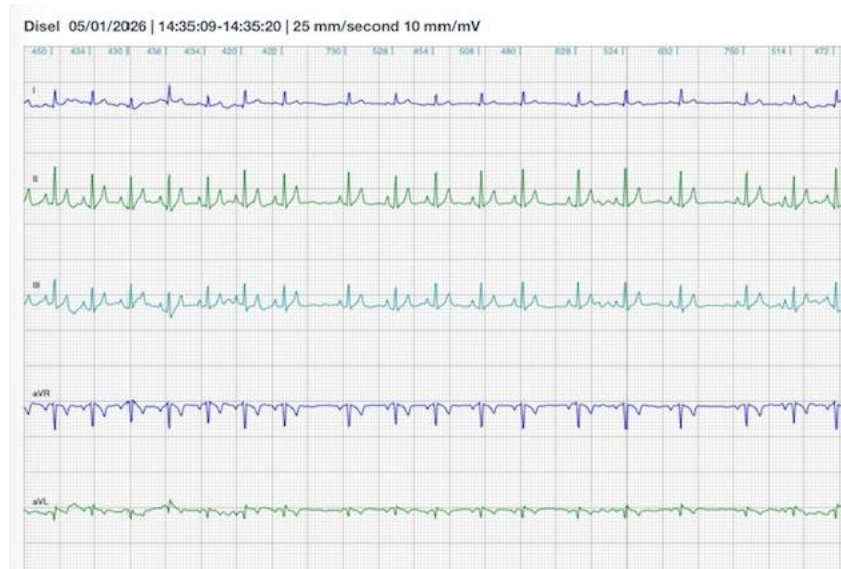ELECTROCARDIOGRAPHIC FINDINGS

- Sinus rhythm

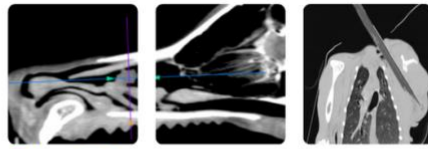
INTERPRETATION OF THE FINDINGS & FURTHER RECOMMENDATIONS

The rhythm appears to be sinus in origin. Abnormal t-waves are not appreciated. Recommend ensuring full bloodwork is normal, particularly potassium and other electrolytes. If there is concern for structural disease, recommend pursuing an echocardiogram. Due to the patient's age, it is reasonable to have an echocardiogram performed starting around 5 years of age as a screening process, as this breed can develop arrhythmogenic cardiomyopathy as they get older.

IMAGES



The information and recommendations provided are based on the images presented by the referring veterinarian/sonographer. No evaluation can be communicated regarding pathology that was not visible in the image/video clips provided.



PATIENT

Disel Maracle

SPECIES

Canine

BREED

Bulldog

SEX

Intact Male

AGE

1 Year

WEIGHT

32.7 kg

INTERPRETED BY

Sara Brethel DVM,
DACVIM (Cardiology)

**IMAGING
PERFORMED BY**

Amanda Stewart

HOSPITAL NAME

Novel Vet

REFERRING VET

Dr. Laing

INVOICE

35234

DATE

1/5/26

Thank you for this referral. If the clinical or image interpretation does not parallel your findings or if I can be of any further assistance please contact me.

Sara Brethel DVM, DACVIM (Cardiology)

info@SonoPath.com