

**PATIENT**

Thunder Reis

**SPECIES**

Feline

**BREED**

Maine Coon X

**SEX**

Neutered Male

**AGE**

3 Years

**WEIGHT**

14.6 Pounds

**INTERPRETED BY**

Sara Brethel, DVM,  
 DACVIM (Cardiology)

**IMAGING PERFORMED BY**

Sara Hansen

**HOSPITAL NAME**

Vetco, Center St. Salem

**REFERRING VET**

Dr. LaPoint

**INVOICE**

35613

**DATE**

1/29/26

**PRESENTING CLINICAL SIGNS**

Clinical Exam Findings: Murmur: Grade 1, harsh left lung sounds. P coughing at home 1-2 times a week.

**ULTRASONOGRAPHIC EXAMINATION OF THE HEART**

FELINE CARDIAC PARAMETERS	BODY WEIGHT (kg)	HR (BPM)	IVSd (cm)	LVIDd (cm)	LVWd (cm)	FS (%)	EF (%)
<b>NORMAL PARAMETER</b>	-----	150-240	0.3-0.6	1.0-2.1	0.25-0.6	35-67	80-100
<b>PATIENT</b>	6.63	NM	0.54	1.47	0.55	40.82	--
FELINE CARDIAC PARAMETERS	LA/AO (M-mode)	LA/AO HEART BASE (Sisson)	LAD LA MAX 4 Chamber		LVOT VEL. (m/s)	RVOT VEL. (m/s)	IVRT (m/)
<b>NORMAL PARAMETER</b>	<1.5	1.6	0.7-1.7		<1.6	<1.3	40-60
<b>PATIENT</b>	1.13	1.32	--		1.5	0.94	NM
Adapted from June Boon, Veterinary Echocardiography, 1998 Sisson D et al. JVIM 1991; 5: 232, Jacobs et al. Am J Vet Res 1985; 46:1705							

LVIDs: 0.87

**ECG Interpretation**

Normal sinus rhythm

**Cardiac Presentation**

The mitral valve leaflets are normal and there is no mitral regurgitation. The left atrial size is normal. There is no evidence of systolic anterior motion of the mitral valve and no evidence of a left ventricular outflow tract obstruction. Left ventricular systolic and diastolic function is within normal limits. There is no evidence of left ventricular concentric hypertrophy, however, the ventricular dimensions measure in a gray zone. There is normal right atrial size without evidence of tricuspid regurgitation. There is no prolapse of the tricuspid valve leaflets and no evidence of pulmonary hypertension on the images provided. The right ventricle appears normal in structure and function subjectively. The aortic and pulmonic valves have normal morphology and the corresponding outflow velocities are within normal limits. There is no evidence of pulmonic or aortic insufficiency. The aorta appears normal. The pulmonary artery and associated branches appear normal. There is no evidence of pleural effusion, pericardial effusion, or intracardiac masses.

**ULTRASONOGRAPHIC FINDINGS**

- Structurally normal heart with left ventricular measurements measuring in a gray zone



**PATIENT**

Thunder Reis

**SPECIES**

Feline

**BREED**

Maine Coon X

**SEX**

Neutered Male

**AGE**

3 Years

**WEIGHT**

14.6 Pounds

**INTERPRETED BY**

Sara Brethel, DVM,  
 DACVIM (Cardiology)

**IMAGING PERFORMED BY**

Sara Hansen

**HOSPITAL NAME**

Vetco, Center St. Salem

**REFERRING VET**

Dr. LaPoint

**INVOICE**

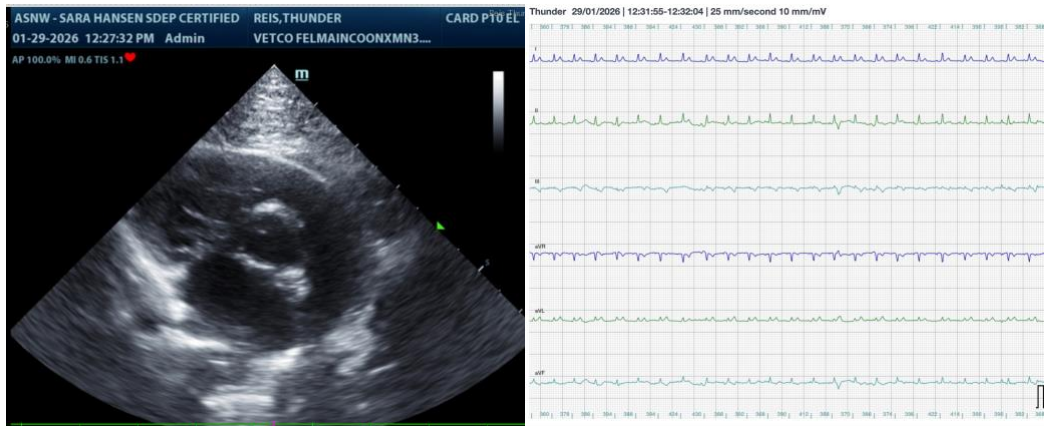
35613

**DATE**

1/29/26

**INTERPRETATION OF THE FINDINGS & FURTHER RECOMMENDATIONS**

The patient's heart is structurally normal. Left ventricular wall measurements are <6.0 mm, however, with the measurements being 5.5 mm, this does put the patient in a gray zone. Given the patient's breed, another echo is recommended in 10-12 months. However, the cause of the current clinical signs is not cardiac in nature. The murmur is likely innocent, and I would recommend evaluation of the airways as the primary cause of the patient's clinical signs.



**The information and recommendations provided are based on the images presented by the referring veterinarian/sonographer. No evaluation can be communicated regarding pathology that was not visible in the image/video clips provided.**

Thank you for this referral. If the clinical or image interpretation does not parallel your findings or if I can be of any further assistance please contact me.

Sara Brethel DVM, DACVIM (Cardiology)

[info@SonoPath.com](mailto:info@SonoPath.com)