

PATIENT

Pepper Brook

SPECIES

Canine

BREED

German Shepherd X

SEX

Spayed Female

AGE

2 Years

WEIGHT

56.18 Pounds

INTERPRETED BY

Sara Brethel, DVM,
DACVIM (Cardiology)

IMAGING PERFORMED BY

Sara Hansen

HOSPITAL NAME

Vetco, Center St. Salem

REFERRING VET

Dr. LaPoint

INVOICE

35615

DATE

1/29/26

PRESENTING CLINICAL SIGNS

Clinical Exam Findings: Grade 2 heart murmur

ULTRASONOGRAPHIC EXAMINATION OF THE HEART

CANINE CARDIAC PARAMETERS	MR VMAX (m/s)	TR VMAX (m/s)	LA/AO (M-Mode)	LA/AO (Heart Base; Swe)	FS (%)	EF (%)	EPSS (cm)
NORMAL PARAMETER	4.5-5.5	<2.7	1.3	Up to 1.6	28-40	40-100	<0.6
PATIENT	--	--	1.07	1.16	35.56	--	--
CANINE CARDIAC PARAMETERS	HR (BPM)	AV VMAX (m/s)	PV MAX (m/s)	BODY WEIGHT (kg)	LAD LA MAX 4 Chamber	LVIDd Avg; 2D and m-mode short axis (cm)	LVIDs Avg; 2D and m-mode short axis (cm)
NORMAL PARAMETER	50-100	0.7-1.7	0.7-1.6				
PATIENT	--	~2.2	1.0	25.54	3.5	3.88	2.5

ECG Interpretation

Normal sinus rhythm

Cardiac Presentation

The mitral valve leaflets are normal and there is no mitral regurgitation. There is no prolapse of the mitral valve leaflets. The left atrial size is normal. Left ventricular systolic and diastolic function is within normal limits. There is normal right atrial size without evidence of tricuspid regurgitation. There is no prolapse of the tricuspid valve leaflets and no evidence of pulmonary hypertension on today's evaluation. The right ventricle subjectively appears normal in structure and function. The aortic and pulmonic valves have normal morphology and the corresponding outflow velocities are within normal limits. Aortic outflow velocities are at the upper limits of normal. There is no evidence of pulmonic or aortic insufficiency. The aorta appears normal. The pulmonary artery and associated branches appear normal. There is no evidence of pleural effusion, pericardial effusion, or intracardiac masses.

ULTRASONOGRAPHIC FINDINGS

- Physiologic murmur
- Aortic outflow velocities upper limits of normal

INTERPRETATION OF THE FINDINGS & FURTHER RECOMMENDATIONS



PATIENT

Pepper Brook

SPECIES

Canine

BREED

German Shepherd X

SEX

Spayed Female

AGE

2 Years

WEIGHT

56.18 Pounds

INTERPRETED BY

Sara Brethel, DVM,
DACVIM (Cardiology)

IMAGING PERFORMED BY

Sara Hansen

HOSPITAL NAME

Vetco, Center St. Salem

REFERRING VET

Dr. LaPoint

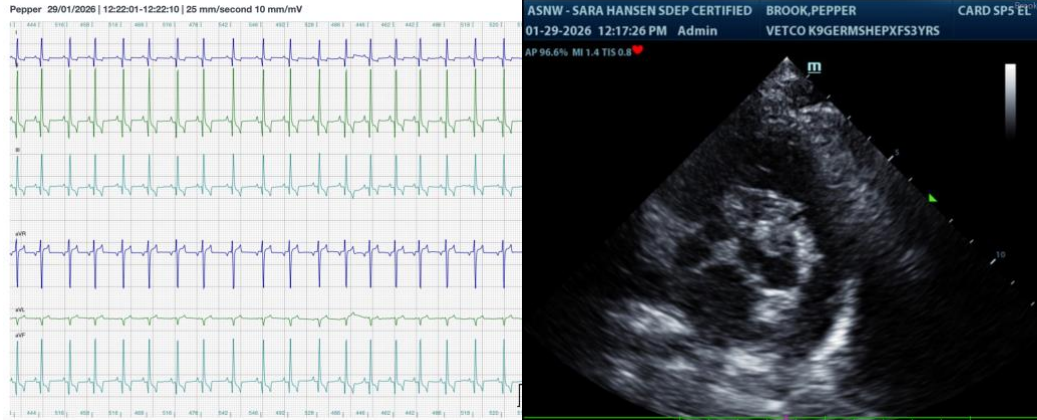
INVOICE

35615

DATE

1/29/26

The heart is structurally normal. Aortic outflow velocities are at the upper limits of normal, which is not a cause for concern. No cardiac therapies are recommended. A recheck echo is not needed unless the patient develops a new heart murmur or the current heart murmur is increasing in intensity.



The information and recommendations provided are based on the images presented by the referring veterinarian/sonographer. No evaluation can be communicated regarding pathology that was not visible in the image/video clips provided.

Thank you for this referral. If the clinical or image interpretation does not parallel your findings or if I can be of any further assistance please contact me.

Sara Brethel DVM, DACVIM (Cardiology)

info@SonoPath.com