



PATIENT

Hyacinth Sterling

SPECIES

Feline

BREED

Himalayan

SEX

Spayed Female

AGE

9 Years

WEIGHT

9.70 pounds

INTERPRETED BY

Sara Brethel, DVM,
 DACVIM (Cardiology)

PRESENTING CLINICAL SIGNS

- Clinical Exam Findings: Grade 4/6 SHM, borderline hypertension. P is scheduled for dental cleaning due to gingivitis
- Is there a Heart Murmur? If so, please grade: 4/6
- Notes to Specialist (if any): Primary question to be answered: Heart health and pre-anesthetic screening

ULTRASONOGRAPHIC EXAMINATION OF THE HEART

FELINE CARDIAC PARAMETERS	BODY WEIGHT (kg)	HR (BPM)	IVSd (cm)	LVIDd (cm)	LVWd (cm)	FS (%)	EF (%)
NORMAL PARAMETER	-----	150-240	0.3-0.6	1.0-2.1	0.25-0.6	35-67	80-100
PATIENT	4.4	NM	0.65	1.43	0.41	--	--
FELINE CARDIAC PARAMETERS	LA/AO (M-mode)	LA/AO HEART BASE (Sisson)	LAD LA MAX 4 Chamber		LVOT VEL. (m/s)	RVOT VEL. (m/s)	IVRT (m/)
NORMAL PARAMETER	<1.5	1.6	0.7-1.7		<1.6	<1.3	40-60
PATIENT	1.25	1.22	--		1.06	0.87	NM
Adapted from June Boon, Veterinary Echocardiography, 1998 Sisson D et al. JVIM 1991; 5: 232, Jacobs et al. Am J Vet Res 1985; 46:1705							

IMAGING PERFORMED BY

Sara Hansen

HOSPITAL NAME

West Hills Animal Hospital

REFERRING VET

Dr. Remcho

INVOICE

13433

DATE

01/28/26

Cardiac Presentation

The left atrium is within normal limits. The mitral valve leaflets are normal and there is no mitral regurgitation. There is no evidence of systolic anterior motion of the mitral valve and no evidence of a left ventricular outflow tract obstruction. There is concentric hypertrophy of the left ventricle. The right atrium is normal. The tricuspid valve is normal without evidence of tricuspid regurgitation. The right ventricle appears to have preserved systolic function subjectively. The aortic and pulmonic valves are normal without evidence of insufficiency. Aortic and pulmonic outflow velocities are within normal limits. The aorta and PA are normal along with the associated PA branches. There is no evidence of pleural effusion, pericardial effusion, or intracardiac masses.

ULTRASONOGRAPHIC FINDINGS

- Left ventricular concentric hypertrophy.
- Normal left atrial size.

INTERPRETATION OF THE FINDINGS & FURTHER RECOMMENDATIONS

The patient has evidence of left ventricular concentric hypertrophy and is classified as a stage B1 due to the normal left atrial size. If not already performed, it is recommended to ensure that patient's blood pressure is normal, and the patient is euthyroid. If the patient is euthyroid and normotensive, then the



PATIENT

Hyacinth Sterling

SPECIES

Feline

BREED

Himalayan

SEX

Spayed Female

AGE

9 Years

WEIGHT

9.70 pounds

INTERPRETED BY

Sara Brethel, DVM,
DACVIM (Cardiology)

IMAGING PERFORMED BY

Sara Hansen

HOSPITAL NAME

West Hills Animal
Hospital

REFERRING VET

Dr. Remcho

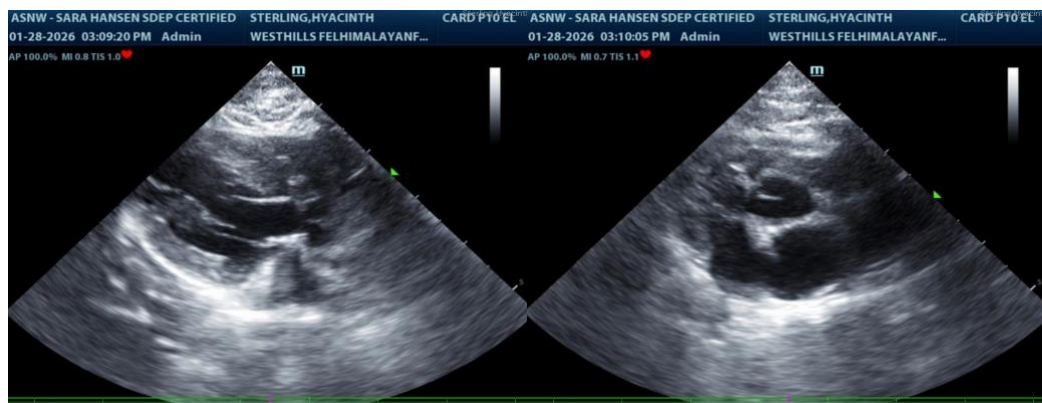
INVOICE

13433

DATE

01/28/26

patient has underlying hypertrophic cardiomyopathy. No cardiac medications are indicated at this time as the patient is at a low risk for complications associated with this condition. Since this can be a progressive condition, serial monitoring is recommended. It's recommended to recheck an echocardiogram in 6 months, sooner if the patient develops cardiovascular clinical signs. I recommend monitoring of the blood pressure with the reported borderline hypertension. Standard perioperative fluid rates should be well-tolerated. Medications like dexmedetomidine and other alpha 2 agonists are best avoided. Ketamine is also best avoided. Anticholinergics can be used in the case of a clinically significant bradyarrhythmia (i.e., bradycardia with concurrent hypotension). If the patient is on an ACEi, recommend not giving this therapy the day of anesthesia.



The information and recommendations provided are based on the images presented by the referring veterinarian/sonographer. No evaluation can be communicated regarding pathology that was not visible in the image/video clips provided.

Thank you for this referral. If the clinical or image interpretation does not parallel your findings or if I can be of any further assistance please contact me.

Sara Brethel, DVM, DACVIM (Cardiology)

info@SonoPath.com