



**PATIENT**

Jagger Fitzpatrick

**SPECIES**

Canine

**BREED**

Dachshund Mix

**SEX**

Neutered Male

**AGE**

10 Years 10 Months

**WEIGHT**

18.2 Pounds

**INTERPRETED BY**

Sara Brethel DVM,  
DACVIM (Cardiology)

**IMAGING PERFORMED BY**

Rebecca Hamilton

**HOSPITAL NAME**

Wantage VH

**REFERRING VET**

Dr. Bullock

**INVOICE**

35399

**DATE**

1/13/26

**PRESENTING CLINICAL SIGNS**

History: No clinical signs, 4/6 systolic murmur. Had echo 2/14/25. Meds: Pimobendan 2.5 mg BID since 2/14/25. No exercise intolerance or coughing even before starting meds.

Abnormal PE/Chem/CBC/UA Results: NSF, Urine: Low ph 5, USG 1.044

**ULTRASONOGRAPHIC EXAMINATION OF THE HEART**

CANINE CARDIAC PARAMETERS	MR VMAX (m/s)	TR VMAX (m/s)	LA/AO (M-Mode)	LA/AO (Heart Base; Swe)	FS (%)	EF (%)	EPSS (cm)
NORMAL PARAMETER	4.5-5.5	<2.7	1.3	Up to 1.6	28-40	40-100	<0.6
PATIENT	6.17	~2.0	1.06	1.5	58.86	89.74	0.16
CANINE CARDIAC PARAMETERS	HR (BPM)	AV VMAX (m/s)	PV MAX (m/s)	BODY WEIGHT (kg)	LAD LA MAX 4 Chamber	LVIDd Avg; 2D and m-mode short axis (cm)	LVIDs Avg; 2D and m-mode short axis (cm)
NORMAL PARAMETER	50-100	0.7-1.7	0.7-1.6				
PATIENT	132	2.33	1.05	8.27	3.3	2.89	1.19

**Cardiac Presentation**

The mitral valve leaflets are mildly thickened with mild mitral regurgitation posteriorly directed. There is no prolapse of the mitral valve leaflet. The left atrial size is mildly increased on long axis assessment. Left ventricular internal dimensions during diastole are within normal limits and systolic function is preserved in the face of mitral regurgitation. There is normal right atrial size with mild tricuspid regurgitation. There is no prolapse of the tricuspid valve leaflets and no evidence of pulmonary hypertension based upon tricuspid regurgitant velocities. The right ventricle subjectively appears normal in structure and function. The aortic and pulmonic valves have normal morphology and the corresponding outflow velocities are within normal limits. There is no evidence of pulmonic or aortic insufficiency. The aorta appears normal. The pulmonary artery and associated branches appear normal. There is no evidence of pleural effusion, pericardial effusion, or intracardiac masses.

**ULTRASONOGRAPHIC FINDINGS**

- Degenerative valve disease, ACVIM stage B-2
- Mild left atrial enlargement

**INTERPRETATION OF THE FINDINGS & FURTHER RECOMMENDATIONS**



**PATIENT**

Jagger Fitzpatrick

**SPECIES**

Canine

**BREED**

Dachshund Mix

**SEX**

Neutered Male

**AGE**

10 Years 10 Months

**WEIGHT**

18.2 Pounds

**INTERPRETED BY**

Sara Brethel DVM,  
 DACVIM (Cardiology)

**IMAGING PERFORMED BY**

Rebecca Hamilton

**HOSPITAL NAME**

Wantage VH

**REFERRING VET**

Dr. Bullock

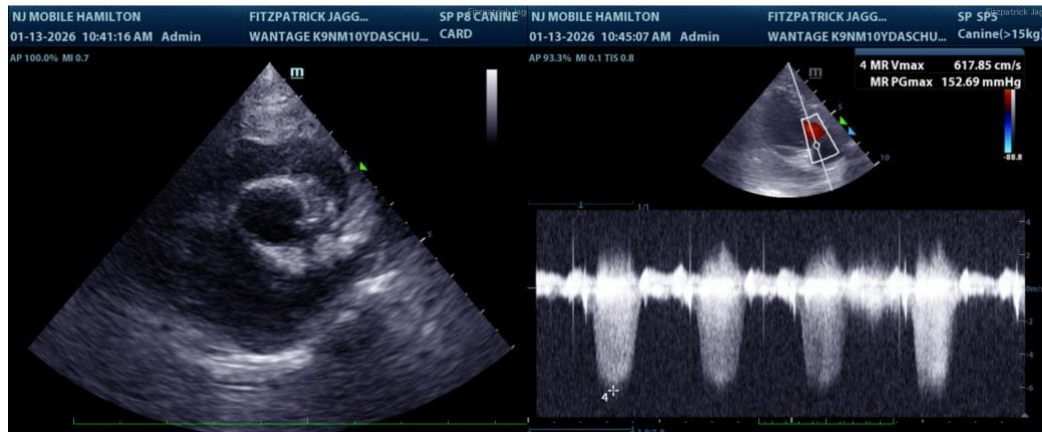
**INVOICE**

35399

**DATE**

1/13/26

The patient continues to have mild left atrial enlargement, but otherwise, the disease appears well controlled on the current pimobendan therapy. No changes are recommended at this time. Recheck echocardiogram is recommended in 10-12 months, sooner if the murmur is changing in intensity or the patient is developing cardiovascular clinical signs. Recommend obtaining a blood pressure on the patient to ensure it is <160mmHg. If the blood pressure is elevated recommend following ACVIM guidelines for systemic hypertension and treating if indicated. If anesthesia is needed, the patient appears to be an adequate candidate. Judicious perioperative fluids are recommended due to the increased left atrial size. Medications like dexmedetomidine and other alpha 2 agonists are best avoided. Ketamine is also best avoided. If needed, anticholinergics can be used in the face of a clinically significant bradyarrhythmia (i.e., bradycardia with concurrent hypotension). If the patient is on an ACEi, recommend not giving this therapy the day of anesthesia.



**The information and recommendations provided are based on the images presented by the referring veterinarian/sonographer. No evaluation can be communicated regarding pathology that was not visible in the image/video clips provided.**

Thank you for this referral. If the clinical or image interpretation does not parallel your findings or if I can be of any further assistance please contact me.

Sara Brethel DVM, DACVIM (Cardiology)

[info@SonoPath.com](mailto:info@SonoPath.com)