



PATIENT

Malcolm Madrid

SPECIES

Canine

BREED

Mixed

SEX

Neutered Male

AGE

11 Years

WEIGHT

35.6 pounds

INTERPRETED BY

Sara Brethel, DVM,
DACVIM (Cardiology)

IMAGING PERFORMED BY

Sara Hansen

HOSPITAL NAME

Banfield Pet Hospital-
North Eugene

REFERRING VET

Dr. Mirate

INVOICE

13121

DATE

01/12/26

PRESENTING CLINICAL SIGNS

H/L: Murmur grade 3-4/6, lungs clear GI/UG: NAF M/S: Brief exam, AMB X4 Neuro: Appropriate, full neuro not performed LNN: NAF ABNORMAL Labwork Values Cardiopet 1066 (0-900 for normal range) For ECHO Only: Blood Pressure Not taken HR/RR/BP: 130 / Sniffing Is there a Heart Murmur? If so, please grade. Yes, 3-4/6 Current Medications None Radiographic Findings N/A

ULTRASONOGRAPHIC EXAMINATION OF THE HEART

CANINE CARDIAC PARAMETERS	MR VMAX (m/s)	TR VMAX (m/s)	LA/AO (M-Mode)	LA/AO (Heart Base; Swe)	FS (%)	EF (%)	EPSS (cm)
NORMAL PARAMETER	4.5-5.5	<2.7	1.3	Up to 1.6	28-40	40-100	<0.6
PATIENT	6.69	--	NM	1.47	45.94	--	NM
CANINE CARDIAC PARAMETERS	HR (BPM)	AV VMAX (m/s)	PV MAX (m/s)	BODY WEIGHT (kg)	LAD LA MAX 4 Chamber	LVIDd Avg; 2D and m-mode short axis (cm)	LVIDs Avg; 2D and m-mode short axis (cm)
NORMAL PARAMETER	50-100	0.7-1.7	0.7-1.6				
PATIENT	--	2.31	1.84	16.18	3.99	3.7	2.0

Cardiac Presentation

The mitral valve leaflets are mildly thickened with mild mitral regurgitation posteriorly directed. There is no prolapse of the mitral valve leaflets. The left atrial size is normal. Left ventricular internal dimensions during diastole are within normal limits and systolic function is preserved in the face of mitral regurgitation. There is normal right atrial size without tricuspid regurgitation. There is no prolapse of the tricuspid valve leaflets and no evidence of pulmonary hypertension based upon tricuspid regurgitant velocities. The right ventricle subjectively appears normal in structure and function. The aortic and pulmonic valves have normal morphology and the corresponding outflow velocities are within normal limits. There is no evidence of pulmonic or aortic insufficiency. The aorta appears normal. The pulmonary artery and associated branches appear normal. There is no evidence of pleural effusion, pericardial effusion, or intracardiac masses.

ULTRASONOGRAPHIC FINDINGS

- Degenerative valve disease ACVIM stage B1.
- Normal left atrial size (left atrium upper limits of normal).

INTERPRETATION OF THE FINDINGS & FURTHER RECOMMENDATIONS

The patient has degenerative valve disease ACVIM stage B1 and no cardiac medications are indicated at this time. Since this can be a progressive condition, serial monitoring is recommended. A recheck



PATIENT

Malcolm Madrid

echocardiogram is recommended in 6 months due to the left atrium being at the upper limits of normal. A sooner recheck is recommended if the patient develops cardiovascular clinical signs or the heart murmur is worsening in intensity. Elective anesthetic procedures should be well tolerated.

SPECIES

Canine

Recommend obtaining a blood pressure on the patient to ensure it is <160mmHg. If the blood pressure is elevated recommend following ACVIM guidelines for systemic hypertension and treating if indicated.

BREED

Mixed

Standard perioperative fluid rates should be well-tolerated. Medications like dexmedetomidine and other alpha 2 agonists are best avoided. Ketamine is also best avoided. Anticholinergics can be used in the case of a clinically significant bradyarrhythmia (i.e., bradycardia with concurrent hypotension). If the patient is on an ACEi, recommend not giving this therapy the day of anesthesia.

SEX

Neutered Male

AGE

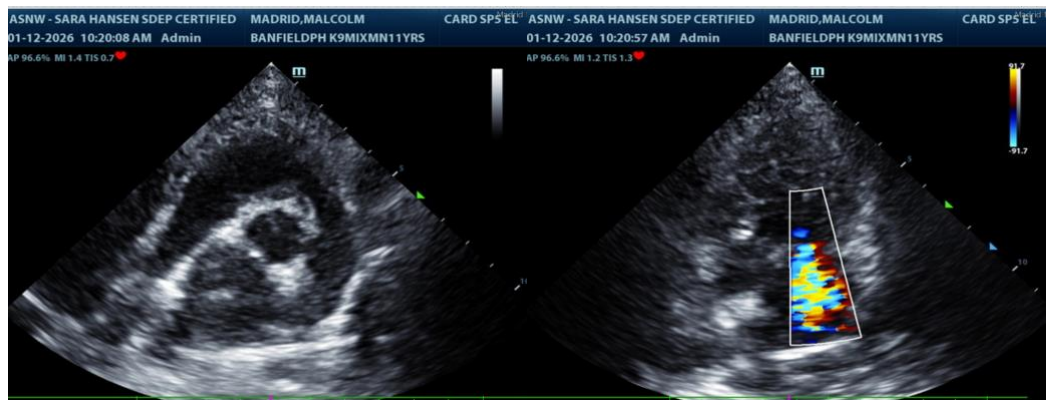
11 Years

WEIGHT

35.6 pounds

INTERPRETED BY

Sara Brethel, DVM,
 DACVIM (Cardiology)



The information and recommendations provided are based on the images presented by the referring veterinarian/sonographer. No evaluation can be communicated regarding pathology that was not visible in the image/video clips provided.

IMAGING PERFORMED BY

Sara Hansen

Thank you for this referral. If the clinical or image interpretation does not parallel your findings or if I can be of any further assistance please contact me.

HOSPITAL NAME

Banfield Pet Hospital-
 North Eugene

Sara Brethel DVM, DACVIM (Cardiology)

info@SonoPath.com

REFERRING VET

Dr. Mirate

INVOICE

13121

DATE

01/12/26