

PATIENT

Signalment

10-year-old neutered male DSH.

Yeti Eure

SPECIES

History

Wolf-Parkinson-White syndrome diagnosed as a kitten and successfully managed with diltiazem and sotalol with no further issues or arrhythmias. Recently diagnosed with pancreatitis with cyst formation.

Feline

BREED

Hematology

Mild neutrophilia (10.61).

Domestic Shorthair

SEX

Serum Biochemistry

Elevated ALT activity (526).

Elevated fPL (32.5).

Neutered male

AGE

Abdominal Ultrasound

- Pancreatic cyst/abscess.
- Ascites.
- Mild splenomegaly.
- Mild hepatopathy.
- Age-related renal changes.

10 years

WEIGHT

7.7 lbs

INTERPRETED BY

Cytology

Mixed inflammatory reaction within the pancreatic cystic fluid.

Remo Lobetti, BVSc,
MMedVet (Med),
PhD, Dipl. ECVIM

Culture

Negative aerobic culture.

Anaerobic culture yielded *Clostridium perfringens*.

IMAGING PERFORMED BY

Interpretation

The pancreatic cyst would be a complication of the pancreatitis and can based on the cytology be considered inflammatory in nature.

Tracy Eure

HOSPITAL NAME

The presence of *Clostridium* within the cyst implies that it is a secondary infection as *Clostridium* does not form part of the normal pancreatic flora and thus represents pathologic contamination of the cyst, which can be considered an anaerobic environment.

Moyock AH

REFERRING VET

The mild neutrophilia, ascites, splenomegaly, and hepatopathy can all be attributed to the pancreatitis.

Dr. Eure

Further Assessment

- Repeat ALT activity and fPL to monitor progression and/or possible deterioration.

INVOICE

69519

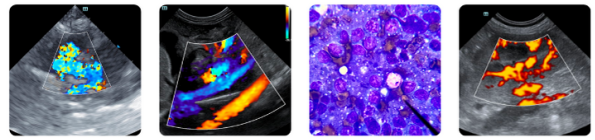
Management

DATE

Three options for the pancreatic cyst would be:

12/23/25

- Ideal therapy would be surgical removal of the cyst.
- Percutaneous drainage and instilling a combination of intravenous formulations of metronidazole and penicillin into the cavity, which may need to be repeated. Dose of both drugs would be 20 mg/kg mixed with \pm 5 mls of saline.



PATIENT

Yeti Eure

SPECIES

Feline

BREED

Domestic Shorthair

SEX

Neutered male

AGE

10 years

WEIGHT

7.7 lbs

INTERPRETED BY

Remo Lobetti, BVSc,
MMedVet (Med),
PhD, Dipl. ECVIM

IMAGING PERFORMED BY

Tracy Eure

HOSPITAL NAME

Moyock AH

REFERRING VET

Dr. Eure

INVOICE

69519

DATE

12/23/25

- Intermittent percutaneous drainage of the cyst and continuing with systemic antibiotic therapy using a combination of metronidazole and penicillin.

Long-term management of the pancreatitis would be feeding small frequent meals of a low-fat intestinal diet.

Monitoring for the development of diabetes mellitus and/or exocrine pancreatic insufficiency would be recommended.

The information and recommendations provided are based on the images presented by the referring veterinarian/sonographer. No evaluation can be communicated regarding pathology that was not visible in the image/video clips provided.

Thank you for this referral. If the clinical or image interpretation does not parallel your findings or if I can be of any further assistance please contact me.

Remo Lobetti, BVSc, MMedVet (Med), PhD, Dipl. ECVIM

info@SonoPath.com