



PATIENT

Daphne Klimen

SPECIES

Canine

BREED

Pit Mix

SEX

Spayed female

AGE

13 years

WEIGHT

53.5 lbs

INTERPRETED BY

Remo Lobetti, BVSc,
MMedVet (Med),
PhD, Dipl. ECVIM

IMAGING PERFORMED BY

Rebecca Hamilton

HOSPITAL NAME

Montclair AH

REFERRING VET

Dr. Stoin

INVOICE

78409

DATE

6/8/26

PRESENTING CLINICAL SIGNS

History: Pu/Pd, polyphagia, mildly elevated ALT, Stable grade 2/6 HM and multiple dermal + SQ masses. Meds: Proin
Platelets 378K, ALT 128, ALP 433, USG 1.012

ULTRASONOGRAPHIC EXAMINATION OF THE ABDOMEN

Urinary System

The urinary bladder is full with a normal thickness and smooth appearance of the wall. Normal anechoic urine with no sediment or uroliths evident.

Normal appearance of the trigone area, proximal urethra, and iliac blood vessels.

Normal appearance and size of the iliac lymph nodes. Ureters not visualized, which can be considered a normal finding.

Normal renal size (left measured 6.0 cm, right measured 5.8 cm), architecture, echogenic appearance, cortico-medullary differentiation, which maintains a 1:3 cortex to medulla ratio, pelvis, and capsule. No infarcts, mineralization or renoliths evident. Normal color flow pattern is evident in both kidneys.

Adrenal Glands

Normal shape, echogenic appearance, size, position, and appearance of the visible peri-adrenal vasculature. Left adrenal gland measured 2.67 cm in length x 0.65 cm and 0.7 cm in width. The right adrenal gland measured 2.71 cm in length x 0.71 cm in width.

Spleen

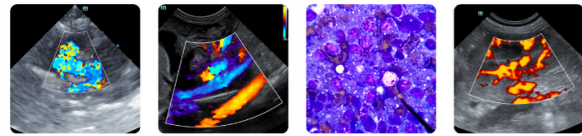
Normal size and echogenic appearance. Smooth homogenous parenchyma and regular curvilinear capsule. Normal volume of the splenic vasculature without any overt congestion or thrombosis evident. No inflammatory, neoplastic, infarction, or infiltrative changes evident. The spleen measured 1.9 cm in width.

Liver

Normal size with a diffuse, increased echogenic and coarse appearance, normal portal markings, and regular curvilinear capsule. No nodules or masses evident. Normal appearance of the hepatic and portal vasculature.

Gallbladder

The gallbladder is full containing normal anechoic bile. Normal thickness and echogenic appearance of the wall. Normal size and appearance of the cystic and common bile duct.



PATIENT

Daphne Klimen

SPECIES

Canine

BREED

Pit Mix

SEX

Spayed female

AGE

13 years

WEIGHT

53.5 lbs

INTERPRETED BY

Remo Lobetti, BVSc,
MMedVet (Med),
PhD, Dipl. ECVIM

IMAGING PERFORMED BY

Rebecca Hamilton

HOSPITAL NAME

Montclair AH

REFERRING VET

Dr. Stoin

INVOICE

78409

DATE

6/8/26

Gastrointestinal

Normal appearance of the stomach, duodenum, small intestine, ileo-cecal junction, and colon with no loss of layering, 1:3 muscularis to mucosa ratio, normal wall thickness and peristaltic activity, and no distension of the lumen.

Pancreas

The visible sections of the pancreas are of normal size and echogenic appearance with a regular capsule. Normal echogenic appearance of the mesentery and fat surrounding the pancreas.

Free Abdomen

Normal mesenteric lymph nodes.

No ascites evident.

ULTRASONOGRAPHIC FINDINGS

- Hepatopathy.

INTERPRETATION OF THE FINDINGS & FURTHER RECOMMENDATIONS

Etiologies for the hepatopathy would be reactive hyperplasia, vacuolar and metabolic with hepatitis and infiltrative neoplasia an unlikely differential diagnosis.

Although the adrenal glands appear ultrasonographically normal with the presenting clinical signs and the hepatopathy, pituitary dependent Cushing's disease should still be considered.

Further assessment would be urine specific gravity and urine cortisol to creatinine ratio and if abnormal then adrenal function testing (ACTH stimulation/LDDST) would then be indicated.

If Cushing's disease has been excluded, then further assessment of the hepatopathy would be FNA cytology; however, a tru cut or wedge biopsy may be required for a final etiological diagnosis.

Specific therapy would be dependent on an etiological diagnosis.

Symptomatic management of the hepatopathy that could be considered would be the use of Ursodiol with regular monitoring of liver enzyme activity.



PATIENT

Daphne Klimen

SPECIES

Canine

BREED

Pit Mix

SEX

Spayed female

AGE

13 years

WEIGHT

53.5 lbs

INTERPRETED BY

Remo Lobetti, BVSc,
 MMedVet (Med),
 PhD, Dipl. ECVIM

IMAGING PERFORMED BY

Rebecca Hamilton

HOSPITAL NAME

Montclair AH

REFERRING VET

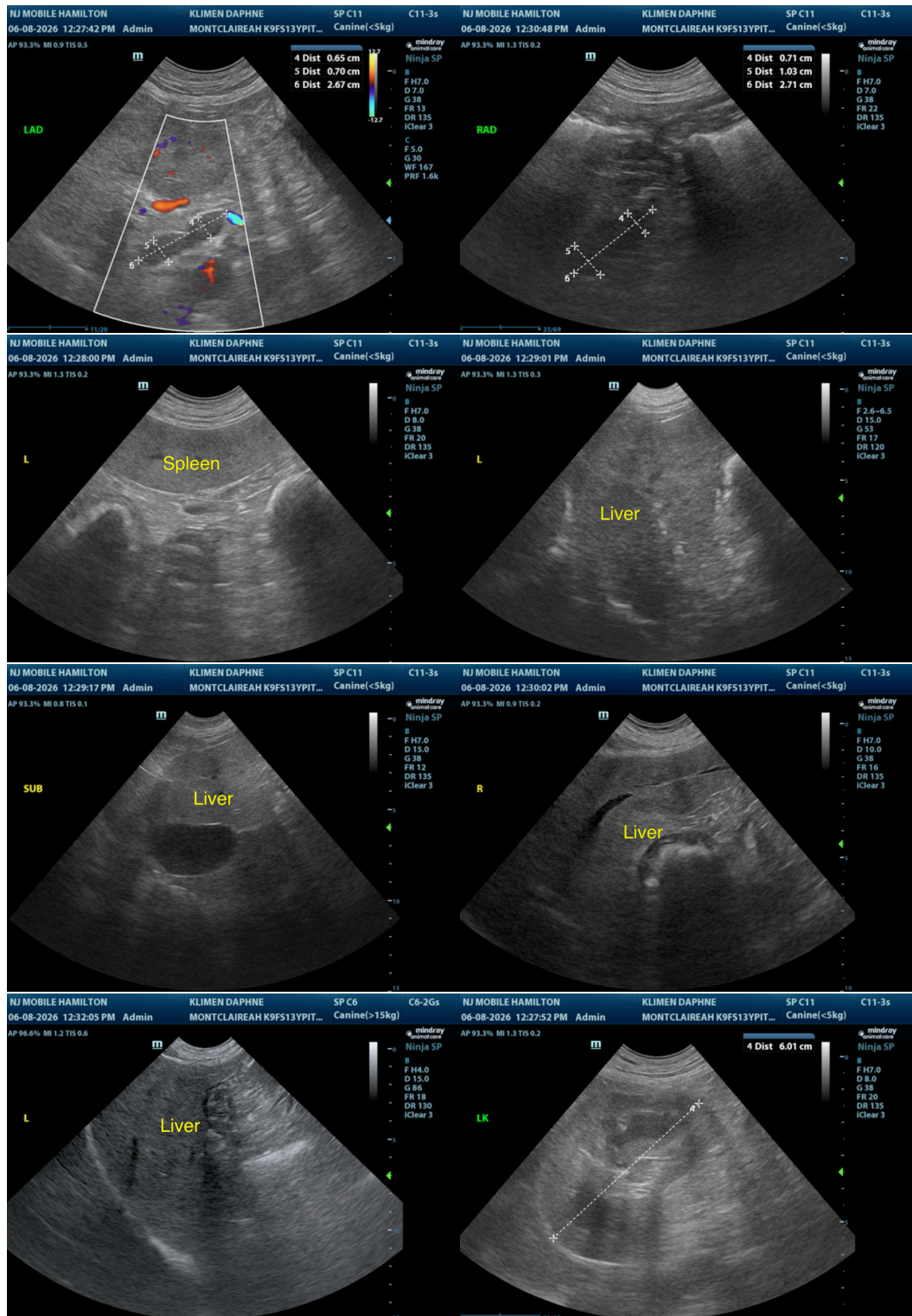
Dr. Stoin

INVOICE

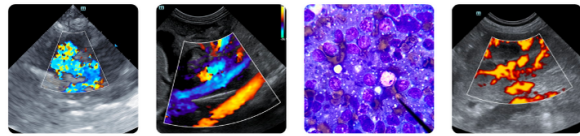
78409

DATE

6/8/26



The information and recommendations provided are based on the images presented by the



PATIENT

Daphne Klimen

SPECIES

Canine

BREED

Pit Mix

SEX

Spayed female

AGE

13 years

WEIGHT

53.5 lbs

INTERPRETED BY

Remo Lobetti, BVSc,
MMedVet (Med),
PhD, Dipl. ECVIM

**IMAGING
PERFORMED BY**

Rebecca Hamilton

HOSPITAL NAME

Montclair AH

REFERRING VET

Dr. Stoin

INVOICE

78409

DATE

6/8/26

referring veterinarian/sonographer. No evaluation can be communicated regarding pathology that was not visible in the image/video clips provided.

Thank you for this referral. If the clinical or image interpretation does not parallel your findings or if I can be of any further assistance please contact me.

Remo Lobetti, BVSc, MMedVet (Med), PhD, Dipl. ECVIM (Internal Medicine)

info@sonopath.com