



## PATIENT

Toby Bylicki

## SPECIES

Feline

## BREED

Domestic Shorthair

## SEX

Neutered male

## AGE

13 years

## WEIGHT

14 lbs

## INTERPRETED BY

Remo Lobetti, BVSc,  
MMedVet (Med),  
PhD, Dipl. ECVIM

## IMAGING PERFORMED BY

Vincent Ravancho, CVT

## HOSPITAL NAME

Marsh Hospital for  
Animals

## REFERRING VET

Dr. Armani

## INVOICE

78389

## DATE

6/4/26

## PRESENTING CLINICAL SIGNS

History: Hyperthyroid and cardiac murmur grade 2. Needs Mast Cell Removal. Current medications - Methimazole 2.5 mg, Gabapentin 50 mg BID

Abnormal PE/Chem/CBC/UA Results: T4 3.2. USG 1.044

## ULTRASONOGRAPHIC EXAMINATION OF THE ABDOMEN

### Urinary System

The urinary bladder is full with a normal thickness and smooth appearance of the wall. A small amount of floating, hyperechogenic sediment is noted.

Normal appearance of the trigone area, proximal urethra, and iliac blood vessels.

Normal appearance and size of the iliac lymph nodes. Ureters not visualized, which can be considered a normal finding.

Normal renal size (left measured 4.8 cm, right measured 4.5 cm), architecture, echogenic appearance, cortico-medullary differentiation, which maintains a 1:3 cortex to medulla ratio, pelvis, and capsule. No infarcts, mineralization or renoliths evident. Normal color flow pattern is evident in both kidneys.

### Adrenal Glands

Normal shape, echogenic appearance, size, position, and appearance of the visible peri-adrenal vasculature. Left adrenal gland measured 0.52 cm in width. The right adrenal gland measured 0.62 cm in width.

### Spleen

Normal size and echogenic appearance. Smooth homogenous parenchyma and regular curvilinear capsule. Normal volume of the splenic vasculature without any overt congestion or thrombosis evident. No inflammatory, neoplastic, infarction, or infiltrative changes evident. The spleen measured 0.7 cm in width.

### Liver

Normal size, echogenic appearance, portal markings, and regular curvilinear capsule. No nodules or masses evident. Normal appearance of the hepatic and portal vasculature.

### Gallbladder

The gallbladder is small containing normal anechoic bile. Normal thickness and echogenic appearance of the wall. Normal size and appearance of the cystic and common bile duct.



## PATIENT

Toby Bylicki

## SPECIES

Feline

## BREED

Domestic Shorthair

## SEX

Neutered male

## AGE

13 years

## WEIGHT

14 lbs

## INTERPRETED BY

Remo Lobetti, BVSc,  
MMedVet (Med),  
PhD, Dipl. ECVIM

## IMAGING PERFORMED BY

Vincent Ravancho, CVT

## HOSPITAL NAME

Marsh Hospital for  
Animals

## REFERRING VET

Dr. Armani

## INVOICE

78389

## DATE

6/4/26

## Gastrointestinal

Normal appearance of the stomach, duodenum, small intestine, ileo-cecal junction, and colon with no loss of layering, 1:3 muscularis to mucosa ratio, normal wall thickness and peristaltic activity, and no distension of the lumen.

## Pancreas

The visible sections of the pancreas are of normal size and echogenic appearance with a regular capsule. Normal echogenic appearance of the mesentery and fat surrounding the pancreas.

## Free Abdomen

Normal mesenteric lymph nodes.

No ascites evident.

## ULTRASONOGRAPHIC FINDINGS

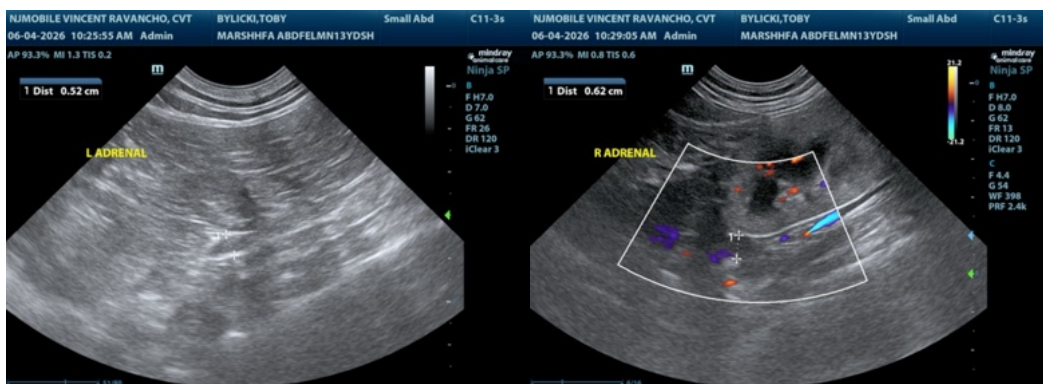
- Urinary bladder sediment.

## INTERPRETATION OF THE FINDINGS & FURTHER RECOMMENDATIONS

The most likely etiology for the urinary bladder sediment would be incidental debris with crystalluria and bacterial cystitis a less likely differential diagnosis.

On this ultrasound there is no obvious evidence of metastatic mast cell neoplasia.

Further assessment that can be considered would urinalysis and possibly urine culture.





**PATIENT**

Toby Bylicki

**SPECIES**

Feline

**BREED**

Domestic Shorthair

**SEX**

Neutered male

**AGE**

13 years

**WEIGHT**

14 lbs

**INTERPRETED BY**

Remo Lobetti, BVSc,  
MMedVet (Med),  
PhD, Dipl. ECVIM

**IMAGING PERFORMED BY**

Vincent Ravancho, CVT

**HOSPITAL NAME**

Marsh Hospital for  
Animals

**REFERRING VET**

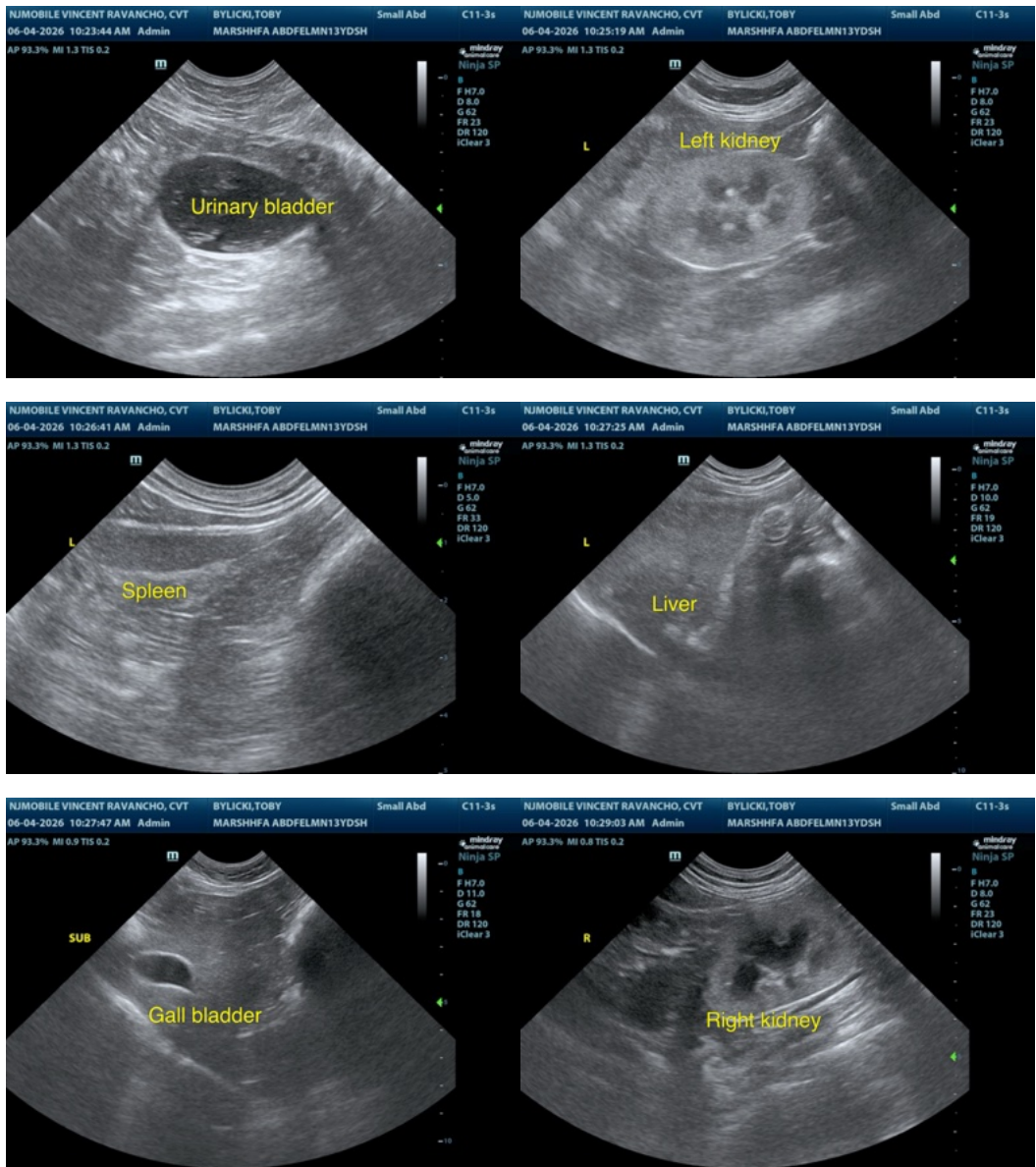
Dr. Armani

**INVOICE**

78389

**DATE**

6/4/26



The information and recommendations provided are based on the images presented by the referring veterinarian/sonographer. No evaluation can be communicated regarding pathology that was not visible in the image/video clips provided.

Thank you for this referral. If the clinical or image interpretation does not parallel your findings or if I can be of any further assistance please contact me.

Remo Lobetti, BVSc, MMedVet (Med), PhD, Dipl. ECVIM (Internal Medicine)

[info@sonopath.com](mailto:info@sonopath.com)