



PATIENT

Remy Vandermark

SPECIES

Canine

BREED

Mix

SEX

Neutered male

AGE

8 ½ years

WEIGHT

69 lbs

INTERPRETED BY

Remo Lobetti, BVSc,
MMedVet (Med),
PhD, Dipl. ECVIM

IMAGING PERFORMED BY

Rebecca Hamilton

HOSPITAL NAME

Hamptonburgh AH

REFERRING VET

Dr. Rogers

INVOICE

75251

DATE

5/6/26

PRESENTING CLINICAL SIGNS

History: Possible suspected Splenic mass w/ regenerative anemia- R/O Hemangiosarcoma, splenic hematoma, Benign splenic mass. Meds: Doxycycline, Telmisartan, Yunnan Baiyao

ULTRASONOGRAPHIC EXAMINATION OF THE ABDOMEN

Urinary System

The urinary bladder is small with a normal thickness and smooth appearance of the wall. Normal anechoic urine with no sediment or uroliths evident.

Normal appearance of the trigone area, proximal urethra, and iliac blood vessels.

Normal appearance and size of the iliac lymph nodes. Ureters not visualized, which can be considered a normal finding.

Normal renal size (left measured 7.5 cm, right measured 7.2 cm), architecture, echogenic appearance, cortico-medullary differentiation, which maintains a 1:3 cortex to medulla ratio, pelvis, and capsule. No infarcts, mineralization or renoliths evident.

The prostate is small and hypoechogenic measuring 1.2 cm in width.

Adrenal Glands

Normal shape, echogenic appearance, size, position, and appearance of the visible peri-adrenal vasculature. Left adrenal gland measured 3.17 cm in length x 0.57 cm and 0.56 cm in width. The right adrenal gland measured 2.96 cm in length x 0.49 cm and 0.57 cm in width.

Spleen

The spleen revealed a large, irregular, mottled echogenic, poorly vascularized mass that originated off the head of the spleen measuring at least 8 x 9 cm. The rest of the spleen is of normal size (1.4 cm in width) maintaining a normal echogenic appearance, smooth homogenous parenchyma and a regular curvilinear capsule. Normal volume of the splenic vasculature without any overt congestion or thrombosis evident.

Liver

Normal size, echogenic appearance, portal markings, and regular curvilinear capsule. No nodules or masses evident. Normal appearance of the hepatic and portal vasculature.



PATIENT

Remy Vandermark

SPECIES

Canine

BREED

Mix

SEX

Neutered male

AGE

8 ½ years

WEIGHT

69 lbs

INTERPRETED BY

Remo Lobetti, BVSc,
MMedVet (Med),
PhD, Dipl. ECVIM

IMAGING PERFORMED BY

Rebecca Hamilton

HOSPITAL NAME

Hamptonburgh AH

REFERRING VET

Dr. Rogers

INVOICE

75251

DATE

5/6/26

Gallbladder

The gallbladder is small containing normal anechoic bile. Normal thickness and echogenic appearance of the wall. Normal size and appearance of the cystic and common bile duct.

Gastrointestinal

Normal appearance of the stomach, duodenum, small intestine, ileo-cecal junction, and colon with no loss of layering, 1:3 muscularis to mucosa ratio, normal wall thickness and peristaltic activity, and no distension of the lumen.

Pancreas

The pancreas is not visualized.

Free Abdomen

Normal mesenteric lymph nodes.

No ascites evident.

Thorax

Normal appearance of the heart. No pericardial or pleural effusion evident.

ULTRASONOGRAPHIC FINDINGS

- Splenic mass

INTERPRETATION OF THE FINDINGS & FURTHER RECOMMENDATIONS

The most likely etiology for the splenic mass would be neoplasia with hematoma and granuloma a less likely differential diagnosis.

Further assessment would be three view thoracic radiographs, splenectomy should be considered as it could be both diagnostic and therapeutic with further specific therapy dependent on an etiological diagnosis.



PATIENT

Remy Vandermark

SPECIES

Canine

BREED

Mix

SEX

Neutered male

AGE

8 ½ years

WEIGHT

69 lbs

INTERPRETED BY

Remo Lobetti, BVSc,
 MMedVet (Med),
 PhD, Dipl. ECVIM

IMAGING PERFORMED BY

Rebecca Hamilton

HOSPITAL NAME

Hamptonburgh AH

REFERRING VET

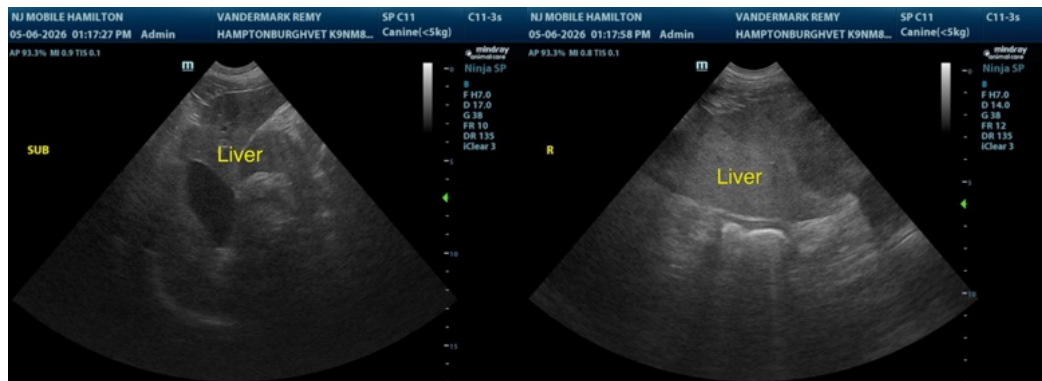
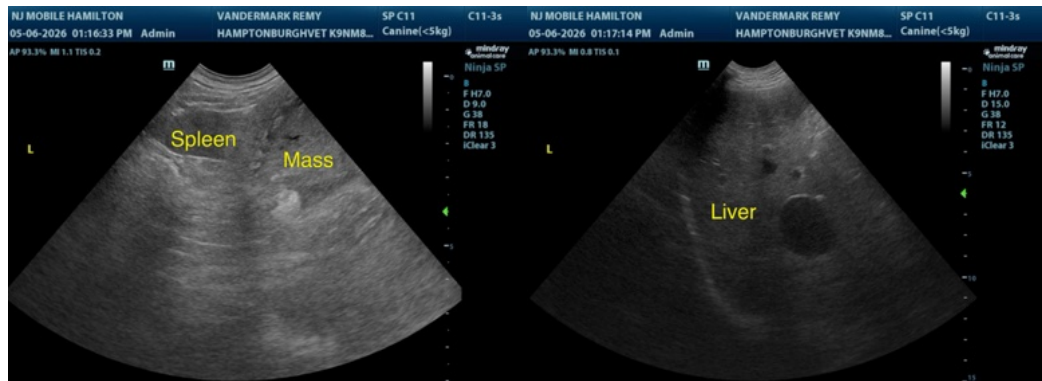
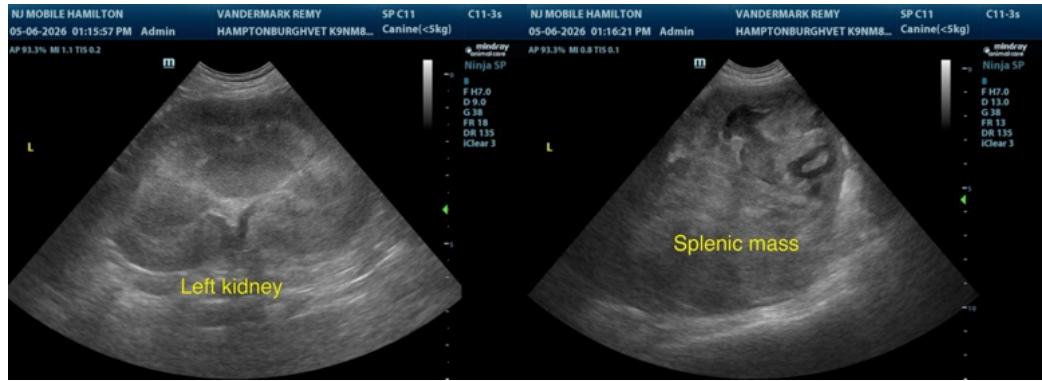
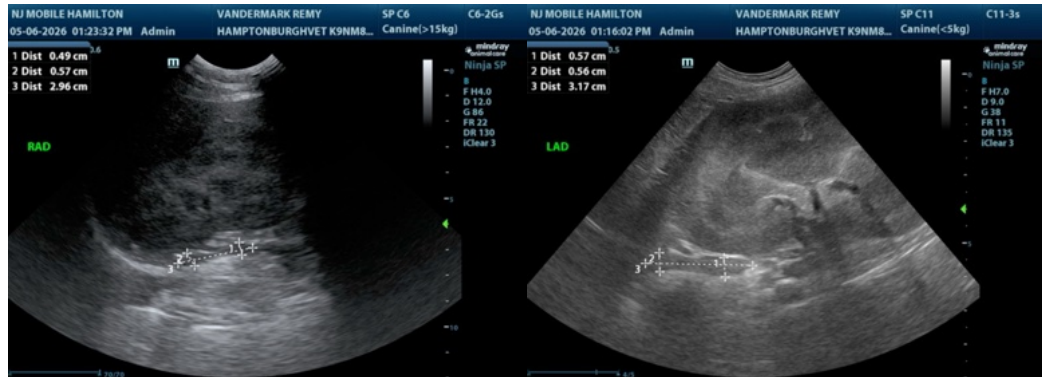
Dr. Rogers

INVOICE

75251

DATE

5/6/26





PATIENT

Remy Vandermark

SPECIES

Canine

BREED

Mix

SEX

Neutered male

AGE

8 ½ years

WEIGHT

69 lbs

INTERPRETED BY

Remo Lobetti, BVSc, MMedVet (Med), PhD, Dipl. ECVIM

IMAGING PERFORMED BY

Rebecca Hamilton

HOSPITAL NAME

Hamptonburgh AH

REFERRING VET

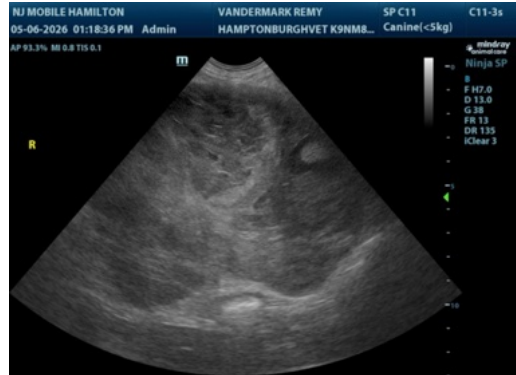Dr. Rogers

INVOICE

75251

DATE

5/6/26



The information and recommendations provided are based on the images presented by the referring veterinarian/sonographer. No evaluation can be communicated regarding pathology that was not visible in the image/video clips provided.

Thank you for this referral. If the clinical or image interpretation does not parallel your findings or if I can be of any further assistance please contact me.

Remo Lobetti, BVSc, MMedVet (Med), PhD, Dipl. ECVIM (Internal Medicine)

info@sonopath.com