



PATIENT

Mia Martusewicz

SPECIES

Canine

BREED

Mix

SEX

Spayed female

AGE

10 years

WEIGHT

38.9 lbs

INTERPRETED BY

Remo Lobetti, BVSc,
MMedVet (Med),
PhD, Dipl. ECVIM

IMAGING PERFORMED BY

Rebecca Hamilton

HOSPITAL NAME

Animal Hospital
Sullivan County NY

REFERRING VET

Dr. Boblusky

INVOICE

75252

DATE

5/6/26

PRESENTING CLINICAL SIGNS

History: Urinary issues, hematuria for 30 days. Urine crystals and bacteria

ULTRASONOGRAPHIC EXAMINATION OF THE ABDOMEN

Urinary System

The urinary bladder is full with normal thickness and smooth appearance of the wall. A small amount of floating, hyperechogenic sediment.

Normal appearance of the trigone area, proximal urethra, and iliac blood vessels.

Normal appearance and size of the iliac lymph nodes. Ureters not visualized, which can be considered a normal finding.

Normal renal size (left measured 5.5 cm, right measured 6.0 cm), architecture, echogenic appearance, cortico-medullary differentiation, which maintains a 1:3 cortex to medulla ratio, pelvis, and capsule. No infarcts, mineralization or renoliths evident. Normal color flow pattern is evident in both kidneys.

Adrenal Glands

Normal shape, echogenic appearance, size, position, and appearance of the visible peri-adrenal vasculature. Left adrenal gland measured 2.16 cm in length x 0.44 cm and 0.38 cm in width. The right adrenal gland measured 2.03 cm in length x 0.42 cm and 0.63 cm in width.

Spleen

Normal size and echogenic appearance. Smooth homogenous parenchyma and regular curvilinear capsule. Normal volume of the splenic vasculature without any overt congestion or thrombosis evident. No inflammatory, neoplastic, infarction, or infiltrative changes evident. The spleen measured 1.5 cm in width.

Liver

Normal size, echogenic appearance, portal markings, and regular curvilinear capsule. No nodules or masses evident. Normal appearance of the hepatic and portal vasculature.

Gallbladder

The gallbladder is full containing normal anechoic bile. Normal thickness and echogenic appearance of the wall. Normal size and appearance of the cystic and common bile duct.



PATIENT

Mia Martusewicz

SPECIES

Canine

BREED

Mix

SEX

Spayed female

AGE

10 years

WEIGHT

38.9 lbs

INTERPRETED BY

Remo Lobetti, BVSc,
MMedVet (Med),
PhD, Dipl. ECVIM

IMAGING PERFORMED BY

Rebecca Hamilton

HOSPITAL NAME

Animal Hospital
Sullivan County NY

REFERRING VET

Dr. Boblusky

INVOICE

75252

DATE

5/6/26

Gastrointestinal

Normal appearance of the stomach, duodenum, small intestine, ileo-cecal junction, and colon with no loss of layering, 1:3 muscularis to mucosa ratio, normal wall thickness and peristaltic activity, and no distension of the lumen. A small amount of ingesta is present in the stomach compatible with a recent meal.

Pancreas

The visible sections of the pancreas are of normal size and echogenic appearance with a regular capsule. Normal echogenic appearance of the mesentery and fat surrounding the pancreas.

Free Abdomen

Normal mesenteric lymph nodes.
No ascites evident.

ULTRASONOGRAPHIC FINDINGS

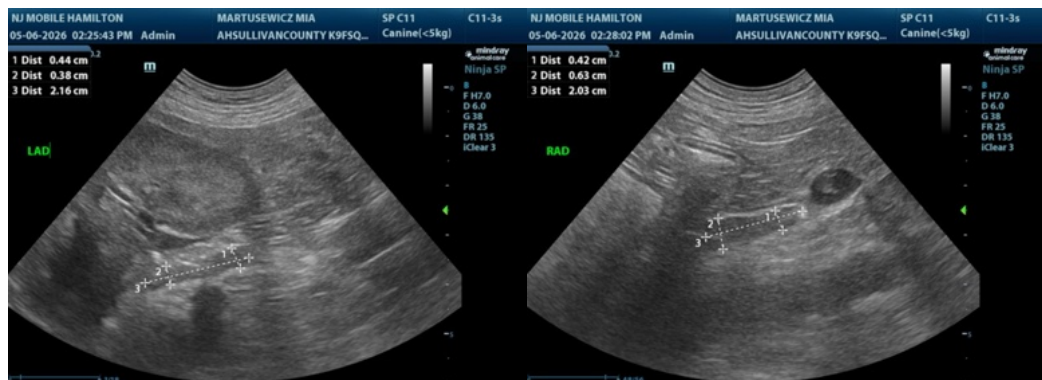
- Urinary bladder sediment.

INTERPRETATION OF THE FINDINGS & FURTHER RECOMMENDATIONS

The most likely etiology for the urinary bladder sediment would be hematuria and bacterial cystitis.

Further assessment would be urine culture.

Specific therapy would be dependent on an etiological diagnosis.





PATIENT

Mia Martusewicz

SPECIES

Canine

BREED

Mix

SEX

Spayed female

AGE

10 years

WEIGHT

38.9 lbs

INTERPRETED BY

Remo Lobetti, BVSc,
 MMedVet (Med),
 PhD, Dipl. ECVIM

IMAGING PERFORMED BY

Rebecca Hamilton

HOSPITAL NAME

Animal Hospital
 Sullivan County NY

REFERRING VET

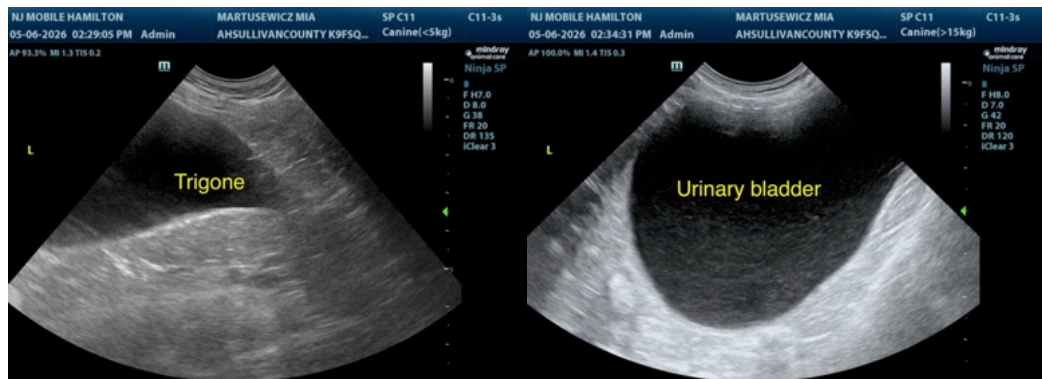
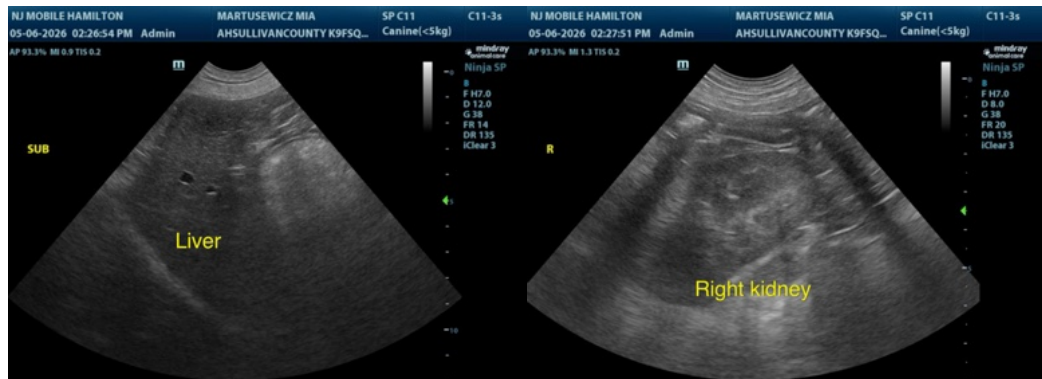
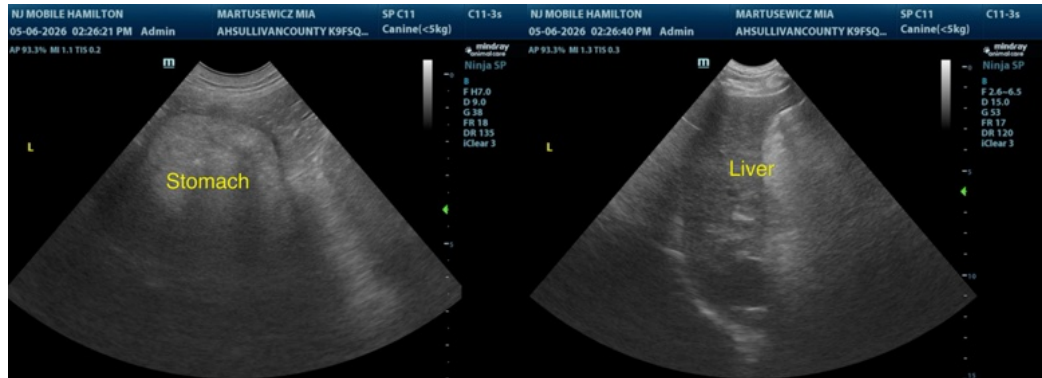
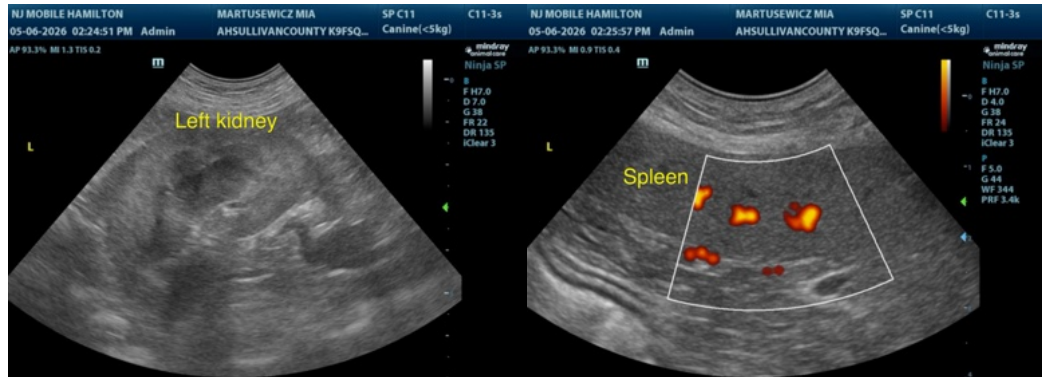
Dr. Boblusky

INVOICE

75252

DATE

5/6/26





PATIENT

Mia Martusewicz

SPECIES

Canine

BREED

Mix

SEX

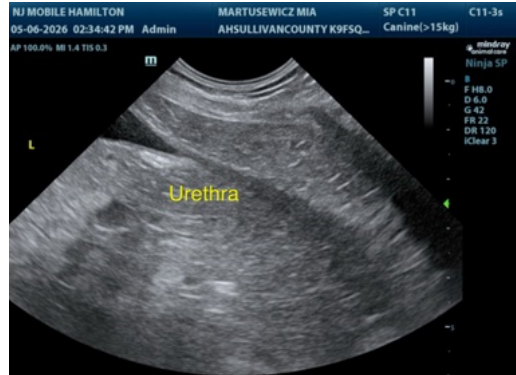Spayed female

AGE

10 years

WEIGHT

38.9 lbs



The information and recommendations provided are based on the images presented by the referring veterinarian/sonographer. No evaluation can be communicated regarding pathology that was not visible in the image/video clips provided.

Thank you for this referral. If the clinical or image interpretation does not parallel your findings or if I can be of any further assistance please contact me.

Remo Lobetti, BVSc, MMedVet (Med), PhD, Dipl. ECVIM (Internal Medicine)

info@sonopath.com

INTERPRETED BY

Remo Lobetti, BVSc,
MMedVet (Med),
PhD, Dipl. ECVIM

IMAGING PERFORMED BY

Rebecca Hamilton

HOSPITAL NAME

Animal Hospital
Sullivan County NY

REFERRING VET

Dr. Boblusky

INVOICE

75252

DATE

5/6/26