



PATIENT PRESENTING CLINICAL SIGNS

Zelda Real Dog Rescue

SPECIES

Canine

BREED

German Shepherd

SEX

Female

AGE

7 years

WEIGHT

48.7 lbs

INTERPRETED BY

Remo Lobetti, BVSc,
MMedVet (Med),
PhD, Dipl. ECVIM

IMAGING PERFORMED BY

Kerri Becker

HOSPITAL NAME

Bergen County VC

REFERRING VET

Dr. Shiffman

INVOICE

75196

DATE

5/5/26

History: Rescued stray from Louisiana, hospitalized for aspiration pneumonia PCR Coronavirus. Cachexia, mild hind end ataxia, discharged 5/2 on antibiotics. Rads 4/28 showed R lung lobe alveolar pattern, esoph gas dilation, focal dorsal convex bulge at splenic tail/body. Meds-metoclopramide, amox/clav, baytril, zofran, ursodiol (started 5/4)
Abnormal PE/Chem/CBC/UA Results: ALT-771 alp-1,848 GGT-32 HCT-30 WBC-normal

ULTRASONOGRAPHIC EXAMINATION OF THE ABDOMEN

Urinary System

The urinary bladder is full with a normal thickness and smooth appearance of the wall. Normal anechoic urine with no sediment or uroliths evident.

Normal appearance of the trigone area, proximal urethra, and iliac blood vessels.

Normal appearance and size of the iliac lymph nodes. Ureters not visualized, which can be considered a normal finding.

Normal renal size (left measured 6.3 cm, right measured 6.8 cm), architecture, echogenic appearance, cortico-medullary differentiation, which maintains a 1:3 cortex to medulla ratio, pelvis, and capsule. No infarcts, mineralization or renoliths evident. Normal color flow pattern is evident in both kidneys.

Adrenal Glands

Normal shape, echogenic appearance, size, position, and appearance of the visible peri-adrenal vasculature. Left adrenal gland measured 1.65 cm in length x 0.49 cm and 0.5 cm in width. The right adrenal gland measured 1.77 cm in length x 0.91 cm and 0.79 cm in width.

Spleen

Normal size and echogenic appearance. Smooth homogenous parenchyma and regular curvilinear capsule. Normal volume of the splenic vasculature without any overt congestion or thrombosis evident. No inflammatory, neoplastic, infarction, or infiltrative changes evident. The spleen measured 2.5 cm in width.

Liver

Normal size with a diffuse, increased echogenic and coarse appearance, mild increase in portal markings, and regular curvilinear capsule. No nodules or masses evident. Normal appearance of the hepatic and portal vasculature.



PATIENT

Zelda Real Dog Rescue

SPECIES

Canine

BREED

German Shepherd

SEX

Female

AGE

7 years

WEIGHT

48.7 lbs

INTERPRETED BY

Remo Lobetti, BVSc,
MMedVet (Med),
PhD, Dipl. ECVIM

IMAGING PERFORMED BY

Kerri Becker

HOSPITAL NAME

Bergen County VC

REFERRING VET

Dr. Shiffman

INVOICE

75196

DATE

5/5/26

Gallbladder

The gallbladder is full containing normal anechoic bile. Normal thickness and echogenic appearance of the wall. Normal size and appearance of the cystic and common bile duct.

Gastrointestinal

Normal appearance of the stomach, duodenum, small intestine, ileo-cecal junction, and colon with no loss of layering, 1:3 muscularis to mucosa ratio, normal wall thickness and peristaltic activity, and no distension of the lumen.

Pancreas

The visible sections of the pancreas are of normal size and echogenic appearance with a regular capsule. Normal echogenic appearance of the mesentery and fat surrounding the pancreas.

Free Abdomen

Normal mesenteric lymph nodes.

No ascites evident.

ULTRASONOGRAPHIC FINDINGS

- Hepatopathy.

INTERPRETATION OF THE FINDINGS & FURTHER RECOMMENDATIONS

Etiologies for the hepatopathy would be reactive hyperplasia, early nodular hyperplasia, vacuolar and metabolic with cholangiohepatitis a possible differential diagnosis.

Infiltrative neoplasia would be an unlikely differential diagnosis.

Further assessment would be FNA cytology of the liver. However, a tru cut or wedge biopsy may be required for a final etiological diagnosis.

Specific therapy would be dependent on an etiological diagnosis.

Initial symptomatic management of the liver that can be considered would be the use of Ursodiol with regular monitoring of liver enzyme activity.



PATIENT

Zelda Real Dog Rescue

SPECIES

Canine

BREED

German Shepherd

SEX

Female

AGE

7 years

WEIGHT

48.7 lbs

INTERPRETED BY

Remo Lobetti, BVSc,
 MMedVet (Med),
 PhD, Dipl. ECVIM

IMAGING PERFORMED BY

Kerri Becker

HOSPITAL NAME

Bergen County VC

REFERRING VET

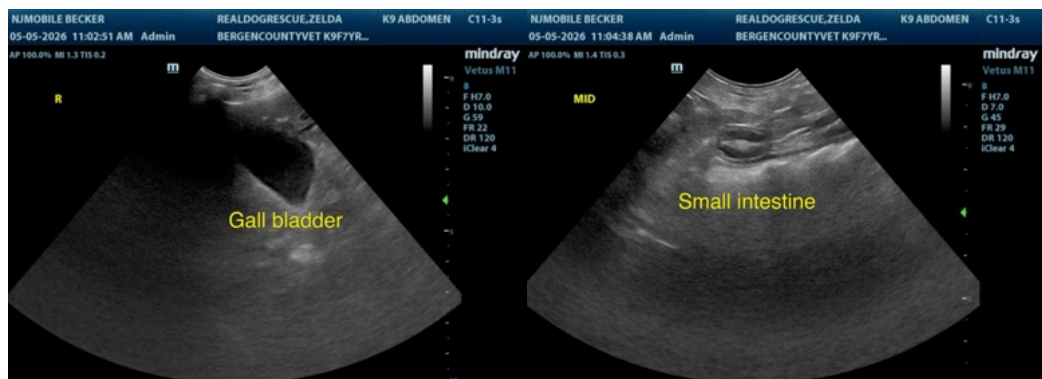
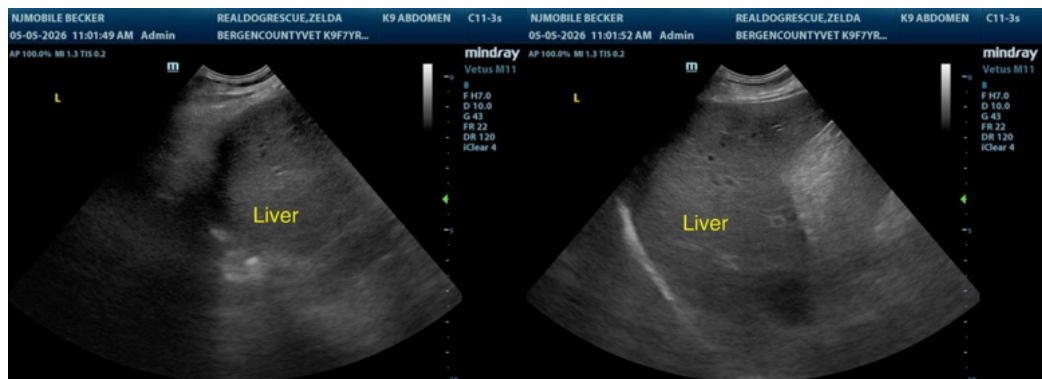
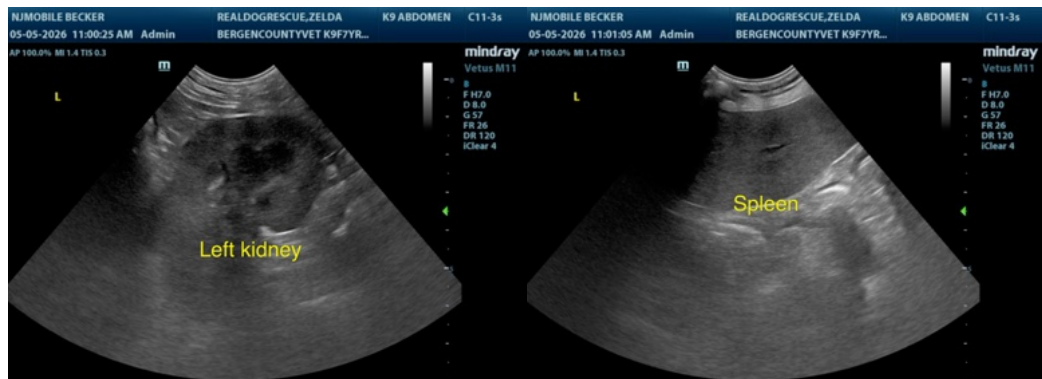
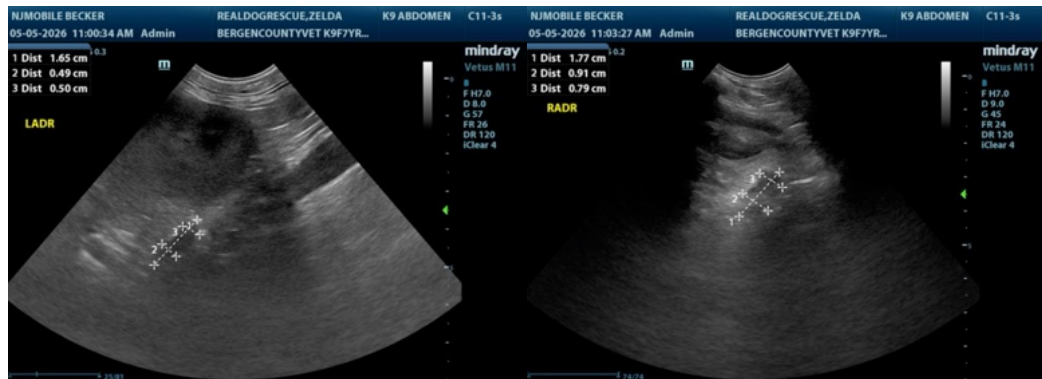Dr. Shiffman

INVOICE

75196

DATE

5/5/26





PATIENT

Zelda Real Dog Rescue

SPECIES

Canine

BREED

German Shepherd

SEX

Female

AGE

7 years

WEIGHT

48.7 lbs

INTERPRETED BY

Remo Lobetti, BVSc,
MMedVet (Med),
PhD, Dipl. ECVIM

IMAGING PERFORMED BY

Kerri Becker

HOSPITAL NAME

Bergen County VC

REFERRING VET

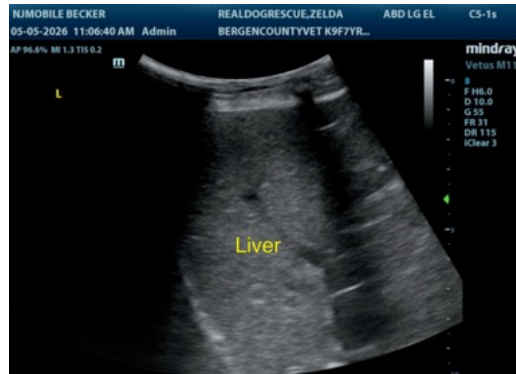Dr. Shiffman

INVOICE

75196

DATE

5/5/26



The information and recommendations provided are based on the images presented by the referring veterinarian/sonographer. No evaluation can be communicated regarding pathology that was not visible in the image/video clips provided.

Thank you for this referral. If the clinical or image interpretation does not parallel your findings or if I can be of any further assistance please contact me.

Remo Lobetti, BVSc, MMedVet (Med), PhD, Dipl. ECVIM (Internal Medicine)

info@sonopath.com