



PATIENT **PRESENTING CLINICAL SIGNS**

Tiramisu Fazzini History: Not eating, vomiting (CKD/pancreatitis) presented dehydrated, nauseous.
Abnormal PE/Chem/CBC/UA Results: azotemia, elev panc lipase and amylase.

SPECIES

Feline

ULTRASONOGRAPHIC EXAMINATION OF THE ABDOMEN

BREED

Urinary System

Siamese

The urinary bladder is full with a normal thickness and smooth appearance of the wall. Normal anechoic urine with no sediment or uroliths evident.

SEX

Normal appearance of the trigone area, proximal urethra, and iliac blood vessels.

Spayed Female

Normal appearance and size of the iliac lymph nodes. Ureters not visualized, which can be considered a normal finding.

AGE

18 years

Normal renal size (left measured 3.0 cm, right measured 3.1 cm), with normal echogenic appearance, loss of cortico-medullary differentiation, mild pyelectasia and an irregular curvilinear capsule. No infarcts, mineralization or renoliths evident. Poor color flow pattern is evident in both kidneys.

WEIGHT

6.84 lbs

Adrenal Glands

INTERPRETED BY

Remo Lobetti, BVSc,
MMedVet (Med),
PhD, Dipl. ECVIM

Normal shape, echogenic appearance, size, position, and appearance of the visible peri-adrenal vasculature. Left adrenal gland measured 0.3 cm in width. The right adrenal gland measured 0.32 cm in width.

IMAGING PERFORMED BY

Kerri Becker

Spleen

Normal size and echogenic appearance. Smooth homogenous parenchyma and regular curvilinear capsule. Normal volume of the splenic vasculature without any overt congestion or thrombosis evident. No inflammatory, neoplastic, infarction, or infiltrative changes evident. The spleen measured 0.8 cm in width.

HOSPITAL NAME

All Creatures Fairfield

REFERRING VET

Dr. Ruiz

Liver

Normal size, echogenic appearance, portal markings, and regular curvilinear capsule. No nodules or masses evident. Normal appearance of the hepatic and portal vasculature.

INVOICE

78116

DATE

5/29/26

Gallbladder

The gallbladder is full containing normal anechoic bile. Normal thickness and echogenic appearance of the wall. Dilated and tortuous appearance of the cystic and common bile ducts with no obvious obstruction evident. The bile duct measured 0.4 cm in diameter.



PATIENT

Tiramisu Fazzini

SPECIES

Feline

BREED

Siamese

SEX

Spayed Female

AGE

18 years

WEIGHT

6.84 lbs

INTERPRETED BY

Remo Lobetti, BVSc,
MMedVet (Med),
PhD, Dipl. ECVIM

IMAGING PERFORMED BY

Kerri Becker

HOSPITAL NAME

All Creatures Fairfield

REFERRING VET

Dr. Ruiz

INVOICE

78116

DATE

5/29/26

Gastrointestinal

Normal appearance of the stomach, duodenum, small intestine, ileo-cecal junction, and colon with no loss of layering, 1:3 muscularis to mucosa ratio, normal wall thickness and peristaltic activity, and no distension of the lumen.

Pancreas

Normal size with a hypoechogenic appearance and an irregular capsule. Increased echogenic appearance of the mesentery and fat surrounding the pancreas.

Free Abdomen

Normal mesenteric lymph nodes.

No ascites evident.

ULTRASONOGRAPHIC FINDINGS

- Renal disease.
- Pancreatitis.

INTERPRETATION OF THE FINDINGS & FURTHER RECOMMENDATIONS

The appearance of the kidneys is consistent with chronic kidney disease.

The dilated and tortuous bile duct can be considered an incidental age related findings.

Further assessment of the renal disease (if not already done) would be urinalysis, UPC, and blood pressure.

Initial management would be fluid therapy, correction of any electrolyte anomalies, antiemetics, opioid analgesics and feeding small frequent meals of an intestinal type diet.

Long term management would be feeding a renal diet, enteric phosphate binders as needed, and either an ace inhibitor or receptor blocker.



PATIENT

Tiramisu Fazzini

SPECIES

Feline

BREED

Siamese

SEX

Spayed Female

AGE

18 years

WEIGHT

6.84 lbs

INTERPRETED BY

Remo Lobetti, BVSc,
 MMedVet (Med),
 PhD, Dipl. ECVIM

IMAGING PERFORMED BY

Kerri Becker

HOSPITAL NAME

All Creatures Fairfield

REFERRING VET

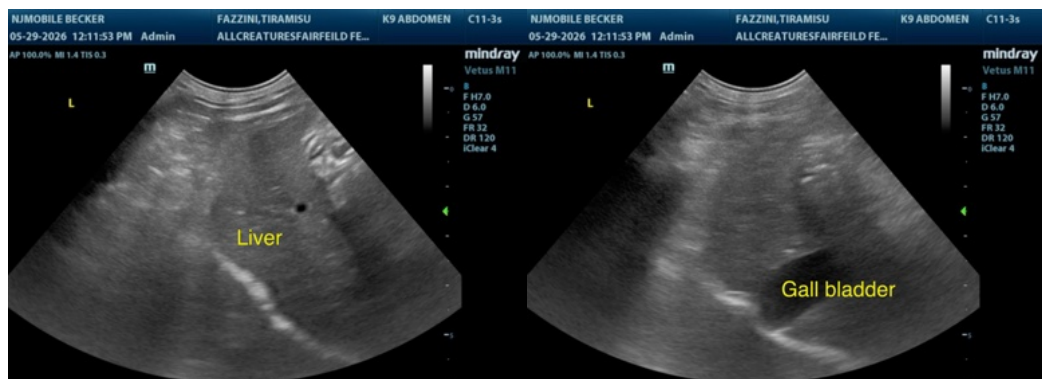
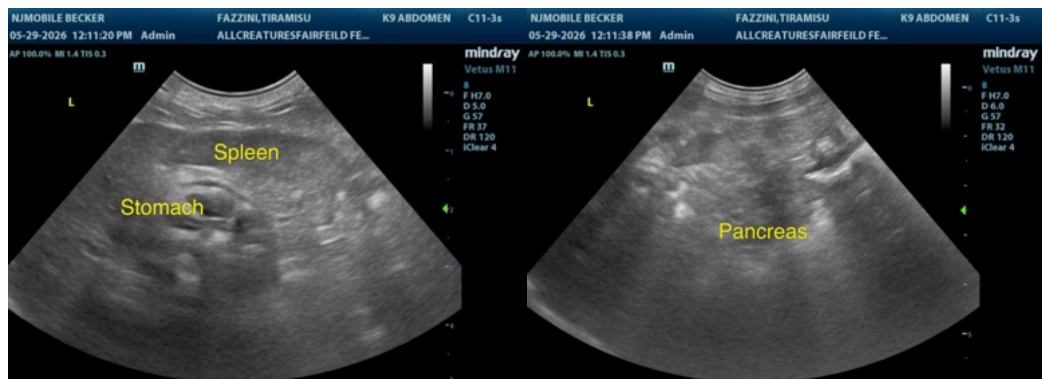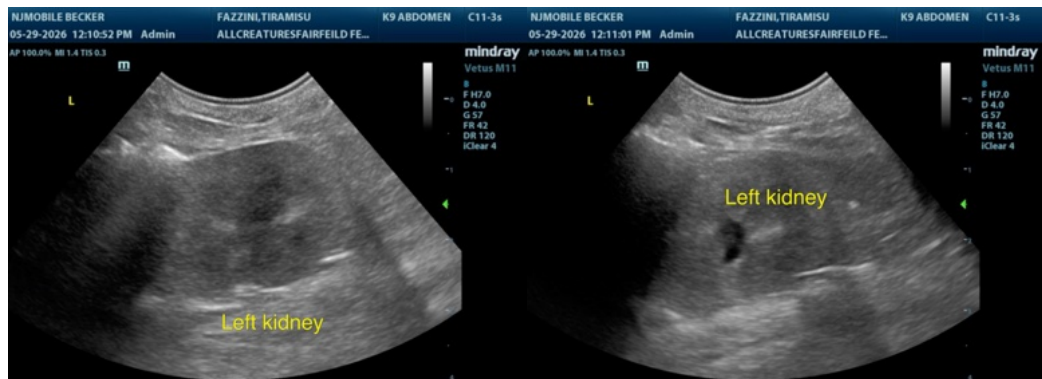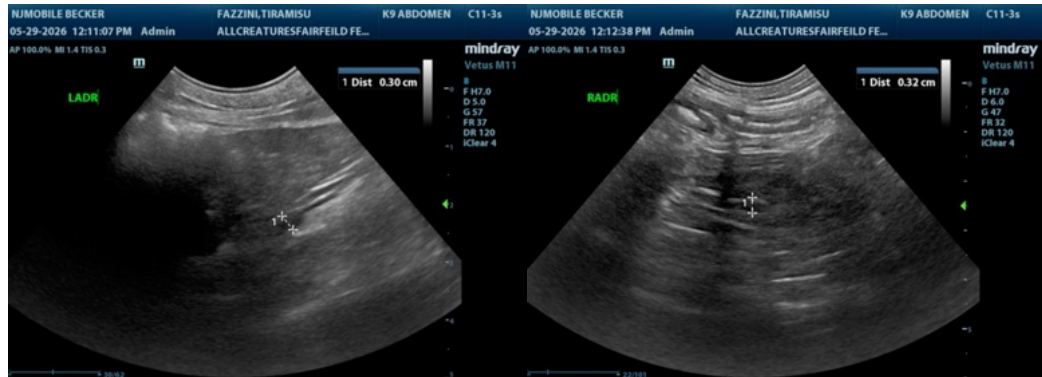
Dr. Ruiz

INVOICE

78116

DATE

5/29/26





PATIENT

Tiramisu Fazzini

SPECIES

Feline

BREED

Siamese

SEX

Spayed Female

AGE

18 years

WEIGHT

6.84 lbs

INTERPRETED BY

Remo Lobetti, BVSc,
 MMedVet (Med),
 PhD, Dipl. ECVIM

IMAGING PERFORMED BY

Kerri Becker

HOSPITAL NAME

All Creatures Fairfield

REFERRING VET

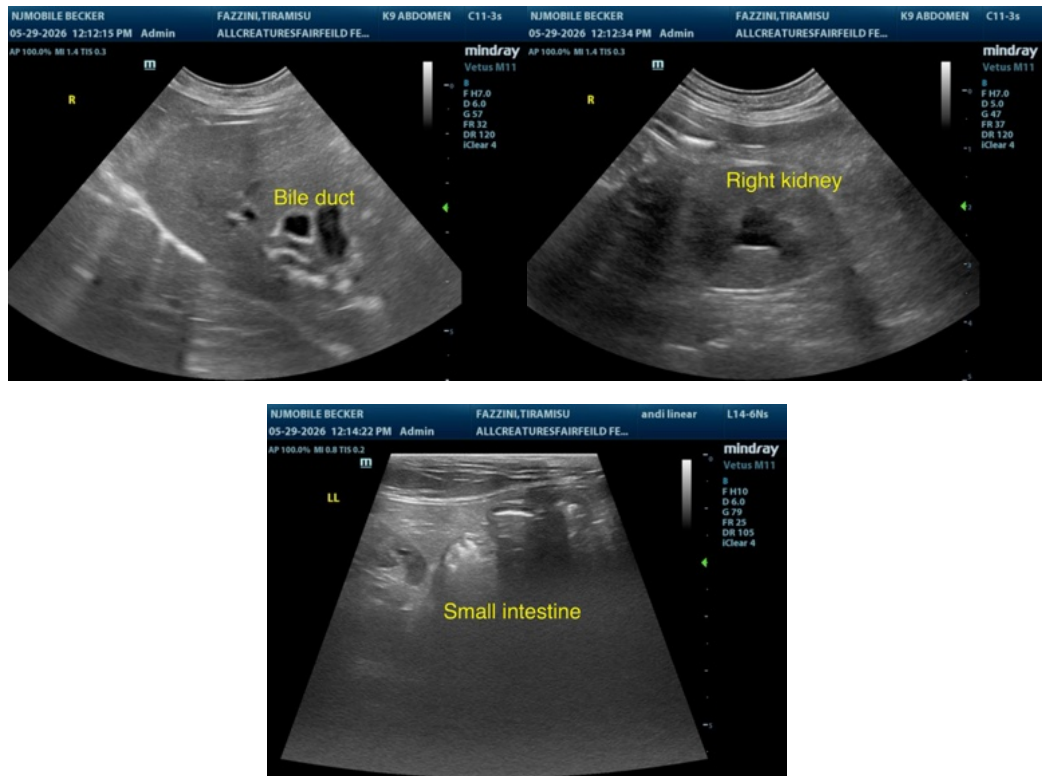Dr. Ruiz

INVOICE

78116

DATE

5/29/26



The information and recommendations provided are based on the images presented by the referring veterinarian/sonographer. No evaluation can be communicated regarding pathology that was not visible in the image/video clips provided.

Thank you for this referral. If the clinical or image interpretation does not parallel your findings or if I can be of any further assistance please contact me.

Remo Lobetti, BVSc, MMedVet (Med), PhD, Dipl. ECVIM (Internal Medicine)

info@sonopath.com