



PATIENT **PRESENTING CLINICAL SIGNS**

Missychamp History: Elev liver values, Dog BAR, exam NSF, may be drinking a little more water?
Sendgikoski Abnormal PE/Chem/CBC/UA Results: AST-98 ALT-497 HCT-61

SPECIES

Canine

ULTRASONOGRAPHIC EXAMINATION OF THE ABDOMEN

BREED

Urinary System

Mix The urinary bladder is small with a normal thickness and smooth appearance of the wall. Normal anechoic urine with no sediment or uroliths evident.

SEX

Normal appearance of the trigone area, proximal urethra, and iliac blood vessels.

Spayed female

Normal appearance and size of the iliac lymph nodes. Ureters not visualized, which can be considered a normal finding.

AGE

8 years

Normal renal size (left measured 7.0 cm, right measured 6.7 cm), architecture, echogenic appearance, cortico-medullary differentiation, which maintains a 1:3 cortex to medulla ratio, pelvis, and capsule. No infarcts, mineralization or renoliths evident. Normal color flow pattern is evident in both kidneys.

WEIGHT

50 lbs

Adrenal Glands

INTERPRETED BY

Remo Lobetti, BVSc,
MMedVet (Med),
PhD, Dipl. ECVIM

Normal shape, echogenic appearance, size, position, and appearance of the visible peri-adrenal vasculature. Left adrenal gland measured 2.69 cm in length x 0.6 cm and 0.63 cm in width. The right adrenal gland measured 2.73 cm x 0.69 cm in width.

IMAGING PERFORMED BY

Kerri Becker

Spleen

Normal size and echogenic appearance. Smooth homogenous parenchyma and regular curvilinear capsule. Normal volume of the splenic vasculature without any overt congestion or thrombosis evident. No inflammatory, neoplastic, infarction, or infiltrative changes evident. The spleen measured 2.3 cm in width.

HOSPITAL NAME

Branchville Country
VC

REFERRING VET

Dr. Valerio

Liver

Normal size, echogenic appearance, portal markings, and regular curvilinear capsule. No nodules or masses evident. Normal appearance of the hepatic and portal vasculature.

INVOICE

77838

Gallbladder

DATE

5/21/26

The gallbladder is full containing normal anechoic bile. Normal thickness and echogenic appearance of the wall. Normal size and appearance of the cystic and common bile duct.



PATIENT

Missychamp
Sendgikoski

SPECIES

Canine

BREED

Mix

SEX

Spayed female

AGE

8 years

WEIGHT

50 lbs

INTERPRETED BY

Remo Lobetti, BVSc,
MMedVet (Med),
PhD, Dipl. ECVIM

**IMAGING
PERFORMED BY**

Kerri Becker

HOSPITAL NAME

Branchville Country
VC

REFERRING VET

Dr. Valerio

INVOICE

77838

DATE

5/21/26

Gastrointestinal

Normal appearance of the stomach, duodenum, small intestine, ileo-cecal junction, and colon with no loss of layering, 1:3 muscularis to mucosa ratio, normal wall thickness and peristaltic activity, and no distension of the lumen.

Pancreas

The visible sections of the pancreas are of normal size and echogenic appearance with a regular capsule. Normal echogenic appearance of the mesentery and fat surrounding the pancreas.

Free Abdomen

Normal mesenteric lymph nodes.

No ascites evident.

ULTRASONOGRAPHIC FINDINGS

- Normal ultrasound examination of the abdomen.

INTERPRETATION OF THE FINDINGS & FURTHER RECOMMENDATIONS

On this ultrasound there is no obvious etiology for the elevated liver enzyme activity.

Although the liver appears ultrasonographically normal, with the elevated ALT activity, an underlying hepatopathy such as reactive hyperplasia, vacuolar and metabolic should still be considered.

Hepatitis and infiltrative neoplasia would be highly unlikely differential diagnosis.

Further assessment would be FNA cytology of the liver; however, a tru cut or wedge biopsy may be required for a final etiological diagnosis.

Specific therapy would be dependent on an etiological diagnosis.

Symptomatic management that can be considered would be the use of Ursodiol with regular monitoring of liver enzyme activity.



PATIENT

Missychamp
 Sendgikoski

SPECIES

Canine

BREED

Mix

SEX

Spayed female

AGE

8 years

WEIGHT

50 lbs

INTERPRETED BY

Remo Lobetti, BVSc,
 MMedVet (Med),
 PhD, Dipl. ECVIM

IMAGING PERFORMED BY

Kerri Becker

HOSPITAL NAME

Branchville Country
 VC

REFERRING VET

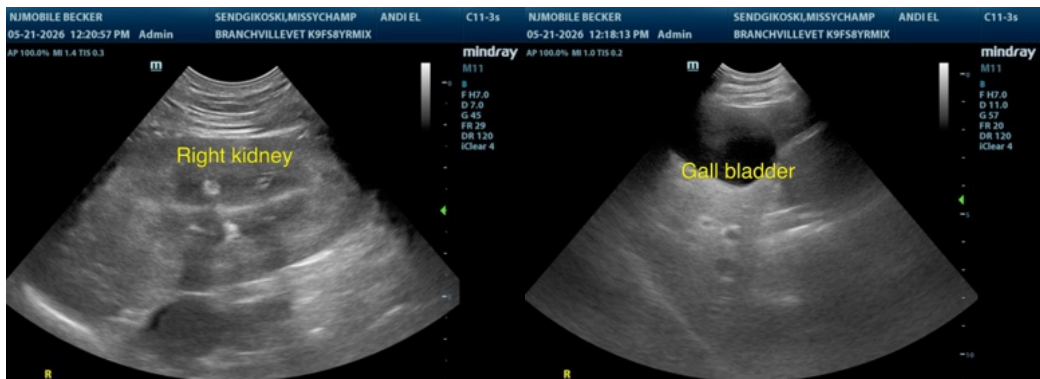
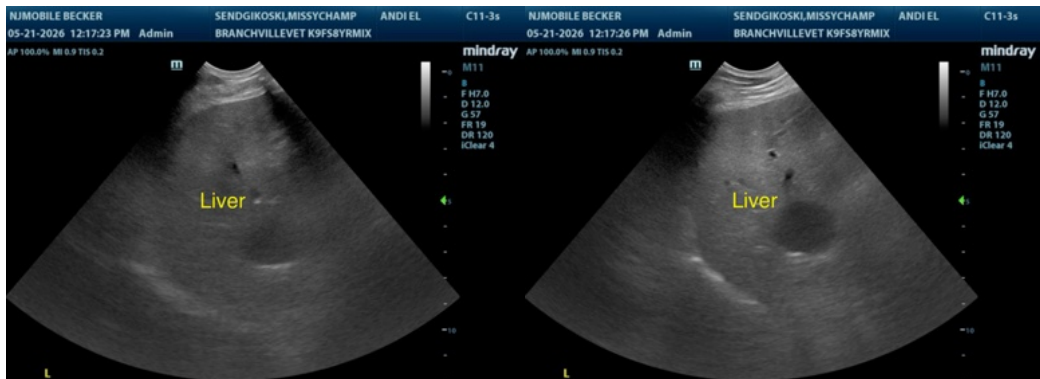
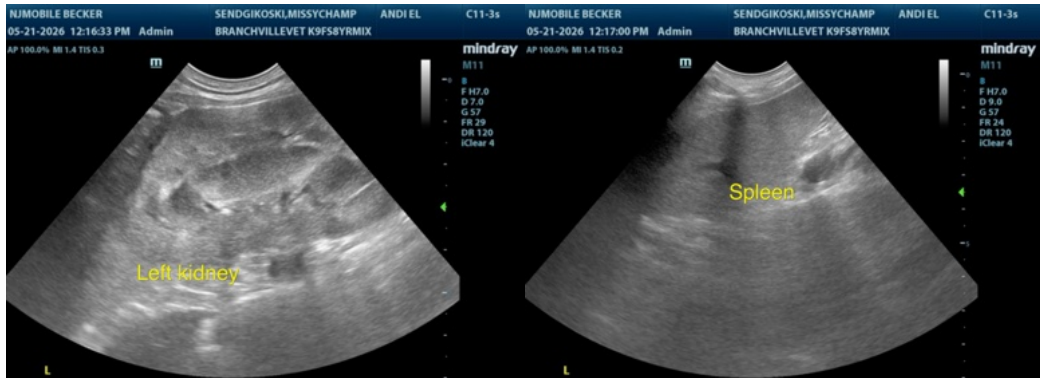
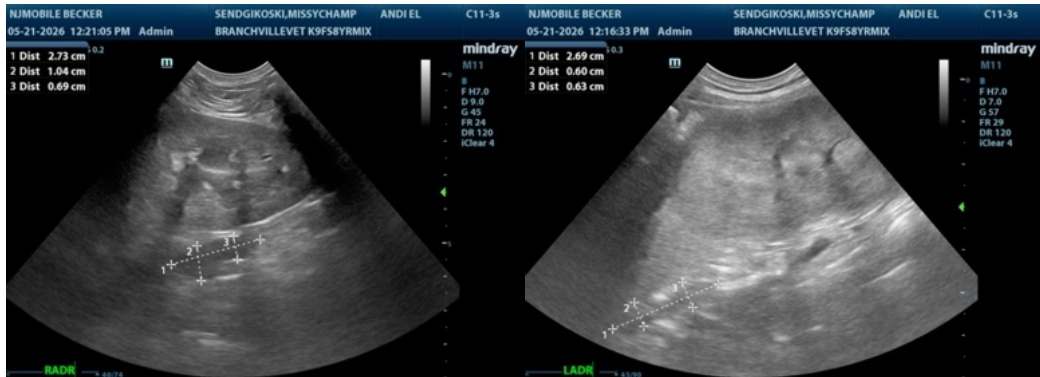
Dr. Valerio

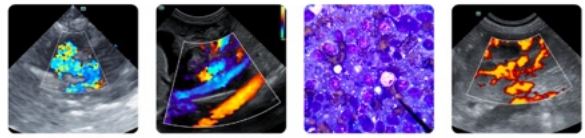
INVOICE

77838

DATE

5/21/26





PATIENT

Missychamp
Sendgikoski

SPECIES

Canine

BREED

Mix

SEX

Spayed female

AGE

8 years

WEIGHT

50 lbs

INTERPRETED BY

Remo Lobetti, BVSc,
MMedVet (Med),
PhD, Dipl. ECVIM

**IMAGING
PERFORMED BY**

Kerri Becker

HOSPITAL NAME

Branchville Country
VC

REFERRING VET

Dr. Valerio

INVOICE

77838

DATE

5/21/26

The information and recommendations provided are based on the images presented by the referring veterinarian/sonographer. No evaluation can be communicated regarding pathology that was not visible in the image/video clips provided.

Thank you for this referral. If the clinical or image interpretation does not parallel your findings or if I can be of any further assistance please contact me.

Remo Lobetti, BVSc, MMedVet (Med), PhD, Dipl. ECVIM (Internal Medicine)

info@sonopath.com