



**PATIENT**

Bella Diss

**SPECIES**

Canine

**BREED**

Bernese Mountain Dog

**SEX**

Spayed female

**AGE**

Not provided

**WEIGHT**

117 lbs

**INTERPRETED BY**

Remo Lobetti, BVSc,  
MMedVet (Med),  
PhD, Dipl. ECVIM

**IMAGING PERFORMED BY**

Rebecca Hamilton

**HOSPITAL NAME**

HoHoKus VH

**REFERRING VET**

Dr. Gannon

**INVOICE**

77874

**DATE**

5/21/26

**PRESENTING CLINICAL SIGNS**

History: Slowly increasing liver values- dog is asymptomatic

Meds: Denamarin- not tried yet

Abnormal PE/Chem/CBC/UA Results: ALY 286 ( Feb 2036 250) ALP 187 USG 1.054

**ULTRASONOGRAPHIC EXAMINATION OF THE ABDOMEN**

**Urinary System**

The urinary bladder is small with a normal thickness and smooth appearance of the wall. Normal anechoic urine with no sediment or uroliths evident.

Normal appearance of the trigone area, proximal urethra, and iliac blood vessels.

Normal appearance and size of the iliac lymph nodes. Ureters not visualized, which can be considered a normal finding.

Normal renal size (left measured 6.7 cm, right measured 7.1 cm), architecture, echogenic appearance, cortico-medullary differentiation, which maintains a 1:3 cortex to medulla ratio, pelvis, and capsule. No infarcts, mineralization or renoliths evident.

**Adrenal Glands**

Normal shape, echogenic appearance, size, position, and appearance of the visible peri-adrenal vasculature. Left adrenal gland measured 2.69 cm in length x 0.51 cm and 0.5 cm in width. The right adrenal gland measured 2.27 cm in length x 0.62 cm in width.

**Spleen**

Normal size and echogenic appearance. Smooth homogenous parenchyma and regular curvilinear capsule. Normal volume of the splenic vasculature without any overt congestion or thrombosis evident. No inflammatory, neoplastic, infarction, or infiltrative changes evident. The spleen measured 1.8 cm in width.

**Liver**

Normal size, echogenic appearance, portal markings, and regular curvilinear capsule. No nodules or masses evident. Normal appearance of the hepatic and portal vasculature.

**Gallbladder**

The gallbladder is small containing normal anechoic bile. Normal thickness and echogenic appearance of the wall. Normal size and appearance of the cystic and common bile duct.



**PATIENT**

Bella Diss

**SPECIES**

Canine

**BREED**

Bernese Mountain Dog

**SEX**

Spayed female

**AGE**

Not provided

**WEIGHT**

117 lbs

**INTERPRETED BY**

Remo Lobetti, BVSc,  
MMedVet (Med),  
PhD, Dipl. ECVIM

**IMAGING PERFORMED BY**

Rebecca Hamilton

**HOSPITAL NAME**

HoHoKus VH

**REFERRING VET**

Dr. Gannon

**INVOICE**

77874

**DATE**

5/21/26

***Gastrointestinal***

Normal appearance of the stomach, duodenum, small intestine, ileo-cecal junction, and colon with no loss of layering, 1:3 muscularis to mucosa ratio, normal wall thickness and peristaltic activity, and no distension of the lumen.

***Pancreas***

The visible sections of the pancreas are of normal size and echogenic appearance with a regular capsule. Normal echogenic appearance of the mesentery and fat surrounding the pancreas.

***Free Abdomen***

Normal mesenteric lymph nodes.

No ascites evident.

**ULTRASONOGRAPHIC FINDINGS**

- Normal ultrasound examination of the abdomen.

**INTERPRETATION OF THE FINDINGS & FURTHER RECOMMENDATIONS**

On this ultrasound there is no obvious etiology for the elevated liver enzyme activity.

Although the liver appears ultrasonographically normal, with the elevated liver enzyme activity and underlying hepatopathy such as reactive hyperplasia, vacuolar and metabolic should still be considered. Hepatitis and infiltrative neoplasia would be highly unlikely differential diagnosis.

Further assessment would be FNA cytology of the liver. However, a tru cut or wedge biopsy may be required for a final etiological diagnosis.

Specific therapy would be dependent on an etiological diagnosis.

Symptomatic management that could be considered would be the use of Ursodiol with regular monitoring of liver enzyme activity.



**PATIENT**

Bella Diss

**SPECIES**

Canine

**BREED**

Bernese Mountain Dog

**SEX**

Spayed female

**AGE**

Not provided

**WEIGHT**

117 lbs

**INTERPRETED BY**

Remo Lobetti, BVSc,  
 MMedVet (Med),  
 PhD, Dipl. ECVIM

**IMAGING PERFORMED BY**

Rebecca Hamilton

**HOSPITAL NAME**

HoHoKus VH

**REFERRING VET**

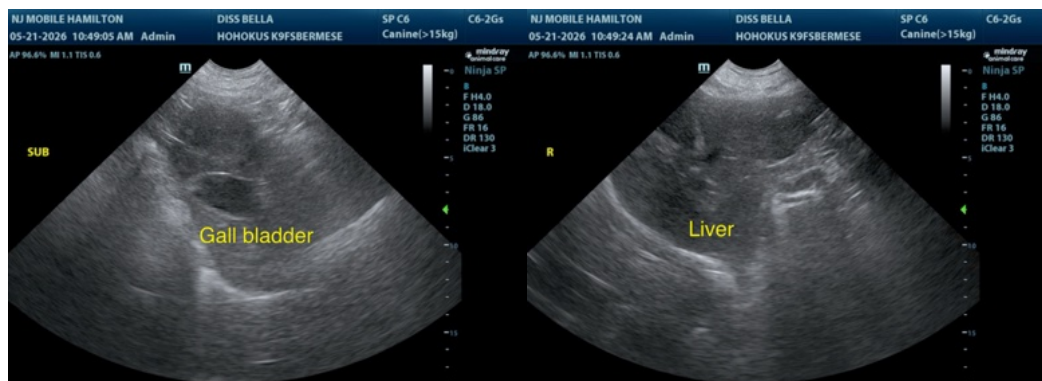
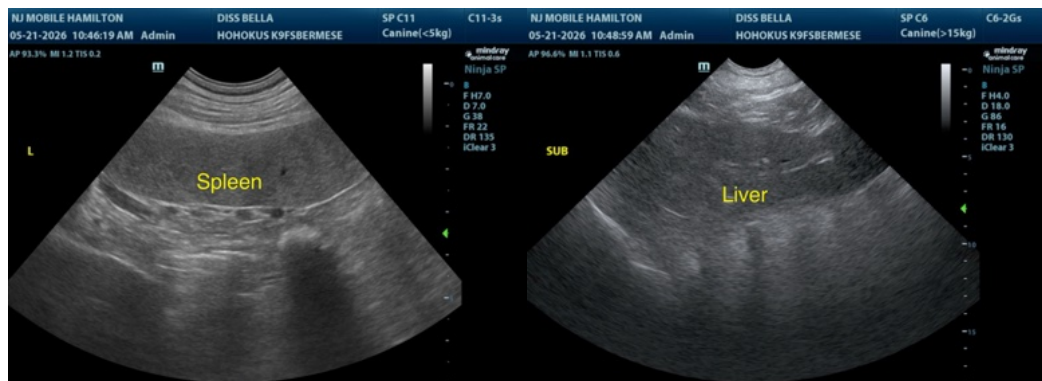
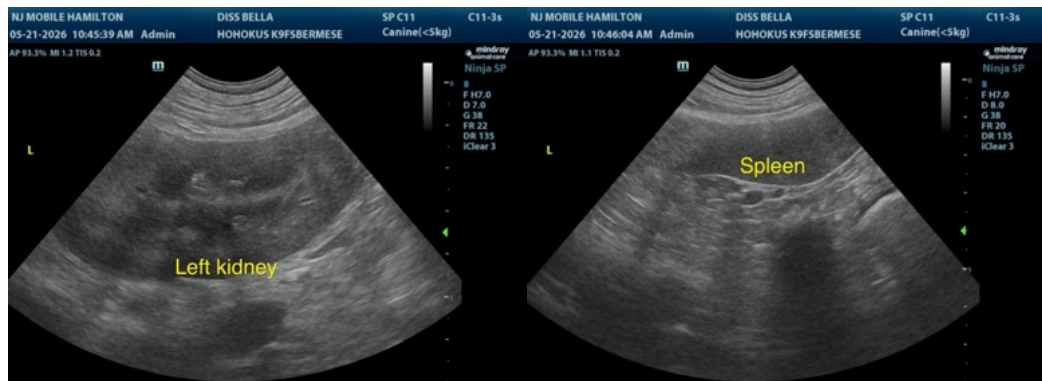
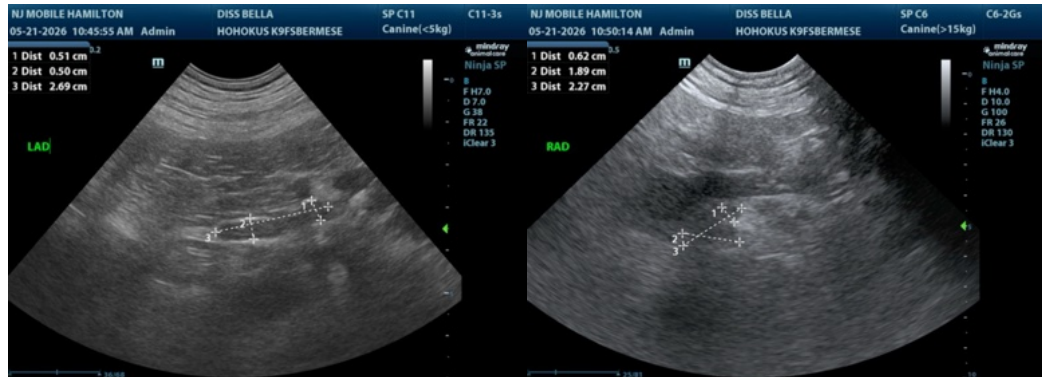
Dr. Gannon

**INVOICE**

77874

**DATE**

5/21/26





**PATIENT**

Bella Diss

**SPECIES**

Canine

**BREED**

Bernese Mountain Dog

**SEX**

Spayed female

**AGE**

Not provided

**WEIGHT**

117 lbs

**INTERPRETED BY**

Remo Lobetti, BVSc,  
MMedVet (Med),  
PhD, Dipl. ECVIM

**IMAGING PERFORMED BY**

Rebecca Hamilton

**HOSPITAL NAME**

HoHoKus VH

**REFERRING VET**

Dr. Gannon

**INVOICE**

77874

**DATE**

5/21/26

The information and recommendations provided are based on the images presented by the referring veterinarian/sonographer. No evaluation can be communicated regarding pathology that was not visible in the image/video clips provided.

Thank you for this referral. If the clinical or image interpretation does not parallel your findings or if I can be of any further assistance please contact me.

Remo Lobetti, BVSc, MMedVet (Med), PhD, Dipl. ECVIM (Internal Medicine)

[info@sonopath.com](mailto:info@sonopath.com)