



PATIENT PRESENTING CLINICAL SIGNS

Skye Gilmartin
History: Elev alp (progressive) exam WNL, no clinical signs
April 2026- alp-859 May 2026- alp-1,275

SPECIES

Canine

BREED

Bernadoodle

SEX

Spayed female

AGE

5 years

WEIGHT

43 lbs

INTERPRETED BY

Remo Lobetti, BVSc,
MMedVet (Med),
PhD, Dipl. ECVIM

IMAGING PERFORMED BY

Kerri Becker

HOSPITAL NAME

Bergen County VC

REFERRING VET

Dr. Santo

INVOICE

77761

DATE

5/20/26

ULTRASONOGRAPHIC EXAMINATION OF THE ABDOMEN

Urinary System

The urinary bladder is full with a normal thickness and smooth appearance of the wall. Normal anechoic urine with no sediment or uroliths evident.

Normal appearance of the trigone area, proximal urethra, and iliac blood vessels.

Normal appearance and size of the iliac lymph nodes. Ureters not visualized, which can be considered a normal finding.

Normal renal size (left measured 5.4 cm, right measured 5.1 cm), architecture, echogenic appearance, cortico-medullary differentiation, which maintains a 1:3 cortex to medulla ratio, pelvis, and capsule. No infarcts, mineralization or renoliths evident. Normal color flow pattern is evident in both kidneys.

Adrenal Glands

Normal shape, echogenic appearance, size, position, and appearance of the visible peri-adrenal vasculature. Left adrenal gland measured 2.6 cm in length x 0.89 cm and 0.59 cm in width. The right adrenal gland measured 2.29 cm in length x 0.57 cm in width.

Spleen

Normal size and echogenic appearance. Smooth homogenous parenchyma and regular curvilinear capsule. Normal volume of the splenic vasculature without any overt congestion or thrombosis evident. No inflammatory, neoplastic, infarction, or infiltrative changes evident. The spleen measured 1.4 cm in width.

Liver

Normal size, echogenic appearance, portal markings, and regular curvilinear capsule. No nodules or masses evident. Normal appearance of the hepatic and portal vasculature.

Gallbladder

The gallbladder is full containing a small amount of non-adhered, hyperechogenic sediment. Normal thickness and echogenic appearance of the wall. Normal size and appearance of the cystic and common bile duct.



PATIENT

Skye Gilmartin

SPECIES

Canine

BREED

Bernadoodle

SEX

Spayed female

AGE

5 years

WEIGHT

43 lbs

INTERPRETED BY

Remo Lobetti, BVSc,
MMedVet (Med),
PhD, Dipl. ECVIM

IMAGING PERFORMED BY

Kerri Becker

HOSPITAL NAME

Bergen County VC

REFERRING VET

Dr. Santo

INVOICE

77761

DATE

5/20/26

Gastrointestinal

Normal appearance of the stomach, duodenum, small intestine, ileo-cecal junction, and colon with no loss of layering, 1:3 muscularis to mucosa ratio, normal wall thickness and peristaltic activity, and no distension of the lumen.

Pancreas

The visible sections of the pancreas are of normal size and echogenic appearance with a regular capsule. Normal echogenic appearance of the mesentery and fat surrounding the pancreas.

Free Abdomen

Normal mesenteric lymph nodes.

No ascites evident.

ULTRASONOGRAPHIC FINDINGS

- Gallbladder sediment

INTERPRETATION OF THE FINDINGS & FURTHER RECOMMENDATIONS

In essence a normal ultrasound examination of the abdomen as the gallbladder sediment can be considered an incidental finding.

On this ultrasound there is no obvious etiology for the progressive elevation of ALP activity.

Although there are no obvious clinical signs and the adrenal glands appear ultrasonographically normal, with the progressive elevation of ALP activity, emerging pituitary dependent Cushing's disease should still be considered.

Further assessment would be urine specific gravity and urine cortisol to creatinine ratio and if abnormal then adrenal function testing (ACTH stimulation/LDDST) would then be indicated.

If Cushing's disease has been excluded then further assessment of the elevated ALP activity would be FNA cytology of the liver. However, a tru cut or wedge biopsy may be required for a final etiological diagnosis.

Specific therapy would be dependent on an etiological diagnosis.

Symptomatic management that could be considered would be the use of Ursodiol with regular monitoring of liver enzyme activity.



PATIENT

Skye Gilmartin

SPECIES

Canine

BREED

Bernadoodle

SEX

Spayed female

AGE

5 years

WEIGHT

43 lbs

INTERPRETED BY

Remo Lobetti, BVSc,
 MMedVet (Med),
 PhD, Dipl. ECVIM

IMAGING PERFORMED BY

Kerri Becker

HOSPITAL NAME

Bergen County VC

REFERRING VET

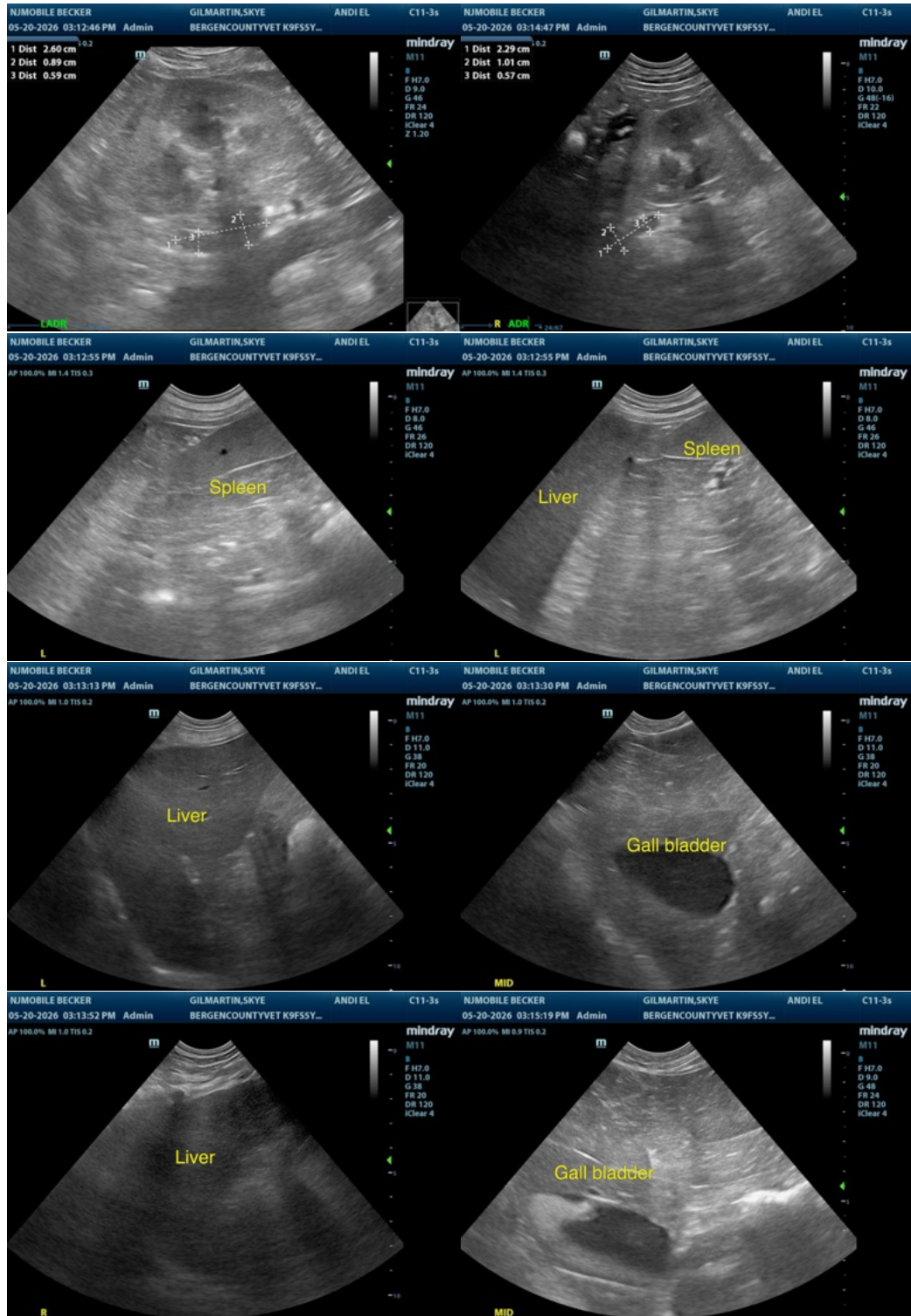
Dr. Santo

INVOICE

77761

DATE

5/20/26





PATIENT

Skye Gilmartin

SPECIES

Canine

BREED

Bernadoodle

SEX

Spayed female

AGE

5 years

WEIGHT

43 lbs

INTERPRETED BY

Remo Lobetti, BVSc,
MMedVet (Med),
PhD, Dipl. ECVIM

IMAGING PERFORMED BY

Kerri Becker

HOSPITAL NAME

Bergen County VC

REFERRING VET

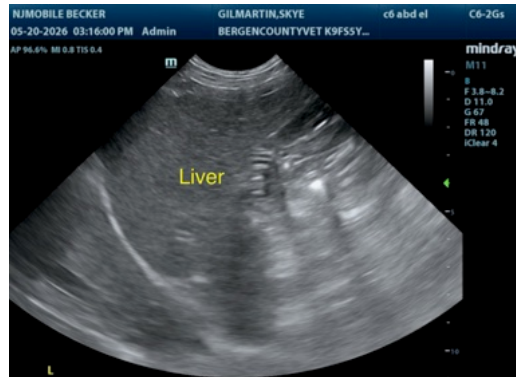Dr. Santo

INVOICE

77761

DATE

5/20/26



The information and recommendations provided are based on the images presented by the referring veterinarian/sonographer. No evaluation can be communicated regarding pathology that was not visible in the image/video clips provided.

Thank you for this referral. If the clinical or image interpretation does not parallel your findings or if I can be of any further assistance please contact me.

Remo Lobetti, BVSc, MMedVet (Med), PhD, Dipl. ECVIM (Internal Medicine)

info@sonopath.com