



PATIENT

Julian Lopinto

SPECIES

Canine

BREED

Hound Mix

SEX

Neutered male

AGE

10 ½ years

WEIGHT

91 lbs

INTERPRETED BY

Remo Lobetti, BVSc,
MMedVet (Med),
PhD, Dipl. ECVIM

IMAGING PERFORMED BY

Shari Reffi, CVT

HOSPITAL NAME

Farview AC

REFERRING VET

Dr. Thomas

INVOICE

77626

DATE

5/18/26

PRESENTING CLINICAL SIGNS

History: BCS 8/9. Inappetence, not acting himself-lethargic, possible liver or splenic mass. PE-pale mm, painful abdominal palpation. Mid abd. mass. Current Medications: Yunan Baiyo 1 once a day.

ULTRASONOGRAPHIC EXAMINATION OF THE ABDOMEN

Urinary System

The urinary bladder is full with a normal thickness and smooth appearance of the wall. Normal anechoic urine with no sediment or uroliths evident.

Normal appearance of the trigone area, proximal urethra, and iliac blood vessels.

Normal appearance and size of the iliac lymph nodes. Ureters not visualized, which can be considered a normal finding.

Normal renal size (left measured 8.1 cm, right measured 8.5 cm), architecture, echogenic appearance, cortico-medullary differentiation, which maintains a 1:3 cortex to medulla ratio, pelvis, and capsule. No infarcts, mineralization or renoliths evident. Normal color flow pattern is evident around both kidneys.

The prostate is small and hypoechogenic measuring 0.9 cm in width.

Adrenal Glands

Normal shape, echogenic appearance, size, position, and appearance of the visible peri-adrenal vasculature. Left adrenal gland measured 2.69 cm in length x 0.85 cm and 0.6 cm in width. The right adrenal gland measured 2.32 cm in length x 0.72 cm and 0.52 cm in width.

Spleen

The spleen is large and irregular with mottled echogenic, cystic and poorly vascularized mass measuring 6.5 x 7.0 cm originating off the tail of the spleen. The rest of the spleen is of normal size (2.9 cm in width) maintaining a normal echogenic appearance, smooth homogenous parenchyma and regular curvilinear capsule. Normal volume of the splenic vasculature without any overt congestion or thrombosis evident.

Liver

Normal size, echogenic appearance, portal markings, and regular curvilinear capsule. No nodules or masses evident. Normal appearance of the hepatic and portal vasculature.



PATIENT

Julian Lopinto

SPECIES

Canine

BREED

Hound Mix

SEX

Neutered male

AGE

10 ½ years

WEIGHT

91 lbs

INTERPRETED BY

Remo Lobetti, BVSc,
MMedVet (Med),
PhD, Dipl. ECVIM

IMAGING PERFORMED BY

Shari Reffi, CVT

HOSPITAL NAME

Farview AC

REFERRING VET

Dr. Thomas

INVOICE

77626

DATE

5/18/26

Gallbladder

The gallbladder is full containing normal anechoic bile. Normal thickness and echogenic appearance of the wall. Normal size and appearance of the cystic and common bile duct.

Gastrointestinal

Normal appearance of the stomach, duodenum, small intestine, ileo-cecal junction, and colon with no loss of layering, 1:3 muscularis to mucosa ratio, normal wall thickness and peristaltic activity, and no distension of the lumen.

Pancreas

The visible sections of the pancreas are of normal size and echogenic appearance with a regular capsule. Normal echogenic appearance of the mesentery and fat surrounding the pancreas.

Free Abdomen

Normal mesenteric lymph nodes.

A scant amount of ascites present.

Thorax

Normal appearance of the heart. No pericardial or pleural effusion evident.

ULTRASONOGRAPHIC FINDINGS

- Splenic mass.
- Ascites.

INTERPRETATION OF THE FINDINGS & FURTHER RECOMMENDATIONS

The most likely etiology for the splenic mass would be neoplasia with granuloma and hematoma possible differential diagnosis.

The ascites can be ascribed as secondary to the splenic mass.

Further assessment would be three view thoracic radiographs and possibly FNA cytology of the mass.

Splenectomy should be considered as it could be both diagnostic and therapeutic with further specific therapy dependent on an etiological diagnosis.



PATIENT

Julian Lopinto

SPECIES

Canine

BREED

Hound Mix

SEX

Neutered male

AGE

10 ½ years

WEIGHT

91 lbs

INTERPRETED BY

Remo Lobetti, BVSc,
MMedVet (Med),
PhD, Dipl. ECVIM

IMAGING PERFORMED BY

Shari Reffi, CVT

HOSPITAL NAME

Farview AC

REFERRING VET

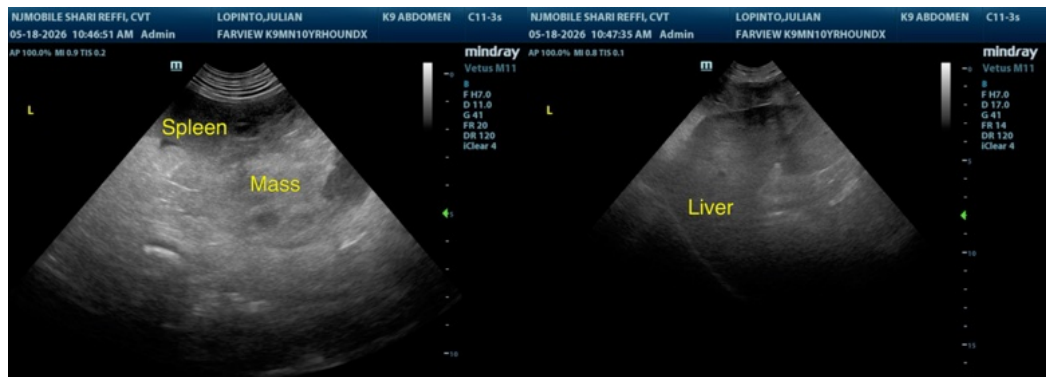
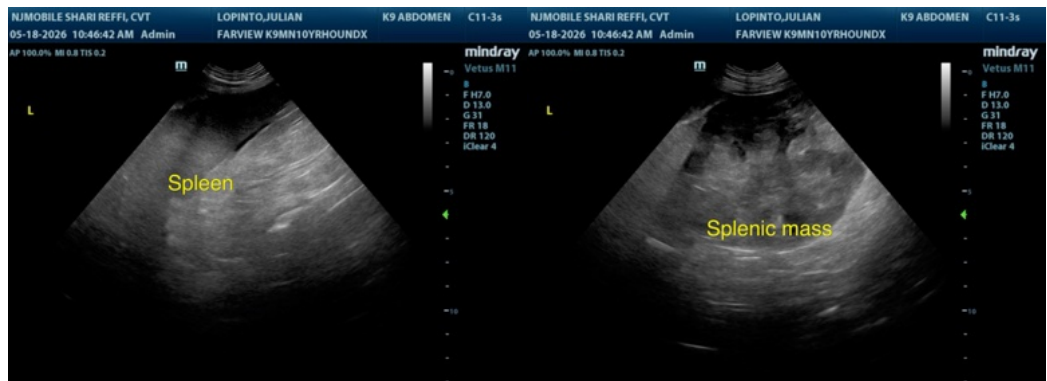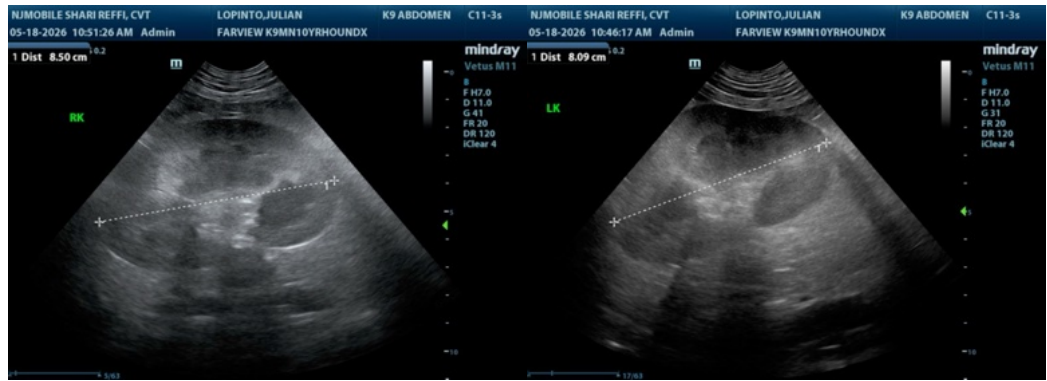
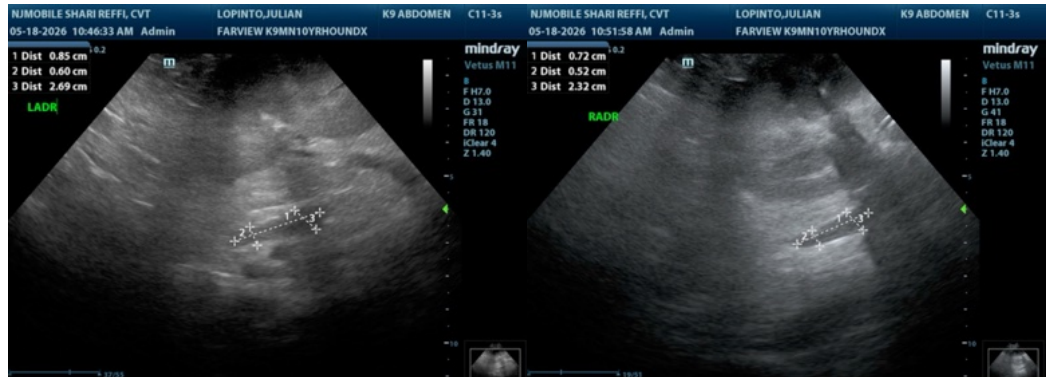
Dr. Thomas

INVOICE

77626

DATE

5/18/26





PATIENT

Julian Lopinto

SPECIES

Canine

BREED

Hound Mix

SEX

Neutered male

AGE

10 ½ years

WEIGHT

91 lbs

INTERPRETED BY

Remo Lobetti, BVSc,
MMedVet (Med),
PhD, Dipl. ECVIM

IMAGING PERFORMED BY

Shari Reffi, CVT

HOSPITAL NAME

Farview AC

REFERRING VET

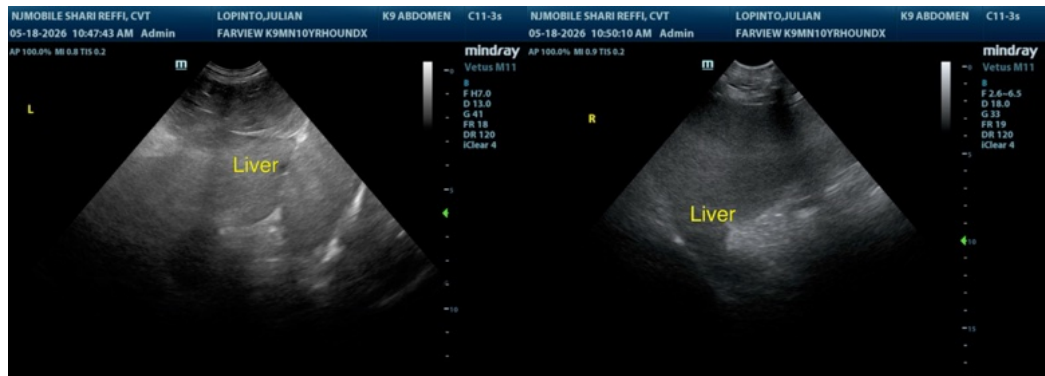
Dr. Thomas

INVOICE

77626

DATE

5/18/26



The information and recommendations provided are based on the images presented by the referring veterinarian/sonographer. No evaluation can be communicated regarding pathology that was not visible in the image/video clips provided.

Thank you for this referral. If the clinical or image interpretation does not parallel your findings or if I can be of any further assistance please contact me.

Remo Lobetti, BVSc, MMedVet (Med), PhD, Dipl. ECVIM (Internal Medicine)

info@sonopath.com