



**PATIENT PRESENTING CLINICAL SIGNS**

Loki Grambone  
History: WT loss- xray and bw wnl food the same  
Cortisol-6.5 T4 bnp fecal all normal TLI cob normal folate -4

**SPECIES**

Canine

**ULTRASONOGRAPHIC EXAMINATION OF THE ABDOMEN**

**BREED**

**Urinary System**

Labrador

The urinary bladder is small with a normal thickness and smooth appearance of the wall. Normal anechoic urine with no sediment or uroliths evident.

**SEX**

Normal appearance of the trigone area, proximal urethra, and iliac blood vessels.

Male

Normal appearance and size of the iliac lymph nodes. Ureters not visualized, which can be considered a normal finding.

**AGE**

4 years

Normal renal size (left measured 7.0 cm, right measured 6.9 cm), architecture, echogenic appearance, cortico-medullary differentiation, which maintains a 1:3 cortex to medulla ratio, pelvis, and capsule. No infarcts, mineralization or renoliths evident. Normal color flow pattern is evident in both kidneys.

**WEIGHT**

74 lbs

Normal size and appearance of the prostate with regular curvilinear capsule and normal appearance of the periprostatic tissue. The prostatic gland measures 2.2 x 3.3 cm in size. Normal size and appearance of both testicles. The left testicle measures 3.3 cm in length and the right testicle measured 3.0 cm in length.

**INTERPRETED BY**

Remo Lobetti, BVSc,  
MMedVet (Med),  
PhD, Dipl. ECVIM

**Adrenal Glands**

Normal shape, echogenic appearance, size, position, and appearance of the visible peri-adrenal vasculature. Left adrenal gland measured 2.33 cm in length x 0.63 cm and 0.6 cm in width. The right adrenal gland measured 2.5 cm in length x 0.9 cm in width.

**IMAGING PERFORMED BY**

Kerri Becker

**HOSPITAL NAME**

Legacy AH

**Spleen**

Normal size and echogenic appearance. Smooth homogenous parenchyma and regular curvilinear capsule. Normal volume of the splenic vasculature without any overt congestion or thrombosis evident. No inflammatory, neoplastic, infarction, or infiltrative changes evident. The spleen measured 2.2 cm in width.

**REFERRING VET**

Dr. Potenzzone

**INVOICE**

75531

**Liver**

Normal size, echogenic appearance, portal markings, and regular curvilinear capsule. No nodules or masses evident. Normal appearance of the hepatic and portal vasculature.

**DATE**

5/14/26



**PATIENT**

Loki Grambone

**SPECIES**

Canine

**BREED**

Labrador

**SEX**

Male

**AGE**

4 years

**WEIGHT**

74 lbs

**INTERPRETED BY**

Remo Lobetti, BVSc,  
MMedVet (Med),  
PhD, Dipl. ECVIM

**IMAGING  
PERFORMED BY**

Kerri Becker

**HOSPITAL NAME**

Legacy AH

**REFERRING VET**

Dr. Potenzone

**INVOICE**

75531

**DATE**

5/14/26

***Gallbladder***

The gallbladder is full containing normal anechoic bile. Normal thickness and echogenic appearance of the wall. Normal size and appearance of the cystic and common bile duct.

***Gastrointestinal***

Normal appearance of the stomach, duodenum, small intestine, ileo-cecal junction, and colon with no loss of layering, 1:3 muscularis to mucosa ratio, normal wall thickness and peristaltic activity, and no distension of the lumen.

***Pancreas***

The visible sections of the pancreas are of normal size and echogenic appearance with a regular capsule. Normal echogenic appearance of the mesentery and fat surrounding the pancreas.

***Free Abdomen***

Normal mesenteric lymph nodes.

No ascites evident.

***Thorax***

Normal appearance of the heart. No pericardial or pleural effusion evident.

**ULTRASONOGRAPHIC FINDINGS**

- Normal ultrasound examination of the abdomen.

**INTERPRETATION OF THE FINDINGS & FURTHER RECOMMENDATIONS**

On this ultrasound there is no obvious etiology for the weight loss.

With normal bloodwork, ultrasound, fecal analysis and GI panel, a possible etiology for the weight loss is that food intake does not match energy output. Therefore, increasing the amount of food fed should be considered.



**PATIENT**

Loki Grambone

**SPECIES**

Canine

**BREED**

Labrador

**SEX**

Male

**AGE**

4 years

**WEIGHT**

74 lbs

**INTERPRETED BY**

Remo Lobetti, BVSc,  
 MMedVet (Med),  
 PhD, Dipl. ECVIM

**IMAGING PERFORMED BY**

Kerri Becker

**HOSPITAL NAME**

Legacy AH

**REFERRING VET**

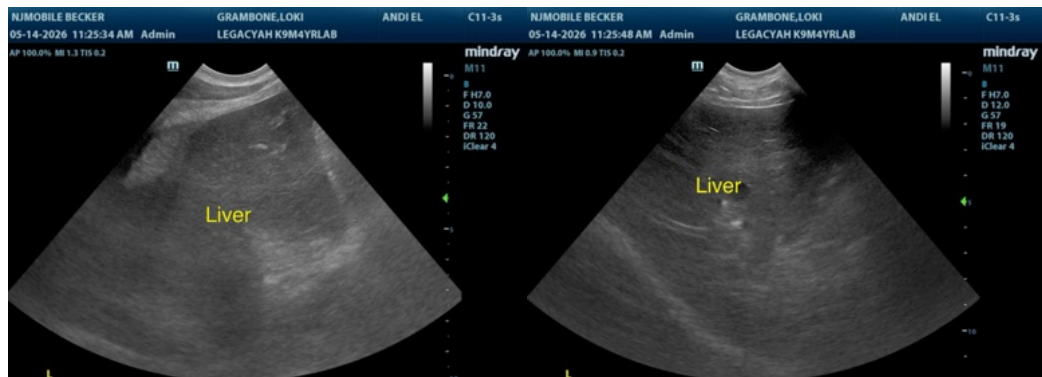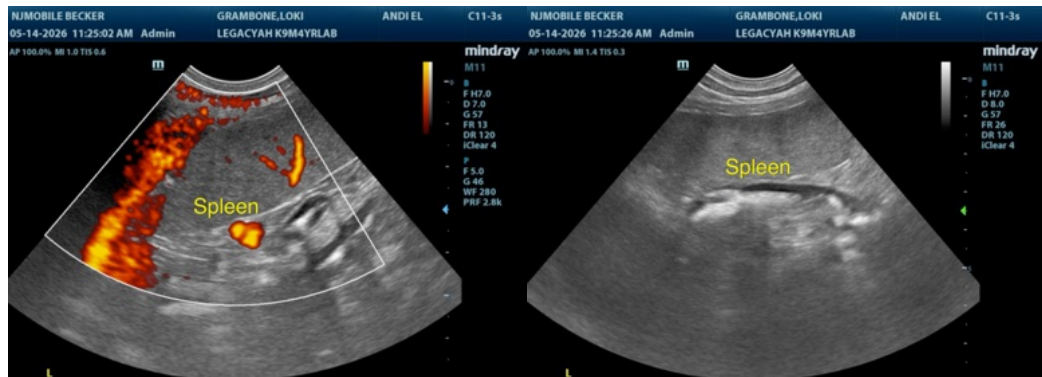
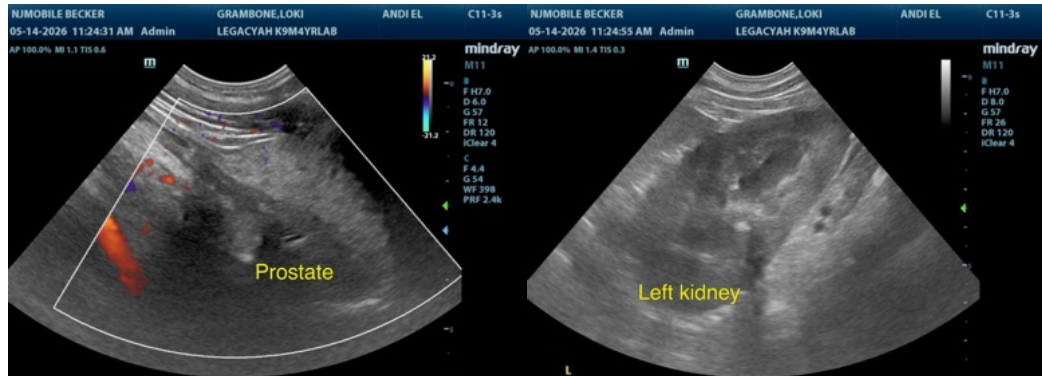
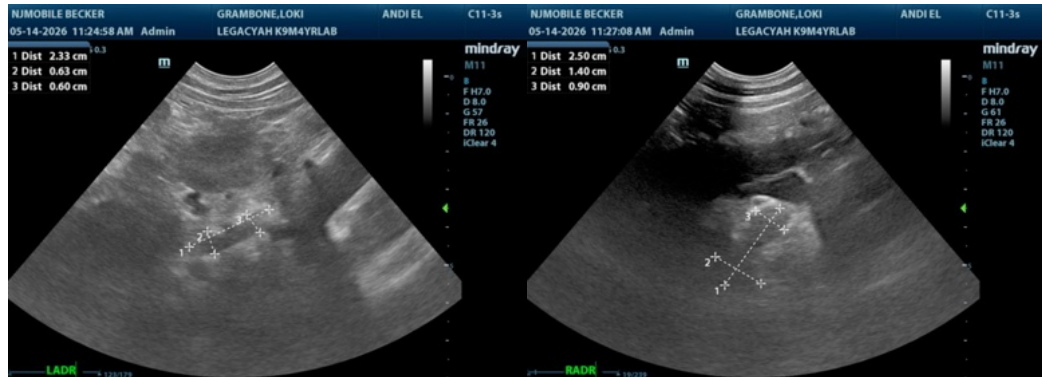
Dr. Potenzzone

**INVOICE**

75531

**DATE**

5/14/26





**PATIENT**

Loki Grambone

**SPECIES**

Canine

**BREED**

Labrador

**SEX**

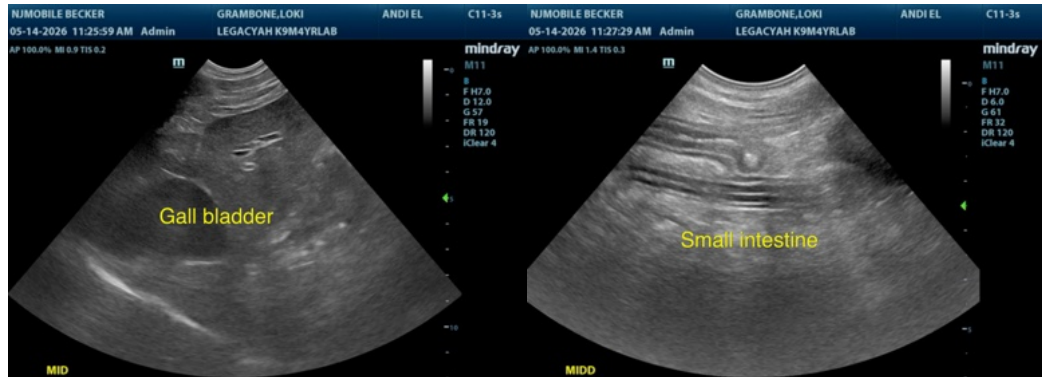
Male

**AGE**

4 years

**WEIGHT**

74 lbs



The information and recommendations provided are based on the images presented by the referring veterinarian/sonographer. No evaluation can be communicated regarding pathology that was not visible in the image/video clips provided.

Thank you for this referral. If the clinical or image interpretation does not parallel your findings or if I can be of any further assistance please contact me.

Remo Lobetti, BVSc, MMedVet (Med), PhD, Dipl. ECVIM (Internal Medicine)

[info@sonopath.com](mailto:info@sonopath.com)

**INTERPRETED BY**

Remo Lobetti, BVSc,  
 MMedVet (Med),  
 PhD, Dipl. ECVIM

**IMAGING PERFORMED BY**

Kerri Becker

**HOSPITAL NAME**

Legacy AH

**REFERRING VET**

Dr. Potenzzone

**INVOICE**

75531

**DATE**

5/14/26