



## PATIENT

Bromley Givant

## SPECIES

Canine

## BREED

Bernadoodle

## SEX

Spayed female

## AGE

5 years

## WEIGHT

63 lbs

## INTERPRETED BY

Remo Lobetti, BVSc,  
MMedVet (Med),  
PhD, Dipl. ECVIM

## IMAGING PERFORMED BY

Rebecca Hamilton

## HOSPITAL NAME

Wyckoff VH

## REFERRING VET

Dr. Eisenberg

## INVOICE

75534

## DATE

5/14/26

## PRESENTING CLINICAL SIGNS

History: Met check, aggressive Grade 2 MCT

## ULTRASONOGRAPHIC EXAMINATION OF THE ABDOMEN

### *Urinary System*

The urinary bladder is small with a normal thickness and smooth appearance of the wall. Normal anechoic urine with no sediment or uroliths evident.

Normal appearance of the trigone area, proximal urethra, and iliac blood vessels.

Normal appearance and size of the iliac lymph nodes. Ureters not visualized, which can be considered a normal finding.

Normal renal size (left measured 6.6 cm, right measured 7.0 cm), architecture, echogenic appearance, cortico-medullary differentiation, which maintains a 1:3 cortex to medulla ratio, pelvis, and capsule. No infarcts, mineralization or renoliths evident.

### *Adrenal Glands*

Normal shape, echogenic appearance, size, position, and appearance of the visible peri-adrenal vasculature. Left adrenal gland measured 2.76 cm in length x 0.46 cm and 0.45 cm in width. The right adrenal gland measured 2.83 cm in length x 0.68 cm and 0.81 cm in width.

### *Spleen*

Normal size and echogenic appearance. Smooth homogenous parenchyma and regular curvilinear capsule. Normal volume of the splenic vasculature without any overt congestion or thrombosis evident. No inflammatory, neoplastic, infarction, or infiltrative changes evident. The spleen measured 1.8 cm.

### *Liver*

Normal size, echogenic appearance, portal markings, and regular curvilinear capsule. No nodules or masses evident. Normal appearance of the hepatic and portal vasculature. A well circumscribed cyst measuring 2.4 x 2.8 cm in size situated on the edge of the right lobe.

### *Gallbladder*

The gallbladder is small containing normal anechoic bile. A small intraluminal cyst measuring 1.3 x 1.4 cm in size containing hyperechogenic material. Normal thickness and echogenic appearance of the wall. Normal size and appearance of the cystic and common bile duct.



**PATIENT**

Bromley Givant

**SPECIES**

Canine

**BREED**

Bernadoodle

**SEX**

Spayed female

**AGE**

5 years

**WEIGHT**

63 lbs

**INTERPRETED BY**

Remo Lobetti, BVSc,  
MMedVet (Med),  
PhD, Dipl. ECVIM

**IMAGING PERFORMED BY**

Rebecca Hamilton

**HOSPITAL NAME**

Wyckoff VH

**REFERRING VET**

Dr. Eisenberg

**INVOICE**

75534

**DATE**

5/14/26

**Gastrointestinal**

Normal appearance of the stomach, duodenum, small intestine, ileo-cecal junction, and colon with no loss of layering, 1:3 muscularis to mucosa ratio, normal wall thickness and peristaltic activity, and no distension of the lumen. Fecal material was present within the colon.

**Pancreas**

The visible sections of the pancreas are of normal size and echogenic appearance with a regular capsule. Normal echogenic appearance of the mesentery and fat surrounding the pancreas.

**Free Abdomen**

Normal mesenteric lymph nodes.

No ascites evident.

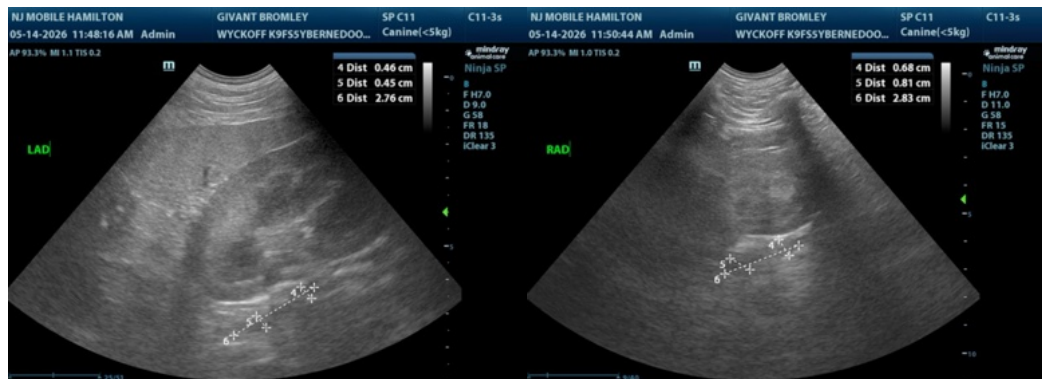**ULTRASONOGRAPHIC FINDINGS**

- Hepatic cyst. Intraluminal gallbladder cyst. Both of which can be considered incidental finding.

**INTERPRETATION OF THE FINDINGS & FURTHER RECOMMENDATIONS**

On this ultrasound there is no obvious evidence of metastatic mast cell neoplasia.

Further assessment that could be considered to complete the metastatic screen would be FNA cytology of the liver and spleen.





**PATIENT**

Bromley Givant

**SPECIES**

Canine

**BREED**

Bernadoodle

**SEX**

Spayed female

**AGE**

5 years

**WEIGHT**

63 lbs

**INTERPRETED BY**

Remo Lobetti, BVSc,  
 MMedVet (Med),  
 PhD, Dipl. ECVIM

**IMAGING PERFORMED BY**

Rebecca Hamilton

**HOSPITAL NAME**

Wyckoff VH

**REFERRING VET**

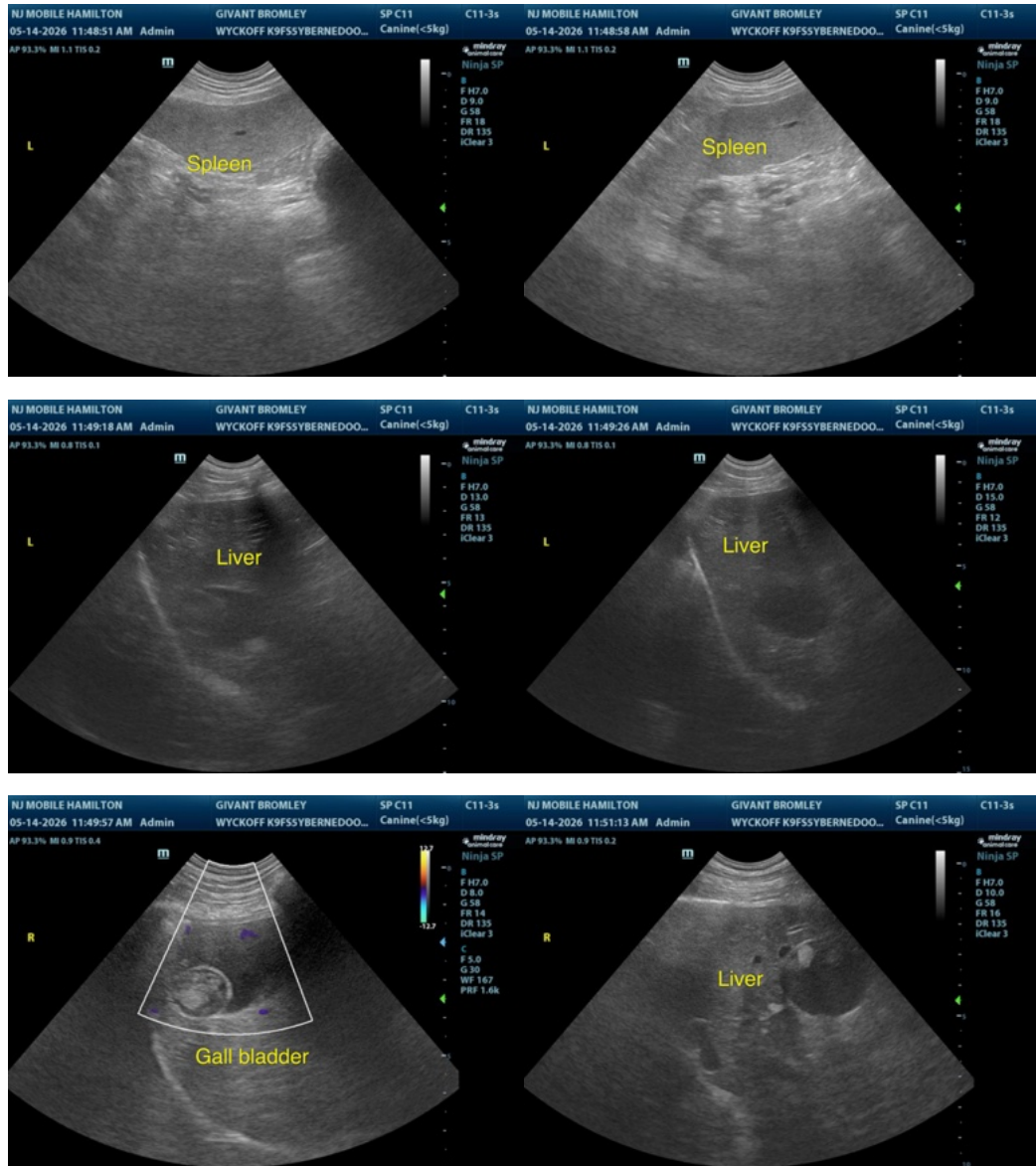
Dr. Eisenberg

**INVOICE**

75534

**DATE**

5/14/26



The information and recommendations provided are based on the images presented by the referring veterinarian/sonographer. No evaluation can be communicated regarding pathology that was not visible in the image/video clips provided.

Thank you for this referral. If the clinical or image interpretation does not parallel your findings or if I can be of any further assistance please contact me.

Remo Lobetti, BVSc, MMedVet (Med), PhD, Dipl. ECVIM (Internal Medicine)

[info@sonopath.com](mailto:info@sonopath.com)