



PATIENT PRESENTING CLINICAL SIGNS

Joey Isak Losing wt, is diabetic, suspect Cushing's disease, prev BW showed elevated kidney values.

SPECIES ULTRASONOGRAPHIC EXAMINATION OF THE ABDOMEN

Canine

BREED Urinary System

Samoyed The urinary bladder is full with a normal thickness and smooth appearance of the wall. Normal anechoic urine with no sediment or uroliths evident.

SEX Normal appearance of the trigone area and iliac blood vessels. The proximal urethra was not visualized.

Neutered male Normal appearance and size of the iliac lymph nodes. Ureters not visualized, which can be considered a normal finding.

AGE Normal renal size (left measured 6.5 cm, right measured 7.8 cm), architecture, echogenic appearance, cortico-medullary differentiation, which maintains a 1:3 cortex to medulla ratio, pelvis, and capsule. No infarcts, mineralization or renoliths evident.

9 years

WEIGHT The prostate was not visualized.

97.5 lbs

INTERPRETED BY Adrenal Glands

Remo Lobetti, BVSc, MMedVet (Med), PhD, Dipl. ECVIM Normal shape, echogenic appearance, size, position, and appearance of the visible peri-adrenal vasculature. Left adrenal gland measured 2.64 cm in length x 0.64 cm and 0.61 cm in width. The right adrenal gland measured 2.67 cm in length x 0.88 cm in width.

IMAGING PERFORMED BY Spleen

Kerri Becker Normal size and echogenic appearance. Smooth homogenous parenchyma and regular curvilinear capsule. Normal volume of the splenic vasculature without any overt congestion or thrombosis evident.

HOSPITAL NAME Incidental myelolipoma is present. No inflammatory, neoplastic, infarction, or infiltrative changes evident. The spleen measured 1.5 cm in width.

Farview AC

REFERRING VET Liver

Dr. Mosaad Normal size with a diffuse, increased echogenic appearance, normal portal markings, and regular curvilinear capsule. No nodules or masses evident. Normal appearance of the hepatic and portal vasculature.

INVOICE Gallbladder

75356

DATE The gallbladder is full containing normal anechoic bile. Normal thickness and echogenic appearance of the wall. Normal size and appearance of the cystic and common bile duct.

5/12/26



PATIENT

Joey Isak

SPECIES

Canine

BREED

Samoyed

SEX

Neutered male

AGE

9 years

WEIGHT

97.5 lbs

INTERPRETED BY

Remo Lobetti, BVSc,
MMedVet (Med),
PhD, Dipl. ECVIM

IMAGING PERFORMED BY

Kerri Becker

HOSPITAL NAME

Farview AC

REFERRING VET

Dr. Mosaad

INVOICE

75356

DATE

5/12/26

Gastrointestinal

Normal appearance of the stomach, duodenum, small intestine, ileo-cecal junction, and colon with no loss of layering, 1:3 muscularis to mucosa ratio, normal wall thickness and peristaltic activity, and no distension of the lumen.

Pancreas

The visible sections of the pancreas are of normal size and echogenic appearance with a regular capsule. Normal echogenic appearance of the mesentery and fat surrounding the pancreas.

Free Abdomen

Normal mesenteric lymph nodes.

No ascites evident.

ULTRASONOGRAPHIC FINDINGS

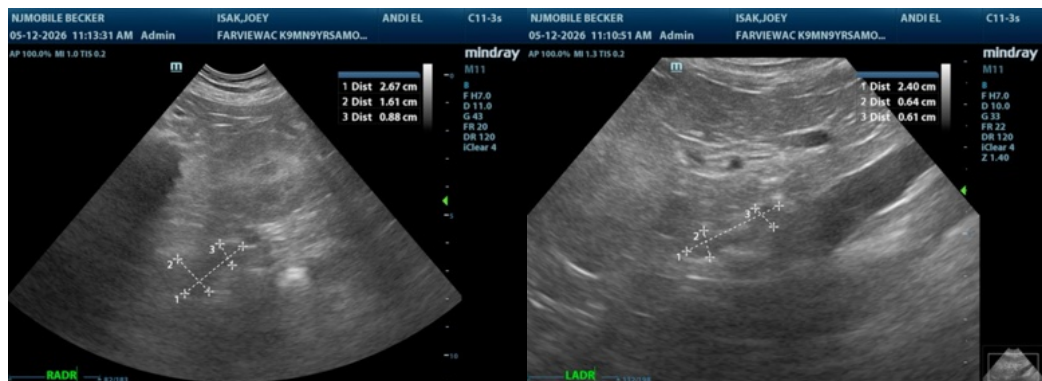
- Hepatopathy.

INTERPRETATION OF THE FINDINGS & FURTHER RECOMMENDATIONS

The most likely etiology for the hepatopathy would be vacuolar secondary to the diabetes with reactive hyperplasia early nodular hyperplasia possible differential diagnosis and hepatitis and infiltrative neoplasia an unlikely differential diagnosis.

Initial further assessment would be to ensure adequate glucose control and possibly FNA cytology of the liver.

Further specific therapy would be dependent on an etiological diagnosis.





PATIENT

Joey Isak

SPECIES

Canine

BREED

Samoyed

SEX

Neutered male

AGE

9 years

WEIGHT

97.5 lbs

INTERPRETED BY

Remo Lobetti, BVSc,
 MMedVet (Med),
 PhD, Dipl. ECVIM

IMAGING PERFORMED BY

Kerri Becker

HOSPITAL NAME

Farview AC

REFERRING VET

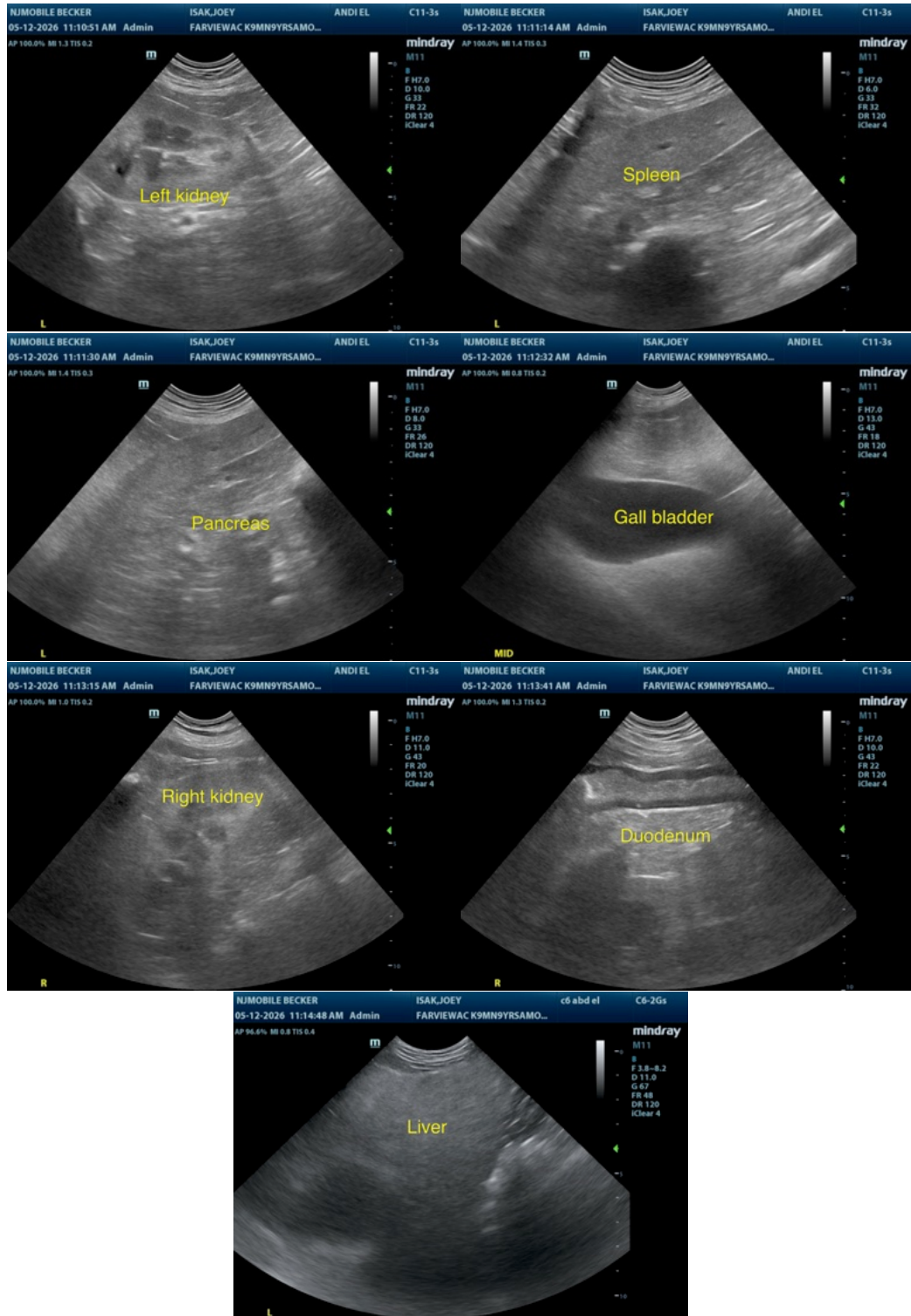
Dr. Mosaad

INVOICE

75356

DATE

5/12/26



The information and recommendations provided are based on the images presented by the referring veterinarian/sonographer. No evaluation can be communicated regarding pathology



PATIENT

Joey Isak

that was not visible in the image/video clips provided.

Thank you for this referral. If the clinical or image interpretation does not parallel your findings or if I can be of any further assistance please contact me.

SPECIES

Canine

Remo Lobetti, BVSc, MMedVet (Med), PhD, Dipl. ECVIM (Internal Medicine)

info@sonopath.com

BREED

Samoyed

SEX

Neutered male

AGE

9 years

WEIGHT

97.5 lbs

INTERPRETED BY

Remo Lobetti, BVSc,
MMedVet (Med),
PhD, Dipl. ECVIM

IMAGING PERFORMED BY

Kerri Becker

HOSPITAL NAME

Farview AC

REFERRING VET

Dr. Mosaad

INVOICE

75356

DATE

5/12/26