



## PATIENT

Colby Hendrix

## SPECIES

Canine

## BREED

Mix

## SEX

Male

## AGE

9 years

## WEIGHT

45.2 lbs

## INTERPRETED BY

Remo Lobetti, BVSc,  
MMedVet (Med),  
PhD, Dipl. ECVIM

## IMAGING PERFORMED BY

Shari Reffi, CVT

## HOSPITAL NAME

Andover AH

## REFERRING VET

Dr. Lawlor

## INVOICE

74128

## DATE

4/3/26

## PRESENTING CLINICAL SIGNS

- BCS 5/9
- Proteinuria, Degen. AV valve Dz, mitral + tricuspid regurg.
- Hx HW Dz-treated/resolved
- Current Meds: Sotalol 60mg PO q12h (Torb sedation)
- 3/2024: TP 5.4 (L), Albumin 2.6 (L), Bilirubin 0.1 (H). UPC 2.1 (12/15/25)

## ULTRASONOGRAPHIC EXAMINATION OF THE ABDOMEN

### *Urinary System*

The urinary bladder is full with a normal thickness and smooth appearance of the wall. Normal anechoic urine with no sediment or uroliths evident.

Normal appearance of the trigone area, proximal urethra, and iliac blood vessels.

Normal appearance and size of the iliac lymph nodes. Ureters not visualized, which can be considered a normal finding.

Normal renal size (left measured 5.4 cm, right measured 5.2 cm), architecture, echogenic appearance, cortico-medullary differentiation, which maintains a 1:3 cortex to medulla ratio, pelvis, and capsule. No infarcts, mineralization or renoliths evident. Normal color flow pattern is evident in both kidneys.

The prostate is small and hypoechogenic measuring 1.1 cm in width.

### *Adrenal Glands*

Normal shape, echogenic appearance, size, position, and appearance of the visible peri-adrenal vasculature. Left adrenal gland measured 2.52 cm in length x 0.68 cm and 0.61 cm in width. The right adrenal gland measured 2.55 cm in length x 0.74 cm in width.

### *Spleen*

Normal size and echogenic appearance. Smooth homogenous parenchyma and regular curvilinear capsule. Normal volume of the splenic vasculature without any overt congestion or thrombosis evident. No inflammatory, neoplastic, infarction, or infiltrative changes evident. The spleen measured 2.1 cm in width.

### *Liver*

Normal size, echogenic appearance, portal markings, and regular curvilinear capsule. No nodules or masses evident. Normal appearance of the hepatic and portal vasculature.



## PATIENT

Colby Hendrix

## SPECIES

Canine

## BREED

Mix

## SEX

Male

## AGE

9 years

## WEIGHT

45.2 lbs

## INTERPRETED BY

Remo Lobetti, BVSc,  
MMedVet (Med),  
PhD, Dipl. ECVIM

## IMAGING PERFORMED BY

Shari Reffi, CVT

## HOSPITAL NAME

Andover AH

## REFERRING VET

Dr. Lawlor

## INVOICE

74128

## DATE

4/3/26

## *Gallbladder*

The gallbladder is full containing normal anechoic bile. Normal thickness and echogenic appearance of the wall. Normal size and appearance of the cystic and common bile duct.

## *Gastrointestinal*

Normal appearance of the stomach, duodenum, small intestine, ileo-cecal junction, and colon with no loss of layering, 1:3 muscularis to mucosa ratio, normal wall thickness and peristaltic activity, and no distension of the lumen.

## *Pancreas*

The visible sections of the pancreas are of normal size and echogenic appearance with a regular capsule. Normal echogenic appearance of the mesentery and fat surrounding the pancreas.

## *Free Abdomen*

Normal mesenteric lymph nodes.

A scant amount of ascites is present.

## ULTRASONOGRAPHIC FINDINGS

- Ascites.

## INTERPRETATION OF THE FINDINGS & FURTHER RECOMMENDATIONS

In essence a normal ultrasound examination of the abdomen as the ascites can be ascribed as secondary to the heart disease.

The hypoalbuminemia can be ascribed to the proteinuria.

Management of the proteinuria would be either an ace inhibitor or receptor blocker and Omega 3 fatty acid supplementation.



**PATIENT**

Colby Hendrix

**SPECIES**

Canine

**BREED**

Mix

**SEX**

Male

**AGE**

9 years

**WEIGHT**

45.2 lbs

**INTERPRETED BY**

Remo Lobetti, BVSc,  
MMedVet (Med),  
PhD, Dipl. ECVIM

**IMAGING PERFORMED BY**

Shari Reffi, CVT

**HOSPITAL NAME**

Andover AH

**REFERRING VET**

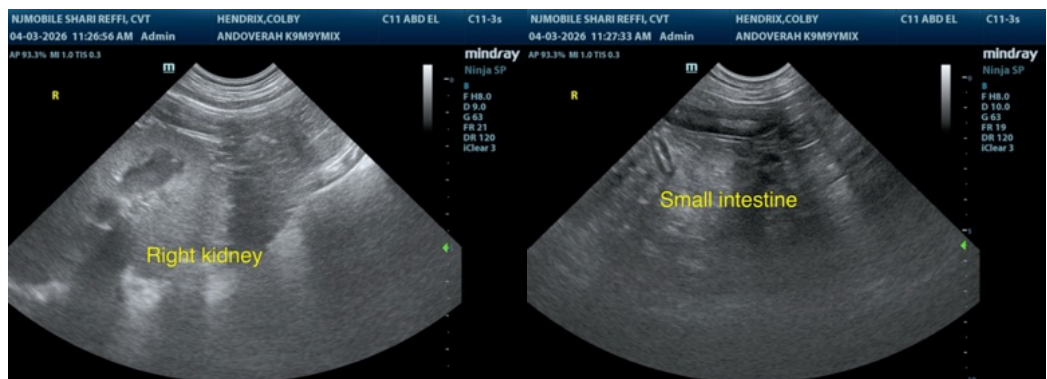
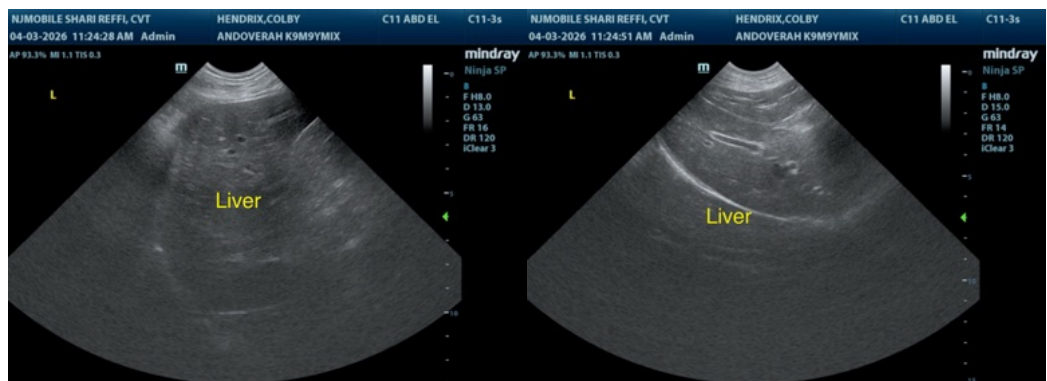
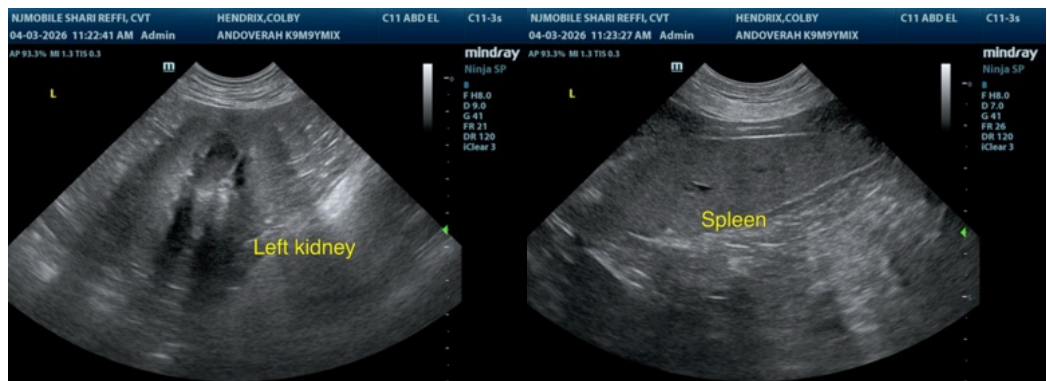
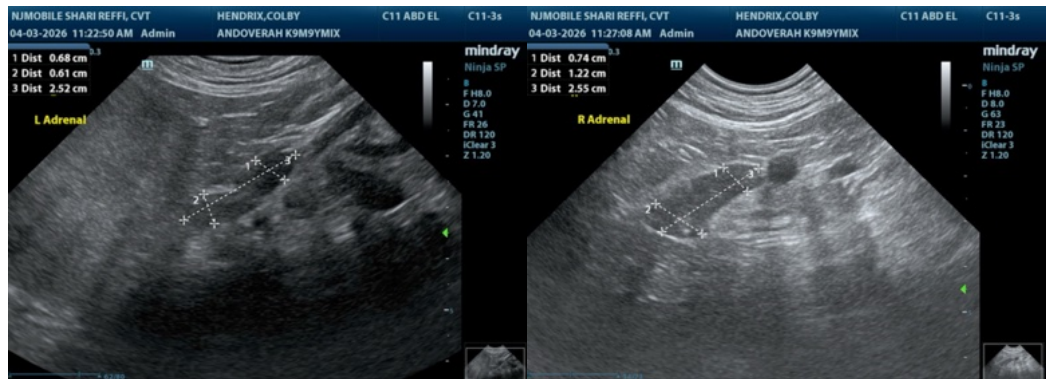
Dr. Lawlor

**INVOICE**

74128

**DATE**

4/3/26





## PATIENT

Colby Hendrix

## SPECIES

Canine

## BREED

Mix

## SEX

Male

## AGE

9 years

## WEIGHT

45.2 lbs

## INTERPRETED BY

Remo Lobetti, BVSc,  
MMedVet (Med),  
PhD, Dipl. ECVIM

## IMAGING PERFORMED BY

Shari Reffi, CVT

## HOSPITAL NAME

Andover AH

## REFERRING VET

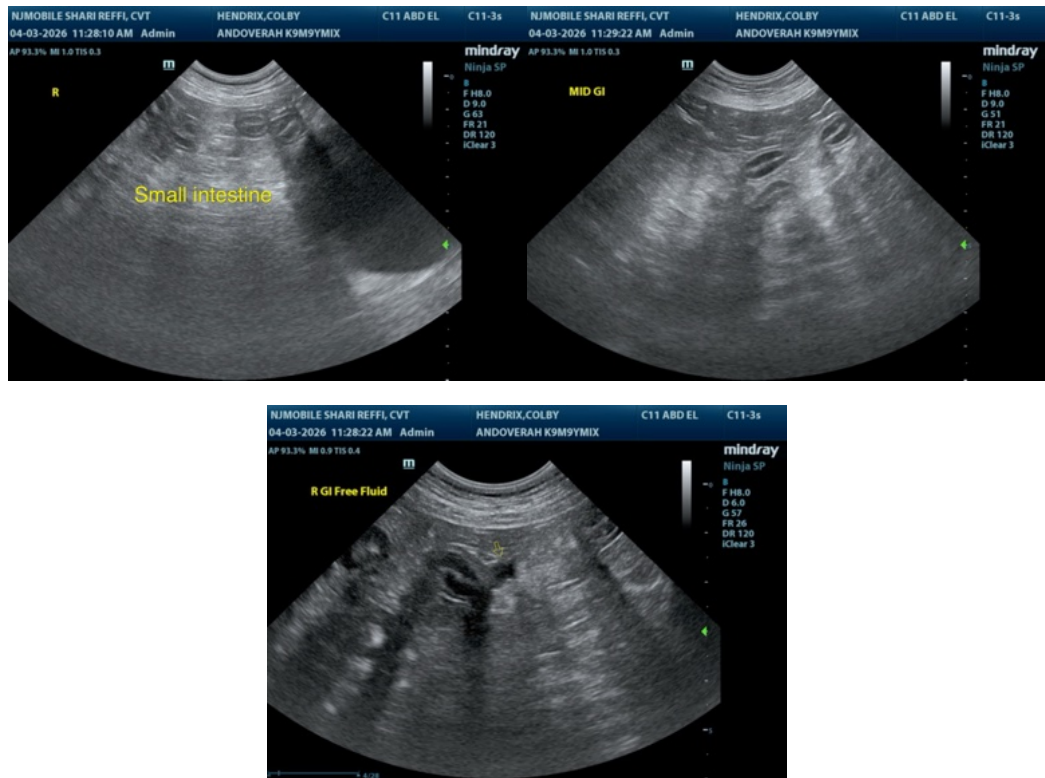
Dr. Lawlor

## INVOICE

74128

## DATE

4/3/26



The information and recommendations provided are based on the images presented by the referring veterinarian/sonographer. No evaluation can be communicated regarding pathology that was not visible in the image/video clips provided.

Thank you for this referral. If the clinical or image interpretation does not parallel your findings or if I can be of any further assistance please contact me.

Remo Lobetti, BVSc, MMedVet (Med), PhD, Dipl. ECVIM (Internal Medicine)

[info@sonopath.com](mailto:info@sonopath.com)