



## PATIENT

Archie De La Rosa  
Michicol

## SPECIES

Canine

## BREED

Beagle

## SEX

Male

## AGE

1 ½ years

## WEIGHT

11.2 kgs

## INTERPRETED BY

Remo Lobetti, BVSc,  
MMedVet (Med),  
PhD, Dipl. ECVIM

## IMAGING PERFORMED BY

Vincent Ravancho, CVT

## HOSPITAL NAME

Bond Vet Union

## REFERRING VET

Dr. Hinds

## INVOICE

74467

## DATE

4/15/26

## PRESENTING CLINICAL SIGNS

History: Chronic intermittent vomiting and diarrhea. Most recent episode, Archie is not eating and lethargic. No significant findings on exam, slightly overweight.

Current medications - Famotidine and Sucralfate

Abnormal PE/Chem/CBC/UA Results: BW WNL

## ULTRASONOGRAPHIC EXAMINATION OF THE ABDOMEN

### *Urinary System*

The urinary bladder is small with a normal thickness and smooth appearance of the wall. Normal anechoic urine with no sediment or uroliths evident.

Normal appearance of the trigone area, proximal urethra, and iliac blood vessels.

Normal appearance and size of the iliac lymph nodes. Ureters not visualized, which can be considered a normal finding.

Normal renal size (left measured 5.4 cm, right measured 5.3 cm), architecture, echogenic appearance, cortico-medullary differentiation, which maintains a 1:3 cortex to medulla ratio, pelvis, and capsule. No infarcts, mineralization or renoliths evident. Normal color flow pattern is evident in both kidneys.

Normal size and appearance of the prostate measuring 1.8 x 2.4 cm in size. Normal size and appearance of both testicles. The left testicle measured 2.9 cm in length and the right testicle measured 2.7 cm in length.

### *Adrenal Glands*

Normal shape, echogenic appearance, size, position, and appearance of the visible peri-adrenal vasculature. Left adrenal gland measured 1.94 cm in length x 0.55 cm and 0.45 cm in width. The right adrenal gland measured 1.62 cm in length x 0.47 cm in width.

### *Spleen*

Normal size and echogenic appearance. Smooth homogenous parenchyma and regular curvilinear capsule. Normal volume of the splenic vasculature without any overt congestion or thrombosis evident. No inflammatory, neoplastic, infarction, or infiltrative changes evident. The spleen measured 1.4 cm in width.

### *Liver*

Normal size, echogenic appearance, portal markings, and regular curvilinear capsule. No nodules or masses evident. Normal appearance of the hepatic and portal vasculature.



## PATIENT

Archie De La Rosa  
Michicol

## SPECIES

Canine

## BREED

Beagle

## SEX

Male

## AGE

1 ½ years

## WEIGHT

11.2 kgs

## INTERPRETED BY

Remo Lobetti, BVSc,  
MMedVet (Med),  
PhD, Dipl. ECVIM

## IMAGING PERFORMED BY

Vincent Ravancho, CVT

## HOSPITAL NAME

Bond Vet Union

## REFERRING VET

Dr. Hinds

## INVOICE

74467

## DATE

4/15/26

## Gallbladder

The gallbladder is full containing normal anechoic bile. Normal thickness and echogenic appearance of the wall. Normal size and appearance of the cystic and common bile duct.

## Gastrointestinal

Normal appearance of the stomach, duodenum, small intestine, ileo-cecal junction, and colon with no loss of layering, 1:3 muscularis to mucosa ratio, normal wall thickness and peristaltic activity, and no distension of the lumen.

## Pancreas

Normal size and echogenic appearance with a regular capsule. Normal echogenic appearance of the mesentery and fat surrounding the pancreas.

## Free Abdomen

Normal mesenteric lymph nodes.

No ascites evident.

## ULTRASONOGRAPHIC FINDINGS

- Normal ultrasound examination of the abdomen.

## INTERPRETATION OF THE FINDINGS & FURTHER RECOMMENDATIONS

On this ultrasound there is no obvious etiology for the presenting clinical signs.

Although the GI tract appears ultrasonographically normal, with the presenting clinical signs an underlying enteropathy such as parasitic enteritis, dietary hypersensitivity and inflammatory bowel disease should still be considered.

Further assessment would be fecal analysis, cobalamin and folate assay and endoscopy of the upper GI tract with biopsies.

Specific therapy would be dependent on an etiological diagnosis.

Symptomatic management that can be considered would be feeding small frequent meals of a novel protein/hypoallergenic diet, course of Fenbendazole, cobalamin supplementation and if there is still not a satisfactory improvement then a course of Prednisolone would then be indicated.



**PATIENT**

Archie De La Rosa Michicol

**SPECIES**

Canine

**BREED**

Beagle

**SEX**

Male

**AGE**

1 ½ years

**WEIGHT**

11.2 kgs

**INTERPRETED BY**

Remo Lobetti, BVSc,  
MMedVet (Med),  
PhD, Dipl. ECVIM

**IMAGING PERFORMED BY**

Vincent Ravancho, CVT

**HOSPITAL NAME**

Bond Vet Union

**REFERRING VET**

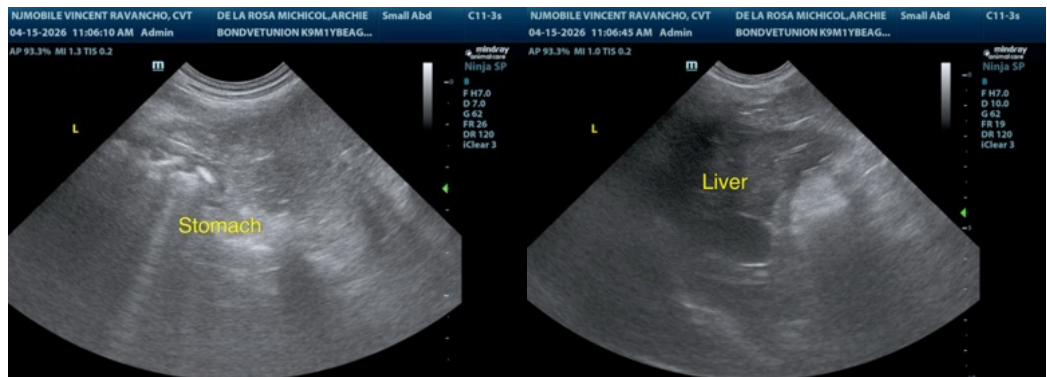
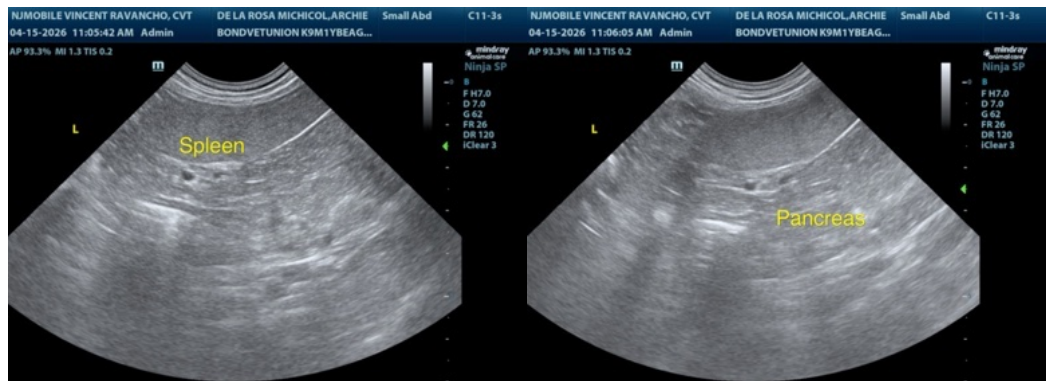
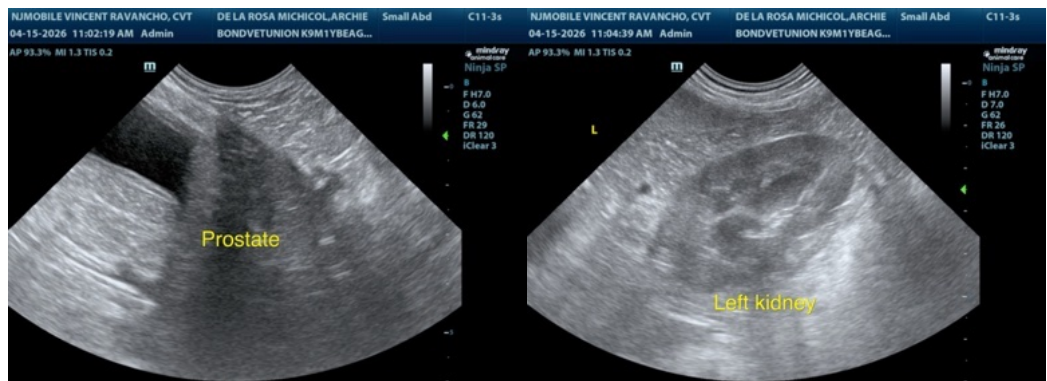
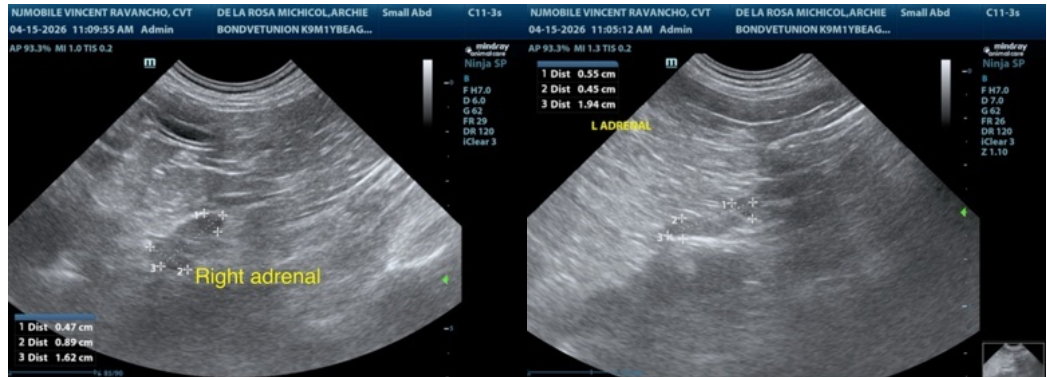
Dr. Hinds

**INVOICE**

74467

**DATE**

4/15/26





## PATIENT

Archie De La Rosa  
Michicol

## SPECIES

Canine

## BREED

Beagle

## SEX

Male

## AGE

1 ½ years

## WEIGHT

11.2 kgs

## INTERPRETED BY

Remo Lobetti, BVSc,  
MMedVet (Med),  
PhD, Dipl. ECVIM

## IMAGING PERFORMED BY

Vincent Ravancho, CVT

## HOSPITAL NAME

Bond Vet Union

## REFERRING VET

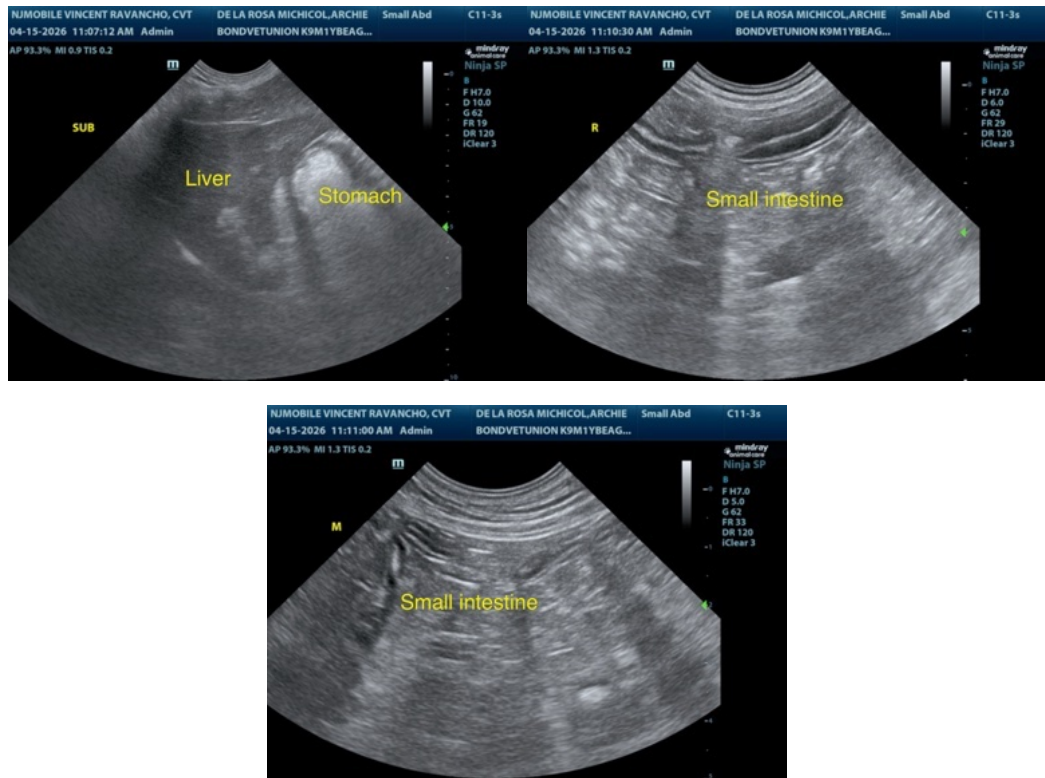
Dr. Hinds

## INVOICE

74467

## DATE

4/15/26



The information and recommendations provided are based on the images presented by the referring veterinarian/sonographer. No evaluation can be communicated regarding pathology that was not visible in the image/video clips provided.

Thank you for this referral. If the clinical or image interpretation does not parallel your findings or if I can be of any further assistance please contact me.

Remo Lobetti, BVSc, MMedVet (Med), PhD, Dipl. ECVIM (Internal Medicine)

[info@sonopath.com](mailto:info@sonopath.com)