



PATIENT

Allie Dollard

SPECIES

Canine

BREED

Labrador

SEX

Female

AGE

6 years

WEIGHT

61 lbs

INTERPRETED BY

Remo Lobetti, BVSc,
MMedVet (Med),
PhD, Dipl. ECVIM

IMAGING PERFORMED BY

Shari Reffi, CVT

HOSPITAL NAME

Smithfield AH

REFERRING VET

Dr. Hull

INVOICE

74459

DATE

4/14/26

PRESENTING CLINICAL SIGNS

History: Evaluate bladder and genital tract for abnormalities, hematuria, dental tartar, blood on vulva.

Current Meds: (Torb/Midaz sedation)

ULTRASONOGRAPHIC EXAMINATION OF THE ABDOMEN

Urinary System

The urinary bladder is small with a normal thickness and smooth appearance of the wall. Normal anechoic urine with no sediment or uroliths evident.

Normal appearance of the trigone area, proximal urethra, and iliac blood vessels.

Normal appearance and size of the iliac lymph nodes. Ureters not visualized, which can be considered a normal finding.

Normal renal size (left measured 5.9 cm, right measured 6.0 cm), architecture, echogenic appearance, cortico-medullary differentiation, which maintains a 1:3 cortex to medulla ratio, pelvis, and capsule. No infarcts, mineralization or renoliths evident. Normal color flow pattern is evident in both kidneys.

Normal size and appearance of the uterine body. The uterine horns are not visualized. Normal size and appearance of both ovaries. The left ovary measured 1.1 x 2.0 cm and the right ovary measured 1.0 x 1.82 cm.

Adrenal Glands

Normal shape, echogenic appearance, size, position, and appearance of the visible peri-adrenal vasculature. Left adrenal gland measured 2.05 cm in length x 0.67 cm and 0.49 cm in width. The right adrenal gland measured 2.35 cm in length x 0.65 cm in width.

Spleen

Normal size and echogenic appearance. Smooth homogenous parenchyma and regular curvilinear capsule. Normal volume of the splenic vasculature without any overt congestion or thrombosis evident. No inflammatory, neoplastic, infarction, or infiltrative changes evident. The spleen measured 2.1 cm in width.

Liver

Normal size, echogenic appearance, portal markings, and regular curvilinear capsule. No nodules or masses evident. Normal appearance of the hepatic and portal vasculature.



PATIENT

Allie Dollard

SPECIES

Canine

BREED

Labrador

SEX

Female

AGE

6 years

WEIGHT

61 lbs

INTERPRETED BY

Remo Lobetti, BVSc,
MMedVet (Med),
PhD, Dipl. ECVIM

IMAGING PERFORMED BY

Shari Reffi, CVT

HOSPITAL NAME

Smithfield AH

REFERRING VET

Dr. Hull

INVOICE

74459

DATE

4/14/26

Gallbladder

The gallbladder is full containing a large amount of non-adhered, hyperechogenic sediment. Normal thickness and echogenic appearance of the wall. Normal size and appearance of the cystic and common bile duct.

Gastrointestinal

Normal appearance of the stomach, duodenum, small intestine, ileo-cecal junction, and colon with no loss of layering, 1:3 muscularis to mucosa ratio, normal wall thickness and peristaltic activity, and no distension of the lumen.

Pancreas

The visible sections of the pancreas are of normal size and echogenic appearance with a regular capsule. Normal echogenic appearance of the mesentery and fat surrounding the pancreas.

Free Abdomen

Normal mesenteric lymph nodes.

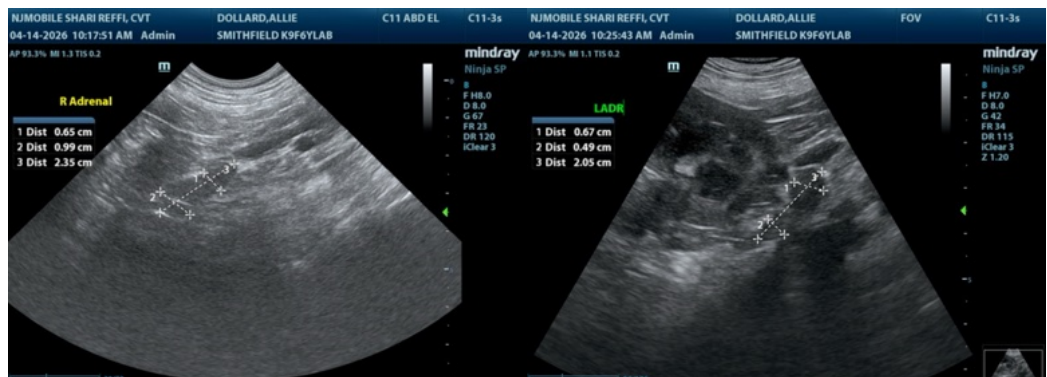
No ascites evident.

ULTRASONOGRAPHIC FINDINGS

- Normal ultrasound examination of the abdomen as gallbladder sediment can be considered an incidental finding.

INTERPRETATION OF THE FINDINGS & FURTHER RECOMMENDATIONS

The most likely etiology for the hematuria and blood present on the vulva would be estrus.





PATIENT

Allie Dollard

SPECIES

Canine

BREED

Labrador

SEX

Female

AGE

6 years

WEIGHT

61 lbs

INTERPRETED BY

Remo Lobetti, BVSc,
MMedVet (Med),
PhD, Dipl. ECVIM

IMAGING PERFORMED BY

Shari Reffi, CVT

HOSPITAL NAME

Smithfield AH

REFERRING VET

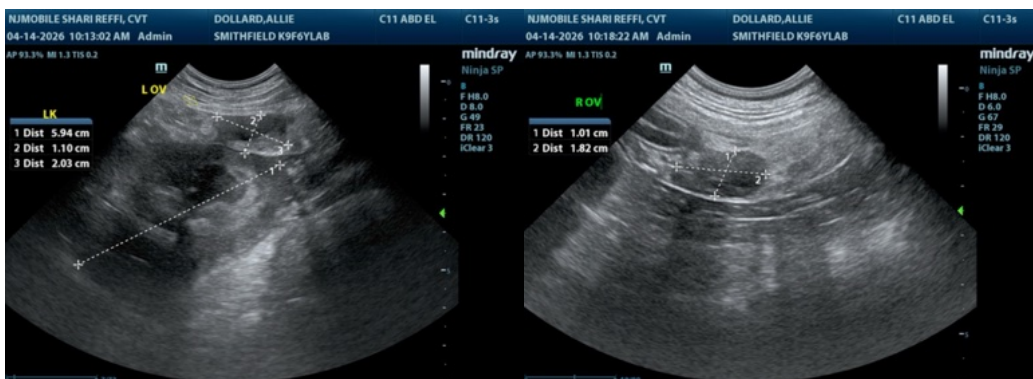
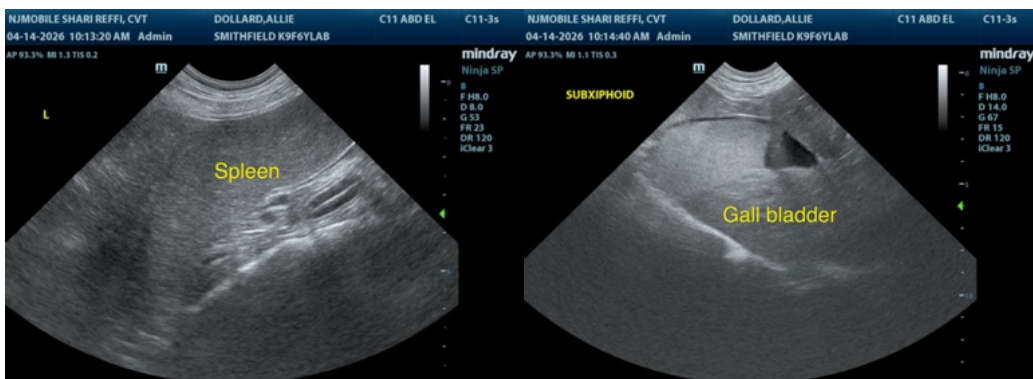
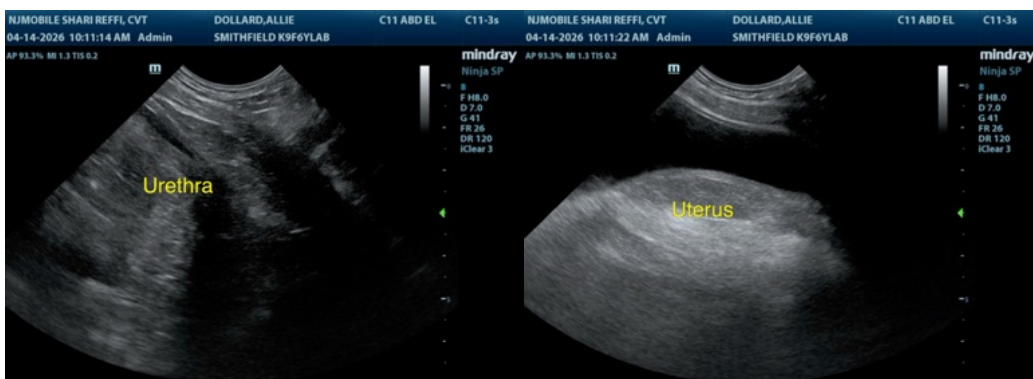
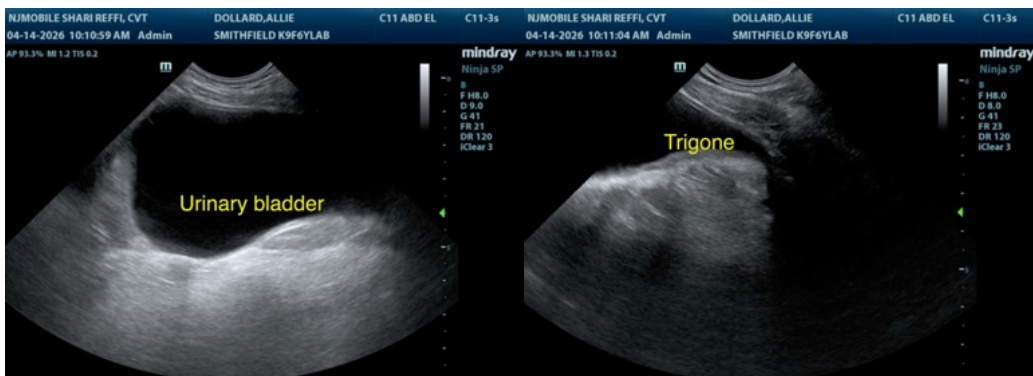
Dr. Hull

INVOICE

74459

DATE

4/14/26





PATIENT

Allie Dollard

SPECIES

Canine

BREED

Labrador

SEX

Female

AGE

6 years

WEIGHT

61 lbs

INTERPRETED BY

Remo Lobetti, BVSc,
MMedVet (Med),
PhD, Dipl. ECVIM

IMAGING PERFORMED BY

Shari Reffi, CVT

HOSPITAL NAME

Smithfield AH

REFERRING VET

Dr. Hull

INVOICE

74459

DATE

4/14/26

The information and recommendations provided are based on the images presented by the referring veterinarian/sonographer. No evaluation can be communicated regarding pathology that was not visible in the image/video clips provided.

Thank you for this referral. If the clinical or image interpretation does not parallel your findings or if I can be of any further assistance please contact me.

Remo Lobetti, BVSc, MMedVet (Med), PhD, Dipl. ECVIM (Internal Medicine)

info@sonopath.com