



## PATIENT

Ringo Hansen

## SPECIES

Canine

## BREED

Pitbull

## SEX

Neutered male

## AGE

11 years

## WEIGHT

80 lbs

## INTERPRETED BY

Remo Lobetti, BVSc,  
MMedVet (Med),  
PhD, Dipl. ECVIM

## IMAGING PERFORMED BY

Kerri Becker

## HOSPITAL NAME

The Venturing Vet

## REFERRING VET

Dr. Herzog

## INVOICE

72229

## DATE

3/5/26

## PRESENTING CLINICAL SIGNS

- Elevated liver enzymes, Grade 4/6 HM
- Denamarin
- ALT-247 ALKP-219

## ULTRASONOGRAPHIC EXAMINATION OF THE ABDOMEN

### *Urinary System*

The urinary bladder is small almost empty a normal thickness and smooth appearance of the wall. Normal anechoic urine with no sediment or uroliths evident.

Normal appearance of the trigone area, proximal urethra, and iliac blood vessels.

Normal appearance and size of the iliac lymph nodes. Ureters not visualized, which can be considered a normal finding.

Normal renal size (left measured 6.5 cm, right measured 6.5 cm), architecture, echogenic appearance, cortico-medullary differentiation, which maintains a 1:3 cortex to medulla ratio, pelvis, and capsule. No infarcts, mineralization or renoliths evident. A normal color flow pattern is evident.

The prostate is small and hypoechogenic measuring 0.9 cm in width.

### *Adrenal Glands*

Normal shape, echogenic appearance, size, position, and appearance of the visible peri-adrenal vasculature. Left adrenal gland measured 2.52 cm in length x 0.54 cm and 0.64 cm in width. The right adrenal gland measured 2.19 cm in length x 0.81 cm and 0.39 cm in width.

### *Spleen*

Normal size and echogenic appearance. Smooth homogenous parenchyma and regular curvilinear capsule. Normal volume of the splenic vasculature without any overt congestion or thrombosis evident. No inflammatory, neoplastic, infarction, or infiltrative changes evident. The spleen measured 2.1 cm in width.

### *Liver*

Normal size, echogenic appearance, portal markings, and regular curvilinear capsule. No nodules or masses evident. Normal appearance of the hepatic and portal vasculature.



**PATIENT**

Ringo Hansen

***Gallbladder***

The gallbladder is not visualized.

**SPECIES**

Canine

***Gastrointestinal***

Normal appearance of the stomach, duodenum, small intestine, ileo-cecal junction, and colon with no loss of layering, 1:3 muscularis to mucosa ratio, normal wall thickness and peristaltic activity, and no distension of the lumen. A moderate amount of ingesta is present in the stomach compatible with a recent meal.

**BREED**

Pitbull

**SEX**

Neutered male

***Pancreas***

The visible sections of the pancreas are of normal size and echogenic appearance with a regular capsule. Normal echogenic appearance of the mesentery and fat surrounding the pancreas.

**AGE**

11 years

**WEIGHT**

80 lbs

***Free Abdomen***

Normal mesenteric lymph nodes.

**INTERPRETED BY**

Remo Lobetti, BVSc,  
MMedVet (Med),  
PhD, Dipl. ECVIM

No ascites evident.

**ULTRASONOGRAPHIC FINDINGS**

- Normal ultrasound examination of the abdomen.

**IMAGING PERFORMED BY**

Kerri Becker

**INTERPRETATION OF THE FINDINGS & FURTHER RECOMMENDATIONS**

On this ultrasound there is no obvious etiology for the mildly elevated liver enzyme activity and may be secondary to the cardiac disease. Other possible etiologies (even though the liver appears ultrasonographically normal) reactive hyperplasia, vacuolar and metabolic.

**HOSPITAL NAME**

The Venturing Vet

Further assessment would be FNA cytology of the liver. A tru cut or wedge biopsy may be required for a final etiological diagnosis.

**REFERRING VET**

Dr. Herzog

Specific therapy would be dependent on an etiological diagnosis.

**INVOICE**

72229

Symptomatic management that can be considered would be the use of Ursodiol with regular monitoring of liver enzyme activity.

**DATE**

3/5/26



**PATIENT**

Ringo Hansen

**SPECIES**

Canine

**BREED**

Pitbull

**SEX**

Neutered male

**AGE**

11 years

**WEIGHT**

80 lbs

**INTERPRETED BY**

Remo Lobetti, BVSc,  
 MMedVet (Med),  
 PhD, Dipl. ECVIM

**IMAGING PERFORMED BY**

Kerri Becker

**HOSPITAL NAME**

The Venturing Vet

**REFERRING VET**

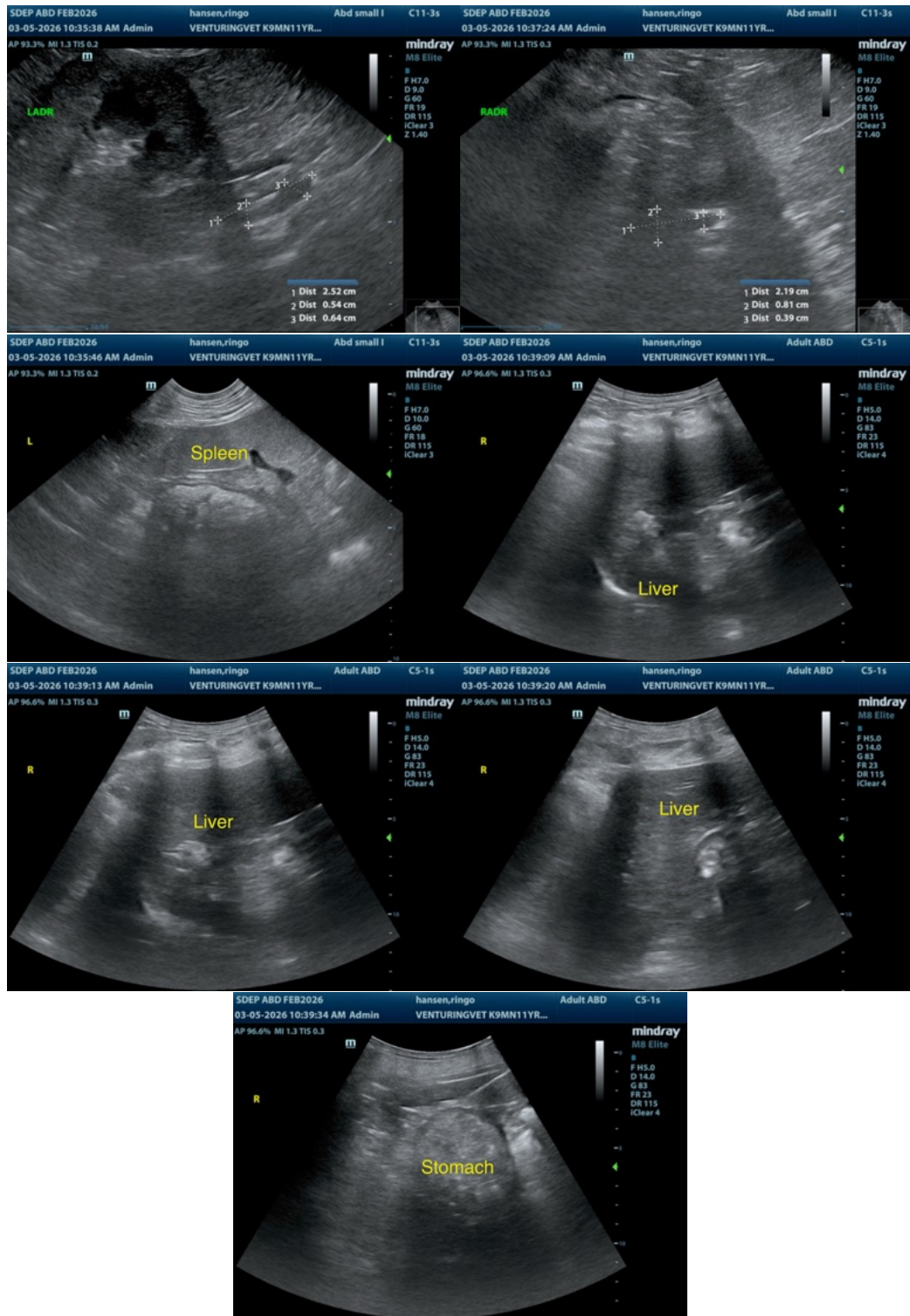
Dr. Herzog

**INVOICE**

72229

**DATE**

3/5/26



The information and recommendations provided are based on the images presented by the referring veterinarian/sonographer. No evaluation can be communicated regarding pathology



**PATIENT**

Ringo Hansen

**SPECIES**

Canine

**BREED**

Pitbull

**SEX**

Neutered male

**AGE**

11 years

**WEIGHT**

80 lbs

**INTERPRETED BY**

Remo Lobetti, BVSc,  
MMedVet (Med),  
PhD, Dipl. ECVIM

**IMAGING  
PERFORMED BY**

Kerri Becker

**HOSPITAL NAME**

The Venturing Vet

**REFERRING VET**

Dr. Herzog

**INVOICE**

72229

**DATE**

3/5/26

**that was not visible in the image/video clips provided.**

Thank you for this referral. If the clinical or image interpretation does not parallel your findings or if I can be of any further assistance please contact me.

**Remo Lobetti, BVSc, MMedVet (Med), PhD, Dipl. ECVIM (Internal Medicine)**

[info@sonopath.com](mailto:info@sonopath.com)