



## PATIENT

Laney Rubin

## SPECIES

Canine

## BREED

Rhodesian Ridgeback

## SEX

Spayed female

## AGE

9 years

## WEIGHT

90.8 lbs

## INTERPRETED BY

Remo Lobetti, BVSc,  
MMedVet (Med),  
PhD, Dipl. ECVIM

## IMAGING PERFORMED BY

Meghan Morse, LVT,  
CVT

## HOSPITAL NAME

Midland Park VH

## REFERRING VET

Dr. Laney

## INVOICE

72232

## DATE

3/5/26

## PRESENTING CLINICAL SIGNS

- Hematuria- persistent
- Perianal mass- cytology revealed perianal gland epithelial proliferation
- Current meds: Simp Trio. Completed course of Clavamox with no change to hematuria
- U/A; protein 2+, blood 3+, RBC >50/hpf

## ULTRASONOGRAPHIC EXAMINATION OF THE ABDOMEN

### *Urinary System*

The urinary bladder is small with a normal thickness and smooth appearance of the wall. A large, hyperechogenic, non-vascularized mass on the apical wall and extended to both the ventral and the dorsal wall. The mass measured 2.6 x 2.7 cm. The rest of the wall is of normal thickness maintaining a smooth appearance. A moderate amount of hyperechogenic sediment is present. There are no uroliths evident.

Normal appearance of the trigone area, proximal urethra, and iliac blood vessels.

Normal appearance and size of the iliac lymph nodes. Ureters not visualized, which can be considered a normal finding.

Normal renal size (left measured 7.9 cm, right measured 8.3 cm), architecture, echogenic appearance, cortico-medullary differentiation, which maintains a 1:3 cortex to medulla ratio, pelvis, and capsule. No infarcts, mineralization or renoliths evident. Normal color flow pattern is evident in both kidneys.

### *Adrenal Glands*

Normal shape, echogenic appearance, size, position, and appearance of the visible peri-adrenal vasculature. Left adrenal gland measured 3.39 cm in length x 0.7 cm and 0.84 cm in width. The right adrenal gland measured 3.47 cm in length x 0.81 cm in width.

### *Spleen*

Normal size and echogenic appearance. Smooth homogenous parenchyma and regular curvilinear capsule. Normal volume of the splenic vasculature without any overt congestion or thrombosis evident. No inflammatory, neoplastic, infarction, or infiltrative changes evident. The spleen measured 2.0 cm in width.

### *Liver*

Normal size, echogenic appearance, portal markings, and regular curvilinear capsule. No nodules or masses evident. Normal appearance of the hepatic and portal vasculature.



**PATIENT**

Laney Rubin

**SPECIES**

Canine

**BREED**

Rhodesian Ridgeback

**SEX**

Spayed female

**AGE**

9 years

**WEIGHT**

90.8 lbs

**INTERPRETED BY**

Remo Lobetti, BVSc,  
MMedVet (Med),  
PhD, Dipl. ECVIM

**IMAGING PERFORMED BY**

Meghan Morse, LVT,  
CVT

**HOSPITAL NAME**

Midland Park VH

**REFERRING VET**

Dr. Laney

**INVOICE**

72232

**DATE**

3/5/26

**Gallbladder**

The gallbladder is full containing normal anechoic bile. Normal thickness and echogenic appearance of the wall. Normal size and appearance of the cystic and common bile duct.

**Gastrointestinal**

Normal appearance of the stomach, duodenum, small intestine, ileo-cecal junction, and colon with no loss of layering, 1:3 muscularis to mucosa ratio, normal wall thickness and peristaltic activity, and no distension of the lumen.

**Pancreas**

Normal size and echogenic appearance with a regular capsule. Normal echogenic appearance of the mesentery and fat surrounding the pancreas.

**Free Abdomen**

Normal mesenteric lymph nodes.

No ascites evident.

**ULTRASONOGRAPHIC FINDINGS**

- Urinary bladder mass.
- Urinary bladder sediment.

**INTERPRETATION OF THE FINDINGS & FURTHER RECOMMENDATIONS**

The most likely etiology for the urinary bladder mass would be neoplasia with granulomatous disease an unlikely differential diagnosis.

The most likely etiology for the urinary bladder sediment would be hematuria as per the patient's history.

Further assessment would be three view thoracic radiographs and possibly BRAF analysis and/or a catheter assisted aspirate/biopsy of the urinary bladder mass. As the mass does not involve the trigone area, surgical resection could be considered.

Alternatively palliative therapy would be indicated.

**Palliative therapy for urinary bladder neoplasia (dog)**

*Medical palliation*

- NSAIDs such as piroxicam (0.3 mg/kg SID), firocoxib 5 mg/kg SID), deracoxib 2–3 mg/kg SID).
- NSAIDs combined with palladia.



**PATIENT**

Laney Rubin

**SPECIES**

Canine

**BREED**

Rhodesian Ridgeback

**SEX**

Spayed female

**AGE**

9 years

**WEIGHT**

90.8 lbs

**INTERPRETED BY**

Remo Lobetti, BVSc,  
MMedVet (Med),  
PhD, Dipl. ECVIM

**IMAGING PERFORMED BY**

Meghan Morse, LVT,  
CVT

**HOSPITAL NAME**

Midland Park VH

**REFERRING VET**

Dr. Laney

**INVOICE**

72232

**DATE**

3/5/26

*Chemotherapy (combined with NSAIDs)*

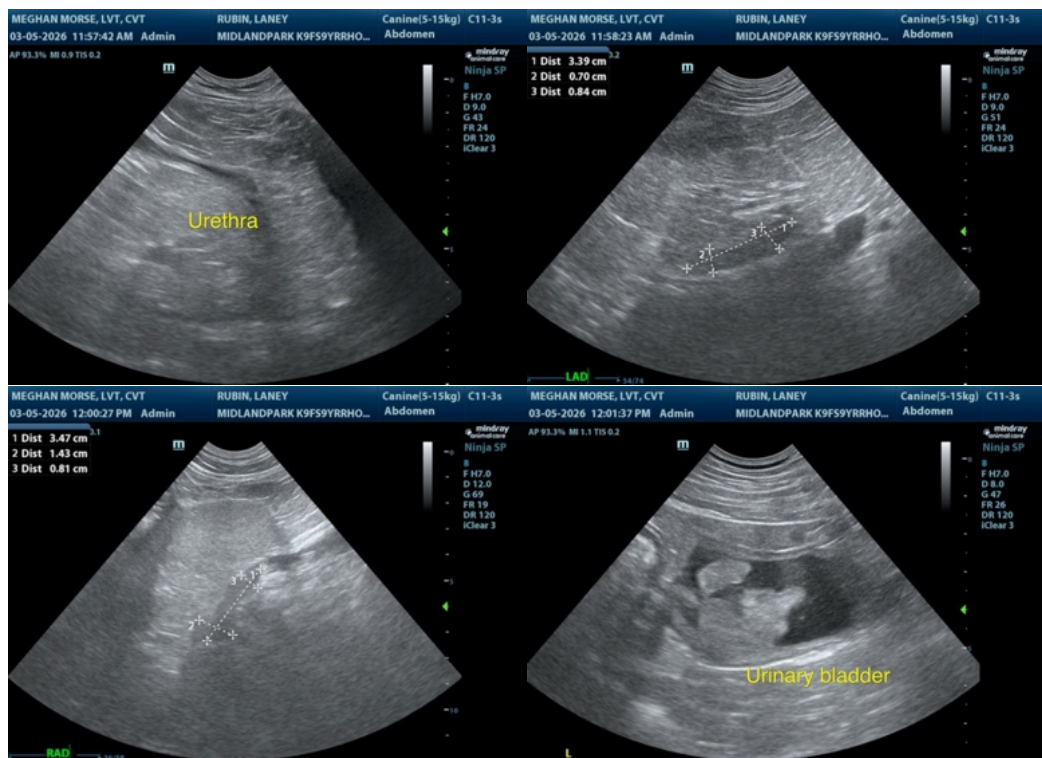
- Mitoxantrone 5–6 mg/m<sup>2</sup> IV q3wk
- Vinblastine 2 mg/m<sup>2</sup> IV q2wk.
- Carboplatin 300 mg/m<sup>2</sup> IV q3–4wk
- Chlorambucil 4 mg/m<sup>2</sup> PO q24–48h.

*Supportive care*

- Pain control: gabapentin ± tramadol.
- Manage dysuria with prazosin or phenoxybenzamine.
- Treat UTIs based on culture.
- Control hematuria with hydration and NSAIDs.
- Manage constipation with lactulose.

*Interventional palliation*

- Urethral stent – relieves obstruction, improves quality of life.
- Cystostomy tube – long-term bladder drainage.
- Palliative radiation – reduces tumor bulk, hematuria, dysuria.
- Laser ablation or debulking.





**PATIENT**

Laney Rubin

**SPECIES**

Canine

**BREED**

Rhodesian Ridgeback

**SEX**

Spayed female

**AGE**

9 years

**WEIGHT**

90.8 lbs

**INTERPRETED BY**

Remo Lobetti, BVSc,  
 MMedVet (Med),  
 PhD, Dipl. ECVIM

**IMAGING PERFORMED BY**

Meghan Morse, LVT,  
 CVT

**HOSPITAL NAME**

Midland Park VH

**REFERRING VET**

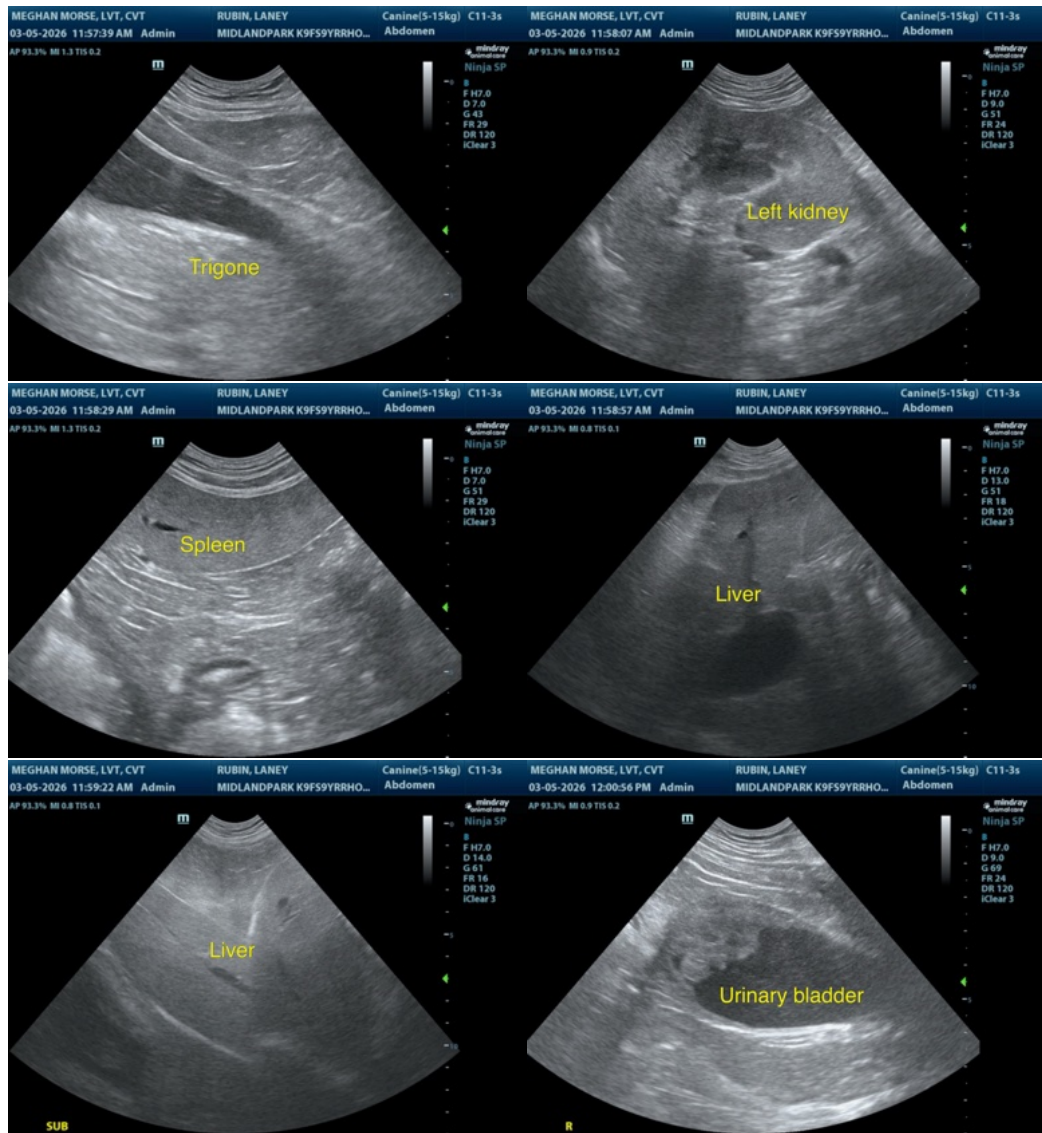
Dr. Laney

**INVOICE**

72232

**DATE**

3/5/26



The information and recommendations provided are based on the images presented by the referring veterinarian/sonographer. No evaluation can be communicated regarding pathology that was not visible in the image/video clips provided.

Thank you for this referral. If the clinical or image interpretation does not parallel your findings or if I can be of any further assistance please contact me.

Remo Lobetti, BVSc, MMedVet (Med), PhD, Dipl. ECVIM (Internal Medicine)  
[info@sonopath.com](mailto:info@sonopath.com)