



PATIENT

Nacho Wojtasek

SPECIES

Canine

BREED

Chihuahua

SEX

Neutered male

AGE

9 years

WEIGHT

-

INTERPRETED BY

Remo Lobetti, BVSc,
MMedVet (Med),
PhD, Dipl. ECVIM

IMAGING PERFORMED BY

Kerri Becker

HOSPITAL NAME

North Jersey AH

REFERRING VET

Dr.

INVOICE

72288

DATE

3/30/26

PRESENTING CLINICAL SIGNS

- WT loss, V+, muscle wasting, Hx GB sx
- Creat-0.1 chol-145

ULTRASONOGRAPHIC EXAMINATION OF THE ABDOMEN

Urinary System

The urinary bladder is full with a normal thickness and smooth appearance of the wall. Normal anechoic urine with no sediment or uroliths evident.

Normal appearance of the trigone area, proximal urethra, and iliac blood vessels.

Normal appearance and size of the iliac lymph nodes. Ureters not visualized, which can be considered a normal finding.

Normal renal size (left measured 3.1 cm, right measured 3.1 cm), architecture, echogenic appearance, cortico-medullary differentiation, which maintains a 1:3 cortex to medulla ratio, pelvis, and capsule. No infarcts, mineralization or renoliths evident. Normal color flow pattern is evident.

The prostate is small and hypoechogenic.

Adrenal Glands

The left adrenal gland is normal in shape, echogenic appearance, size, position, and appearance of the visible peri-adrenal vasculature. Left adrenal gland measured 0.31 cm in length x 0.34 cm and 0.4 cm in width. The right adrenal gland was not clearly visualized, but appears to be of normal shape, echogenic appearance and size.

Spleen

Normal size and echogenic appearance. Smooth homogenous parenchyma and regular curvilinear capsule. Normal volume of the splenic vasculature without any overt congestion or thrombosis evident. No inflammatory, neoplastic, infarction, or infiltrative changes evident. The spleen measured 0.7 cm in width.

Liver

Normal size, echogenic appearance, portal markings, and regular curvilinear capsule. No nodules or masses evident. Normal appearance of the hepatic and portal vasculature.



PATIENT

Nacho Wojtasek

SPECIES

Canine

BREED

Chihuahua

SEX

Neutered male

AGE

9 years

WEIGHT

-

INTERPRETED BY

Remo Lobetti, BVSc,
MMedVet (Med),
PhD, Dipl. ECVIM

IMAGING PERFORMED BY

Kerri Becker

HOSPITAL NAME

North Jersey AH

REFERRING VET

Dr.

INVOICE

72288

DATE

3/30/26

Gallbladder

The gallbladder is absent.

Gastrointestinal

Normal appearance of the stomach, duodenum, small intestine, ileo-cecal junction, and colon with no loss of layering, 1:3 muscularis to mucosa ratio, normal wall thickness and peristaltic activity, and no distension of the lumen.

Pancreas

The visible sections of the pancreas are of normal size and echogenic appearance with a regular capsule. Normal echogenic appearance of the mesentery and fat surrounding the pancreas.

Free Abdomen

Normal mesenteric lymph nodes.

No ascites evident.

ULTRASONOGRAPHIC FINDINGS

- Normal ultrasound examination of the abdomen.

INTERPRETATION OF THE FINDINGS & FURTHER RECOMMENDATIONS

On this ultrasound there is no obvious etiology for the presenting clinical signs.

Although the GI tract appears ultrasonographically normal, with the presenting clinical signs, an underlying enteropathy such as parasitic enteritis, dietary hypersensitivity and inflammatory bowel disease as well as chronic gastritis and Helicobacter gastritis should still be considered.

Further assessment would be fecal analysis, cobalamin and folate assay and endoscopy of the upper GI tract with biopsies.

Specific therapy would be dependent on an etiological diagnosis.

Symptomatic management that can be considered would be feeding small frequent meals of a novel protein/hypoallergenic diet, cobalamin supplementation, course of Fenbendazole and if there is still not a satisfactory improvement then triple therapy for Helicobacter gastritis and if there is still not a satisfactory improvement then a course of Prednisolone would then be indicated.



PATIENT

Nacho Wojtasek

SPECIES

Canine

BREED

Chihuahua

SEX

Neutered male

AGE

9 years

WEIGHT

-

INTERPRETED BY

Remo Lobetti, BVSc,
 MMedVet (Med),
 PhD, Dipl. ECVIM

IMAGING PERFORMED BY

Kerri Becker

HOSPITAL NAME

North Jersey AH

REFERRING VET

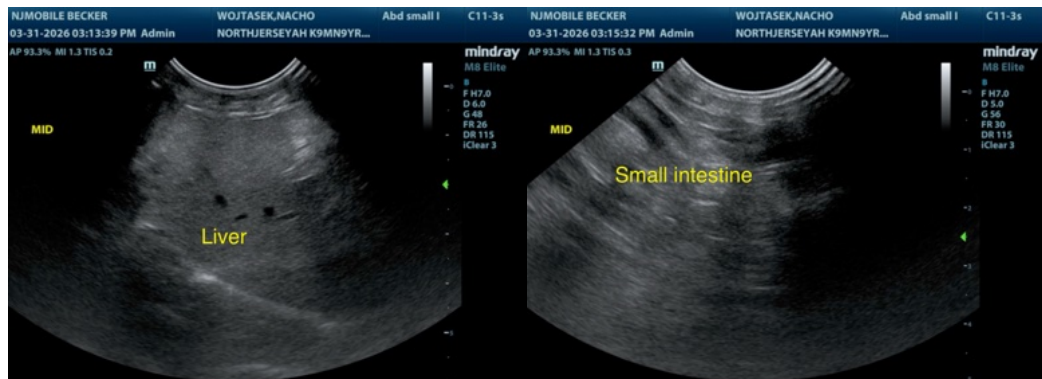
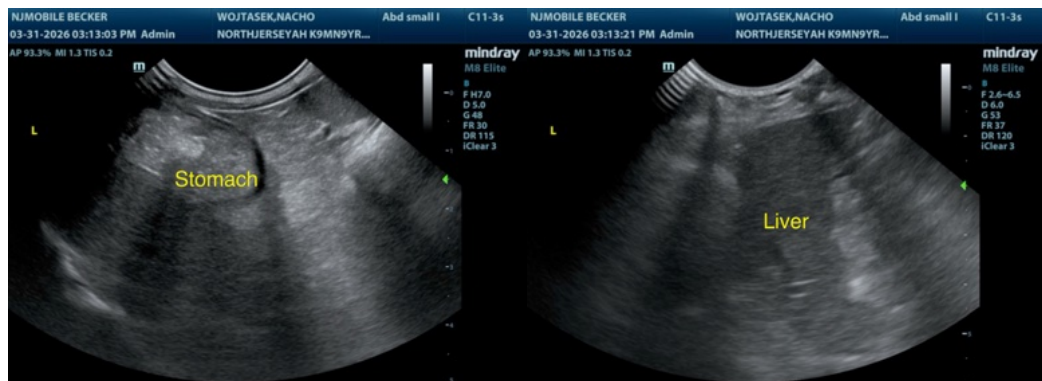
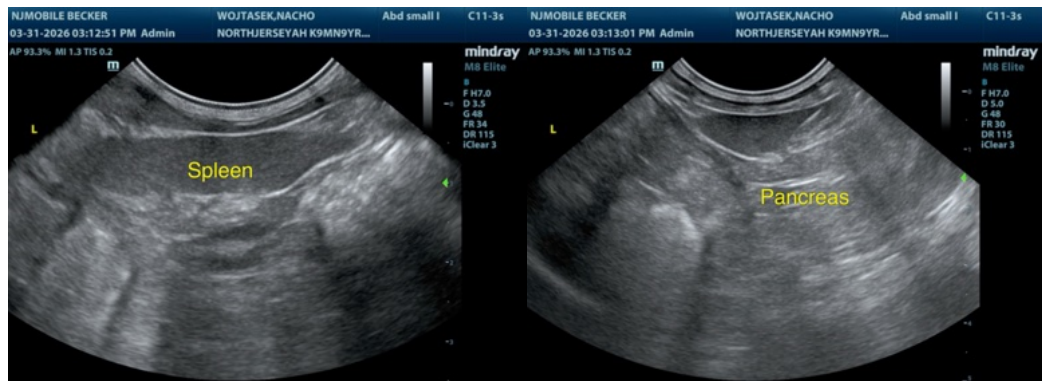
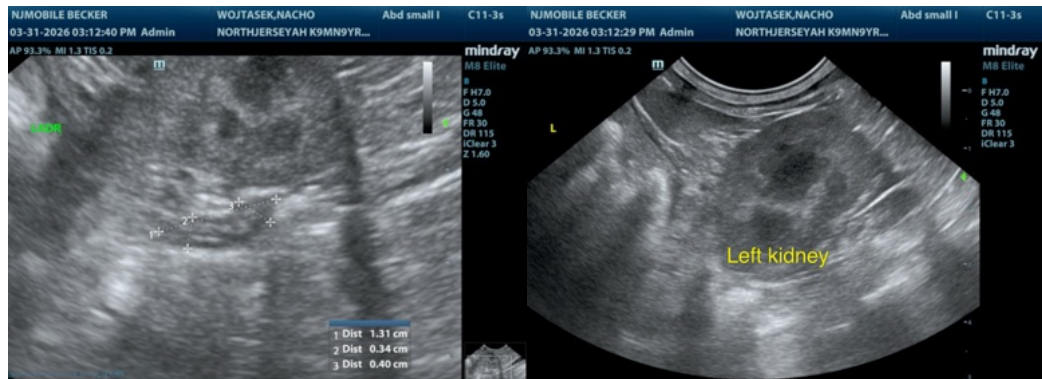
Dr.

INVOICE

72288

DATE

3/30/26





PATIENT

Nacho Wojtasek

SPECIES

Canine

BREED

Chihuahua

SEX

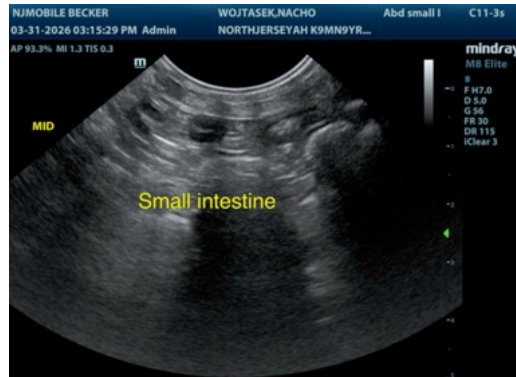Neutered male

AGE

9 years

WEIGHT

-



The information and recommendations provided are based on the images presented by the referring veterinarian/sonographer. No evaluation can be communicated regarding pathology that was not visible in the image/video clips provided.

Thank you for this referral. If the clinical or image interpretation does not parallel your findings or if I can be of any further assistance please contact me.

Remo Lobetti, BVSc, MMedVet (Med), PhD, Dipl. ECVIM (Internal Medicine)

info@sonopath.com

INTERPRETED BY

Remo Lobetti, BVSc,
MMedVet (Med),
PhD, Dipl. ECVIM

IMAGING PERFORMED BY

Kerri Becker

HOSPITAL NAME

North Jersey AH

REFERRING VET

Dr.

INVOICE

72288

DATE

3/30/26