

## PATIENT

Lucy Marselle

## SPECIES

Canine

## BREED

Australian Cattle Dog

## SEX

Spayed female

## AGE

3 years

## WEIGHT

-

## INTERPRETED BY

Remo Lobetti, BVSc,  
MMedVet (Med),  
PhD, Dipl. ECVIM

## IMAGING PERFORMED BY

Shari Reffi, CVT

## HOSPITAL NAME

Chester AH

## REFERRING VET

Dr. Migliaccio

## INVOICE

78366

## DATE

3/30/26

## PRESENTING CLINICAL SIGNS

- Urinary tract incontinence + anxiety.
- Current Medications DES, was on PPA but was causing vomiting, on PPA 8/24 1st time.
- Lap spay-uterus still present. UA: normal. USG: 1.045

## ULTRASONOGRAPHIC EXAMINATION OF THE ABDOMEN

### *Urinary System*

The urinary bladder is full with a normal thickness and smooth appearance of the wall. Normal anechoic urine with no sediment or uroliths evident.

Normal appearance of the trigone area, proximal urethra, and iliac blood vessels.

Normal appearance and size of the iliac lymph nodes. Ureters not visualized, which can be considered a normal finding.

Normal renal size (left measured 5.3 cm, right measured 4.8 cm), architecture, echogenic appearance, cortico-medullary differentiation, which maintains a 1:3 cortex to medulla ratio, pelvis, and capsule. No infarcts, mineralization or renoliths evident. Normal color flow pattern is evident in both kidneys.

The uterus was not visualized.

### *Adrenal Glands*

Normal shape, echogenic appearance, size, position, and appearance of the visible peri-adrenal vasculature. Left adrenal gland measured 0.44 cm and 0.35 cm in width. The right adrenal gland measured 0.43 cm and 0.7 cm in width.

### *Spleen*

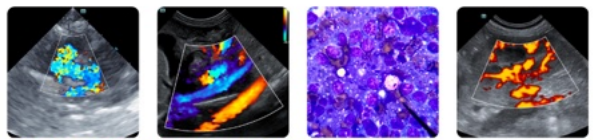
Normal size and echogenic appearance. Smooth homogenous parenchyma and regular curvilinear capsule. Normal volume of the splenic vasculature without any overt congestion or thrombosis evident. No inflammatory, neoplastic, infarction, or infiltrative changes evident. The spleen measured 2.8 cm in width.

### *Liver*

Normal size, echogenic appearance, portal markings, and regular curvilinear capsule. No nodules or masses evident. Normal appearance of the hepatic and portal vasculature.

### *Gallbladder*

The gallbladder is full containing normal anechoic bile. Normal thickness and echogenic appearance of the wall. Normal size and appearance of the cystic and common bile duct.



## PATIENT

Lucy Marselle

## SPECIES

Canine

## BREED

Australian Cattle Dog

## SEX

Spayed female

## AGE

3 years

## WEIGHT

-

## INTERPRETED BY

Remo Lobetti, BVSc,  
MMedVet (Med),  
PhD, Dipl. ECVIM

## IMAGING PERFORMED BY

Shari Reffi, CVT

## HOSPITAL NAME

Chester AH

## REFERRING VET

Dr. Migliaccio

## INVOICE

78366

## DATE

3/30/26

## Gastrointestinal

Normal appearance of the stomach, duodenum, small intestine, ileo-cecal junction, and colon with no loss of layering, 1:3 muscularis to mucosa ratio, normal wall thickness and peristaltic activity, and no distension of the lumen.

## Pancreas

The visible sections of the pancreas are of normal size and echogenic appearance with a regular capsule. Normal echogenic appearance of the mesentery and fat surrounding the pancreas.

## Free Abdomen

Normal mesenteric lymph nodes.

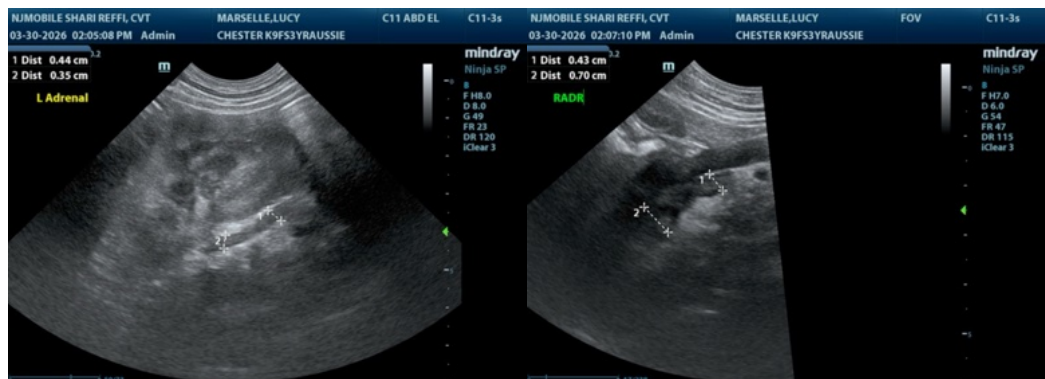
No ascites evident.

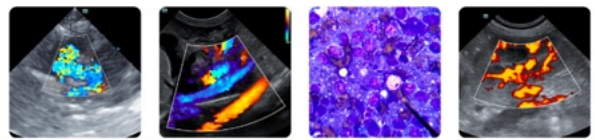
## ULTRASONOGRAPHIC FINDINGS

- Normal ultrasound examination of the abdomen.

## INTERPRETATION OF THE FINDINGS & FURTHER RECOMMENDATIONS

Urinary incontinence in spayed female dogs is common, especially in medium to large breeds. It often develops months to years after spaying and is usually due to hormone-responsive incontinence. Initial management includes phenylpropanolamine and/or estrogen-replacement. In some cases deslorin can be added. In cases that are completely refractory to medical therapy the use of an artificial urethral sphincter (AUS) device should be considered. Maintaining an optimal body weight can also improve the incontinence.





**PATIENT**

Lucy Marselle

**SPECIES**

Canine

**BREED**

Australian Cattle Dog

**SEX**

Spayed female

**AGE**

3 years

**WEIGHT**

-

**INTERPRETED BY**

Remo Lobetti, BVSc,  
MMedVet (Med),  
PhD, Dipl. ECVIM

**IMAGING PERFORMED BY**

Shari Reffi, CVT

**HOSPITAL NAME**

Chester AH

**REFERRING VET**

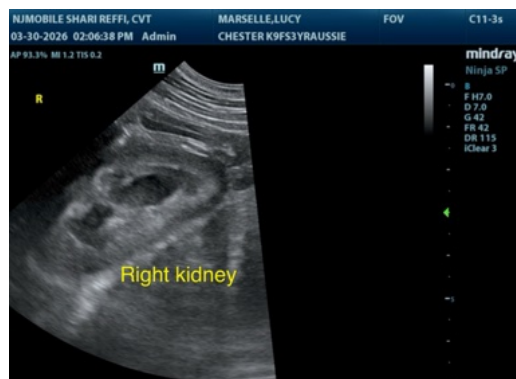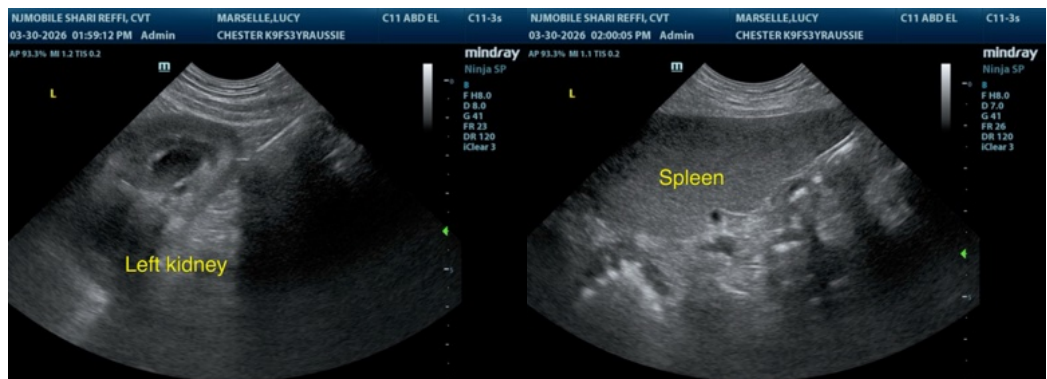
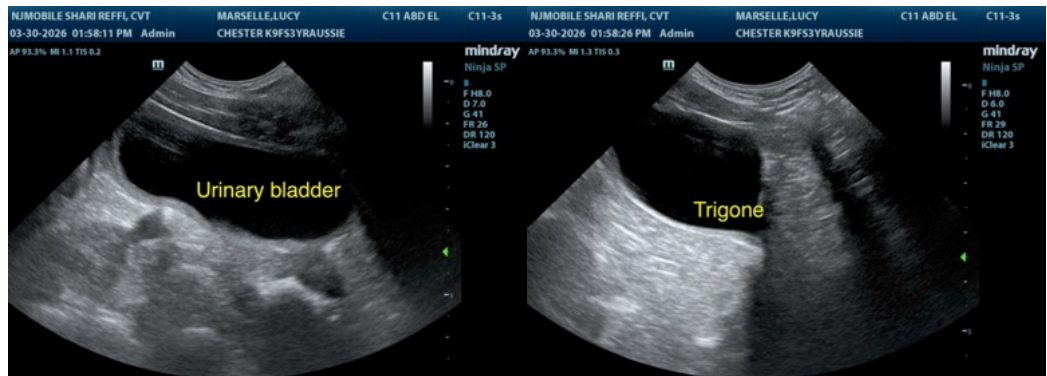
Dr. Migliaccio

**INVOICE**

78366

**DATE**

3/30/26

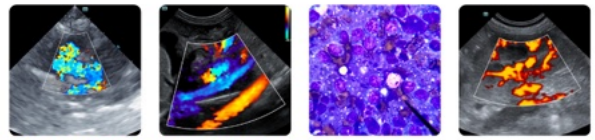


The information and recommendations provided are based on the images presented by the referring veterinarian/sonographer. No evaluation can be communicated regarding pathology that was not visible in the image/video clips provided.

Thank you for this referral. If the clinical or image interpretation does not parallel your findings or if I can be of any further assistance please contact me.

Remo Lobetti, BVSc, MMedVet (Med), PhD, Dipl. ECVIM (Internal Medicine)

[info@sonopath.com](mailto:info@sonopath.com)



## PATIENT

Lucy Marselle

## SPECIES

Canine

## BREED

Australian Cattle Dog

## SEX

Spayed female

## AGE

3 years

## WEIGHT

-

## INTERPRETED BY

Remo Lobetti, BVSc,  
MMedVet (Med),  
PhD, Dipl. ECVIM

## IMAGING PERFORMED BY

Shari Reffi, CVT

## HOSPITAL NAME

Chester AH

## REFERRING VET

Dr. Migliaccio

## INVOICE

78366

## DATE

3/30/26