



PATIENT

Delilah Grossi

SPECIES

Canine

BREED

Lab mix

SEX

Spayed female

AGE

7 years

WEIGHT

66.4 lbs

INTERPRETED BY

Remo Lobetti, BVSc,
 MMedVet (Med),
 PhD, Dipl. ECVIM

IMAGING PERFORMED BY

Shari Reffi, CVT

HOSPITAL NAME

Shohola VH

REFERRING VET

Dr. DeMeo

INVOICE

72146

DATE

3/3/26

PRESENTING CLINICAL SIGNS

- Severe hematuria w no evidence of UTI. Owner found hematuria incidentally on snow.
- Patient has no signs of PU/PD or any dysuria
- current meds: Amoxi/Clav (gaba/traz)
- UA: PH 5.5; 2+ protein; 3+ blood; RBC >50; USG : 1.027

ULTRASONOGRAPHIC EXAMINATION OF THE ABDOMEN

Urinary System

The urinary bladder is full with a normal thickness and smooth appearance of the wall. Normal anechoic urine with no sediment or uroliths evident.

Normal appearance of the trigone area, proximal urethra, and iliac blood vessels.

Normal appearance and size of the iliac lymph nodes. Ureters not visualized, which can be considered a normal finding.

Normal renal size (left measured 6.6 cm, right measured 6.7 cm), architecture, echogenic appearance, cortico-medullary differentiation, which maintains a 1:3 cortex to medulla ratio, pelvis, and capsule. No infarcts, mineralization or renoliths evident.

Adrenal Glands

Normal shape, echogenic appearance, size, position, and appearance of the visible peri-adrenal vasculature. Left adrenal gland measured 0.51 cm and 0.52 cm in width. The right adrenal gland measured 1.2 cm in length x 0.72 cm in width.

Spleen

Normal size and echogenic appearance. Smooth homogenous parenchyma and regular curvilinear capsule. Normal volume of the splenic vasculature without any overt congestion or thrombosis evident. No inflammatory, neoplastic, infarction, or infiltrative changes evident. The spleen measured up to 3.1 cm in width.

Liver

Normal size, echogenic appearance, portal markings, and regular curvilinear capsule. No nodules or masses evident. Normal appearance of the hepatic and portal vasculature.

Gallbladder

The gallbladder is full containing normal anechoic bile. Normal thickness and echogenic appearance of the wall. Normal size and appearance of the cystic and common bile duct.



PATIENT

Delilah Grossi

SPECIES

Canine

BREED

Lab mix

SEX

Spayed female

AGE

7 years

WEIGHT

66.4 lbs

INTERPRETED BY

Remo Lobetti, BVSc,
MMedVet (Med),
PhD, Dipl. ECVIM

IMAGING PERFORMED BY

Shari Reffi, CVT

HOSPITAL NAME

Shohola VH

REFERRING VET

Dr. DeMeo

INVOICE

72146

DATE

3/3/26

Gastrointestinal

Normal appearance of the stomach, duodenum, small intestine, ileo-cecal junction, and colon with no loss of layering, 1:3 muscularis to mucosa ratio, normal wall thickness and peristaltic activity, and no distension of the lumen.

Pancreas

The visible sections of the pancreas are of normal size and echogenic appearance with a regular capsule. Normal echogenic appearance of the mesentery and fat surrounding the pancreas.

Free Abdomen

Normal mesenteric lymph nodes.

No ascites evident.

Thorax

Normal appearance of the heart. No pericardial or pleural effusion evident.

ULTRASONOGRAPHIC FINDINGS

- Normal ultrasound examination of the abdomen.

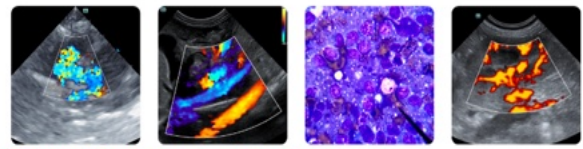
INTERPRETATION OF THE FINDINGS & FURTHER RECOMMENDATIONS

On this ultrasound there is no obvious etiology for the severe hematuria.

Etiologies to consider for the hematuria would be distal urethral pathology, vaginal pathology and possible urinary bladder mucosal ulceration.

Further assessment would be vaginoscopy, contrast urethrogram and/or a contrast retrograde vaginogram. Cystoscopy can also be considered.

Specific therapy would be dependent on an etiological diagnosis.



PATIENT

Delilah Grossi

SPECIES

Canine

BREED

Lab mix

SEX

Spayed female

AGE

7 years

WEIGHT

66.4 lbs

INTERPRETED BY

Remo Lobetti, BVSc,
 MMedVet (Med),
 PhD, Dipl. ECVIM

IMAGING PERFORMED BY

Shari Reffi, CVT

HOSPITAL NAME

Shohola VH

REFERRING VET

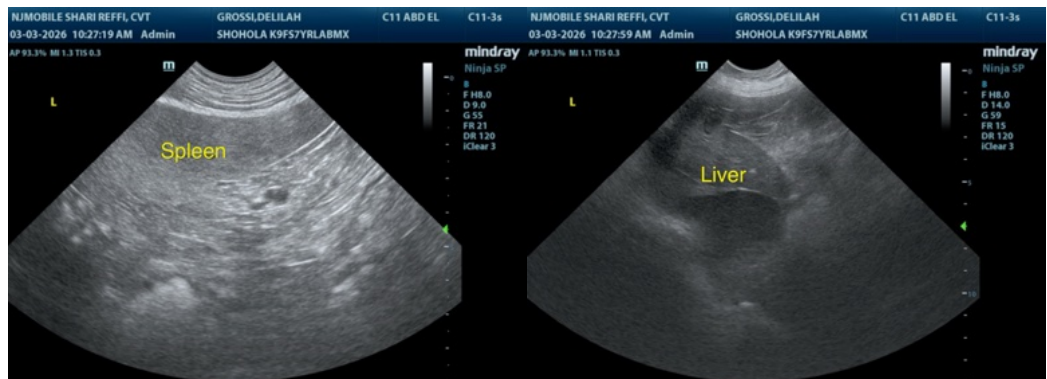
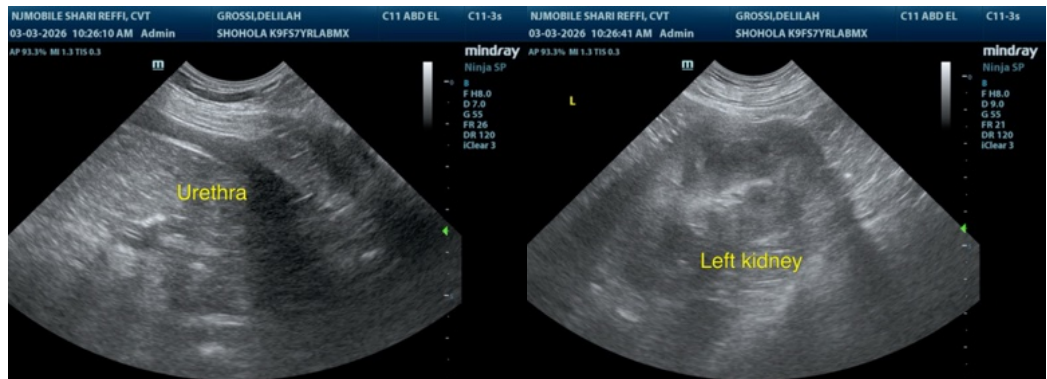
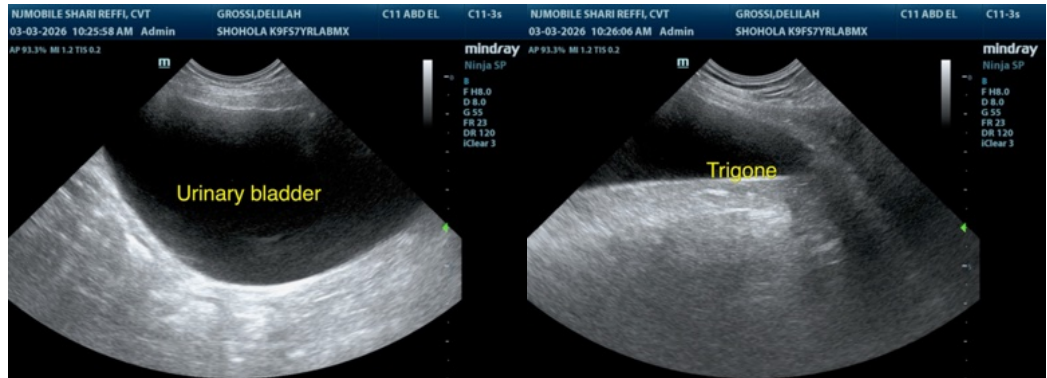
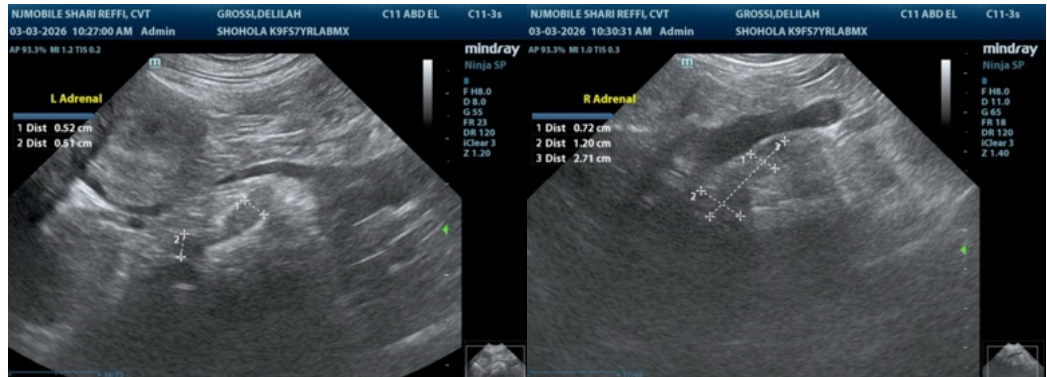Dr. DeMeo

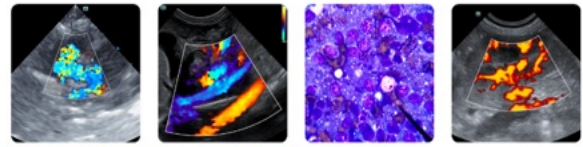
INVOICE

72146

DATE

3/3/26





PATIENT

Delilah Grossi

SPECIES

Canine

BREED

Lab mix

SEX

Spayed female

AGE

7 years

WEIGHT

66.4 lbs

INTERPRETED BY

Remo Lobetti, BVSc,
 MMedVet (Med),
 PhD, Dipl. ECVIM

IMAGING PERFORMED BY

Shari Reffi, CVT

HOSPITAL NAME

Shohola VH

REFERRING VET

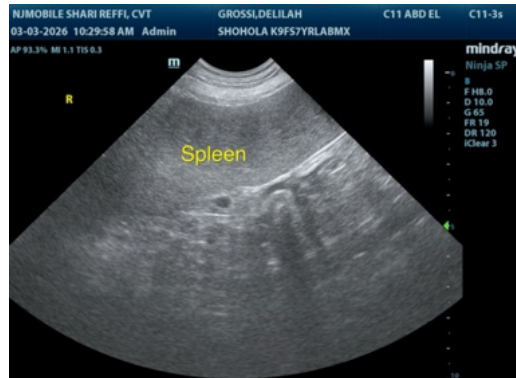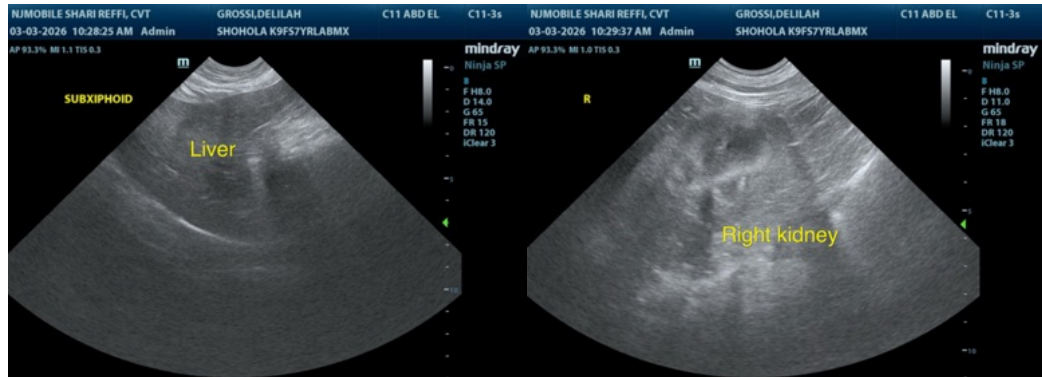
Dr. DeMeo

INVOICE

72146

DATE

3/3/26



The information and recommendations provided are based on the images presented by the referring veterinarian/sonographer. No evaluation can be communicated regarding pathology that was not visible in the image/video clips provided.

Thank you for this referral. If the clinical or image interpretation does not parallel your findings or if I can be of any further assistance please contact me.

Remo Lobetti, BVSc, MMedVet (Med), PhD, Dipl. ECVIM (Internal Medicine)

info@sonopath.com