



PATIENT

Jala Maio

SPECIES

Canine

BREED

Mix

SEX

Spayed female

AGE

13 years

WEIGHT

32 lbs

INTERPRETED BY

Remo Lobetti, BVSc,
MMedVet (Med),
PhD, Dipl. ECVIM

IMAGING PERFORMED BY

Shari Reffi, CVT

HOSPITAL NAME

Magnolia VP

REFERRING VET

Dr. Goldstein

INVOICE

73606

DATE

3/19/26

PRESENTING CLINICAL SIGNS

- BCS 4/9
- chronic LE's elevation
- receiving Clomicalm but liver enz. increased while decreasing med dose
- current meds: Clomicalm, Hepato suppl. ; Trazodone prn
- BUN-32; ALT-521; ALP-1011; GGT-16; Chol-482

ULTRASONOGRAPHIC EXAMINATION OF THE ABDOMEN

Urinary System

The urinary bladder is small with a normal thickness and smooth appearance of the wall. Normal anechoic urine with no sediment or uroliths evident.

Normal appearance of the trigone area, proximal urethra, and iliac blood vessels.

Normal appearance and size of the iliac lymph nodes. Ureters not visualized, which can be considered a normal finding.

Normal renal size (left measured 4.8 cm, right measured 5.0 cm), increased echogenic appearance, some loss of cortico-medullary differentiation, and normal pelvis and capsule. No infarcts, mineralization or renoliths evident. Normal color flow pattern is evident in both kidneys.

Adrenal Glands

Normal shape, echogenic appearance, size, position, and appearance of the visible peri-adrenal vasculature. Left adrenal gland measured 0.56 cm and 0.54 cm in width. The right adrenal gland measured 0.67 cm and 0.55 cm in width.

Spleen

Normal size and echogenic appearance. Smooth homogenous parenchyma and regular curvilinear capsule. Normal volume of the splenic vasculature without any overt congestion or thrombosis evident. No inflammatory, neoplastic, infarction, or infiltrative changes evident. The spleen measured 1.4 cm in width.

Liver

Normal size with a diffuse increased echogenic and coarse appearance, prominent portal markings, and regular curvilinear capsule. No nodules or masses evident. Normal appearance of the hepatic and portal vasculature.



PATIENT

Jala Maio

SPECIES

Canine

BREED

Mix

SEX

Spayed female

AGE

13 years

WEIGHT

32 lbs

INTERPRETED BY

Remo Lobetti, BVSc,
MMedVet (Med),
PhD, Dipl. ECVIM

IMAGING PERFORMED BY

Shari Reffi, CVT

HOSPITAL NAME

Magnolia VP

REFERRING VET

Dr. Goldstein

INVOICE

73606

DATE

3/19/26

Gallbladder

The gallbladder is full containing normal anechoic bile. Normal thickness and echogenic appearance of the wall. Normal size and appearance of the cystic and common bile duct.

Gastrointestinal

Normal appearance of the stomach, duodenum, small intestine, ileo-cecal junction, and colon with no loss of layering, 1:3 muscularis to mucosa ratio, normal wall thickness and peristaltic activity, and no distension of the lumen.

Pancreas

The visible sections of the pancreas are of normal size and echogenic appearance with a regular capsule. Normal echogenic appearance of the mesentery and fat surrounding the pancreas.

Free Abdomen

Normal mesenteric lymph nodes.

No ascites evident.

ULTRASONOGRAPHIC FINDINGS

- Hepatopathy
- Age related renal changes vs early chronic kidney disease.

INTERPRETATION OF THE FINDINGS & FURTHER RECOMMENDATIONS

Etiologies for the hepatopathy would be reactive hyperplasia, early nodular hyperplasia, vacuolar and metabolic with hepatitis and infiltrative neoplasia an unlikely differential diagnosis.

Further assessment would be FNA cytology of the liver; however, a tru cut or wedge biopsy may be required for a final etiological diagnosis.

Symptomatic management that can be considered would be Ursodiol with regular monitoring of liver enzyme activity.



PATIENT

Jala Maio

SPECIES

Canine

BREED

Mix

SEX

Spayed female

AGE

13 years

WEIGHT

32 lbs

INTERPRETED BY

Remo Lobetti, BVSc,
MMedVet (Med),
PhD, Dipl. ECVIM

IMAGING PERFORMED BY

Shari Reffi, CVT

HOSPITAL NAME

Magnolia VP

REFERRING VET

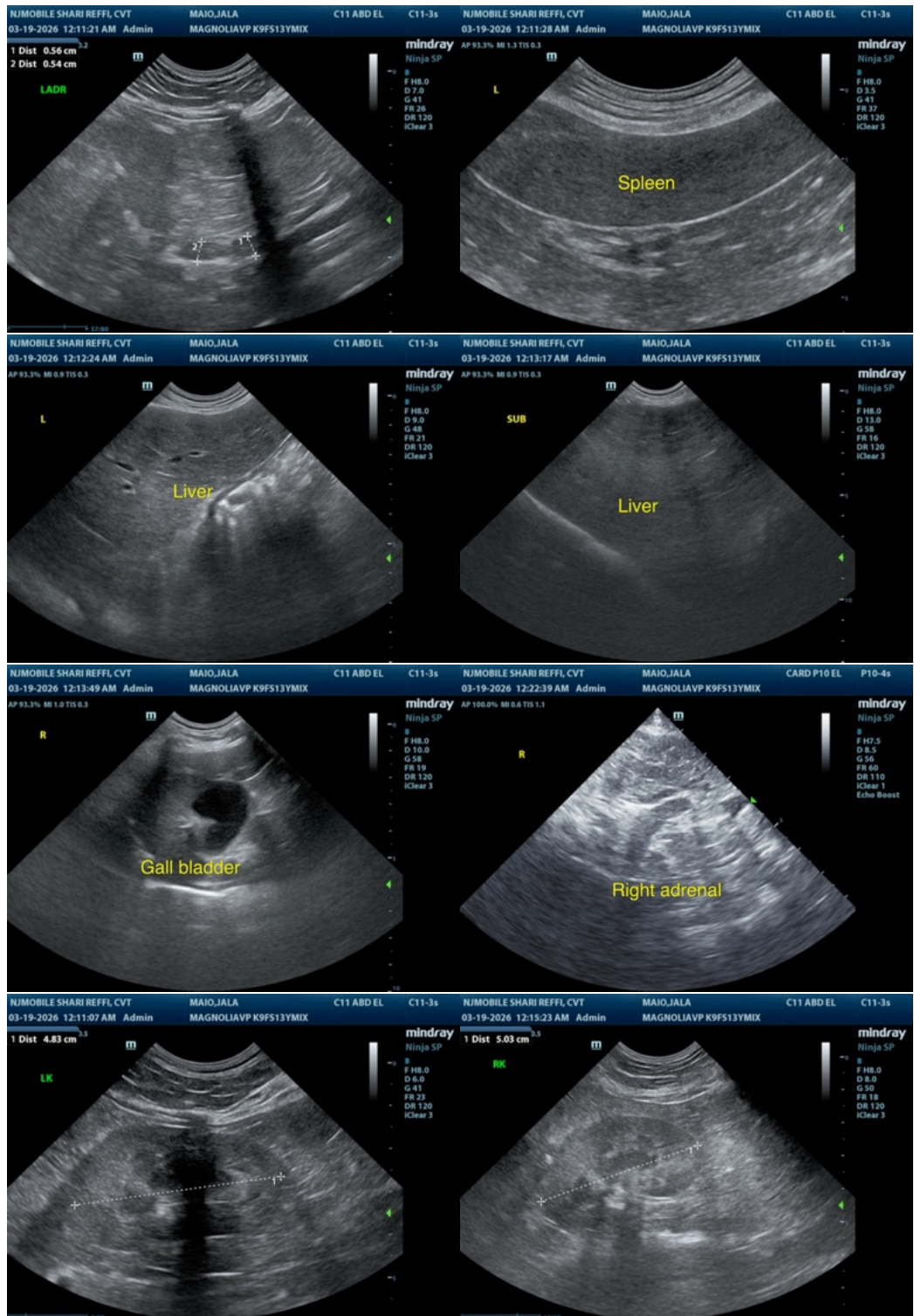
Dr. Goldstein

INVOICE

73606

DATE

3/19/26





PATIENT

Jala Maio

SPECIES

Canine

BREED

Mix

SEX

Spayed female

AGE

13 years

WEIGHT

32 lbs

INTERPRETED BY

Remo Lobetti, BVSc,
MMedVet (Med),
PhD, Dipl. ECVIM

IMAGING PERFORMED BY

Shari Reffi, CVT

HOSPITAL NAME

Magnolia VP

REFERRING VET

Dr. Goldstein

INVOICE

73606

DATE

3/19/26

The information and recommendations provided are based on the images presented by the referring veterinarian/sonographer. No evaluation can be communicated regarding pathology that was not visible in the image/video clips provided.

Thank you for this referral. If the clinical or image interpretation does not parallel your findings or if I can be of any further assistance please contact me.

Remo Lobetti, BVSc, MMedVet (Med), PhD, Dipl. ECVIM (Internal Medicine)

info@sonopath.com