



## PATIENT

Hazel Polchinski

## SPECIES

Canine

## BREED

Shiba

## SEX

Spayed female

## AGE

5 years

## WEIGHT

32.5 lbs

## INTERPRETED BY

Remo Lobetti, BVSc,  
MMedVet (Med),  
PhD, Dipl. ECVIM

## IMAGING PERFORMED BY

Shari Reffi, CVT

## HOSPITAL NAME

Barton Heights VH

## REFERRING VET

Dr. Candelaris

## INVOICE

73604

## DATE

3/19/26

## PRESENTING CLINICAL SIGNS

- Elevated ALP
- Tachypnea >60 RR
- Current meds: Doxycycline, Temeril P; Gabapentin (Torb/Midaz sedation)
- ALP-1,738; ALT- too high to read

## ULTRASONOGRAPHIC EXAMINATION OF THE ABDOMEN

### *Urinary System*

The urinary bladder is small with a normal thickness and smooth appearance of the wall. Normal anechoic urine with no sediment or uroliths evident.

Normal appearance of the trigone area, proximal urethra, and iliac blood vessels.

Normal appearance and size of the iliac lymph nodes. Ureters not visualized, which can be considered a normal finding.

Normal renal size (left measured 5.3 cm, right measured 5.0 cm), architecture, echogenic appearance, cortico-medullary differentiation, which maintains a 1:3 cortex to medulla ratio, pelvis, and capsule. No infarcts, mineralization or renoliths evident. Normal color flow pattern is evident in both kidneys.

### *Adrenal Glands*

Normal shape, echogenic appearance, size, position, and appearance of the visible peri-adrenal vasculature. Left adrenal gland measured 0.56 cm and 0.42 cm in width. The right adrenal gland measured 0.64 cm and 0.67 cm in width.

### *Spleen*

Normal size and echogenic appearance. Smooth homogenous parenchyma and regular curvilinear capsule. Normal volume of the splenic vasculature without any overt congestion or thrombosis evident. No inflammatory, neoplastic, infarction, or infiltrative changes evident. The spleen measured 1.8 cm in width.

### *Liver*

Normal size with a diffuse, increased echogenic appearance, normal portal markings, and regular curvilinear capsule. No nodules or masses evident. Normal appearance of the hepatic and portal vasculature.



## PATIENT

Hazel Polchinski

## SPECIES

Canine

## BREED

Shiba

## SEX

Spayed female

## AGE

5 years

## WEIGHT

32.5 lbs

## INTERPRETED BY

Remo Lobetti, BVSc,  
MMedVet (Med),  
PhD, Dipl. ECVIM

## IMAGING PERFORMED BY

Shari Reffi, CVT

## HOSPITAL NAME

Barton Heights VH

## REFERRING VET

Dr. Candelaris

## INVOICE

73604

## DATE

3/19/26

## ***Gallbladder***

The gallbladder is full containing normal anechoic bile. Normal thickness and echogenic appearance of the wall. Normal size and appearance of the cystic and common bile duct.

## ***Gastrointestinal***

Normal appearance of the stomach, duodenum, small intestine, ileo-cecal junction, and colon with no loss of layering, 1:3 muscularis to mucosa ratio, normal wall thickness and peristaltic activity, and no distension of the lumen. A small amount of ingesta is present within the stomach compatible with a recent meal.

## ***Pancreas***

The visible sections of the pancreas are of normal size and echogenic appearance with a regular capsule. Normal echogenic appearance of the mesentery and fat surrounding the pancreas.

## ***Free Abdomen***

Normal mesenteric lymph nodes.

No ascites evident.

## **ULTRASONOGRAPHIC FINDINGS**

- Hepatopathy.

## **INTERPRETATION OF THE FINDINGS & FURTHER RECOMMENDATIONS**

With the severely elevated liver enzyme activity, especially ALT the most likely etiology for the hepatopathy would be acute hepatitis such as toxins, viral, bacterial, possibly drug reaction and Leptospirosis.

Further assessment would be Leptospirosis PCR and possibly FNA cytology of the liver.

Specific therapy would be dependent on an etiological diagnosis.

Symptomatic management would be fluid therapy as needed, opioid analgesics, Ursodiol and feeding a good quality protein diet.



**PATIENT**

Hazel Polchinski

**SPECIES**

Canine

**BREED**

Shiba

**SEX**

Spayed female

**AGE**

5 years

**WEIGHT**

32.5 lbs

**INTERPRETED BY**

Remo Lobetti, BVSc,  
MMedVet (Med),  
PhD, Dipl. ECVIM

**IMAGING PERFORMED BY**

Shari Reffi, CVT

**HOSPITAL NAME**

Barton Heights VH

**REFERRING VET**

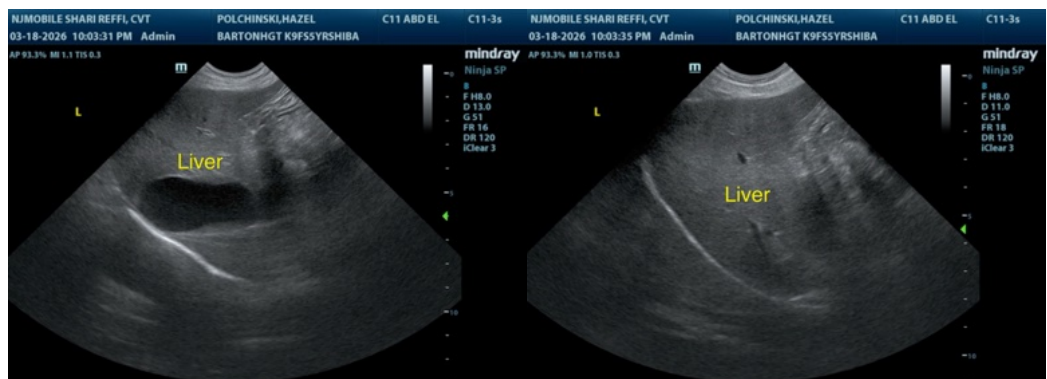
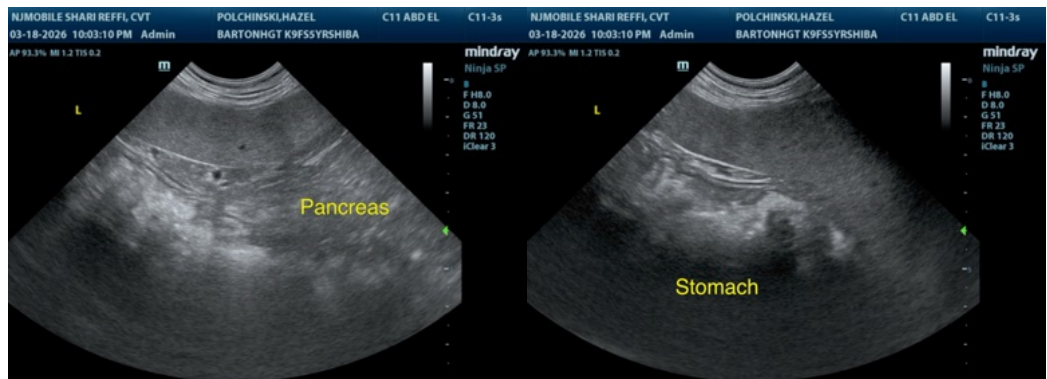
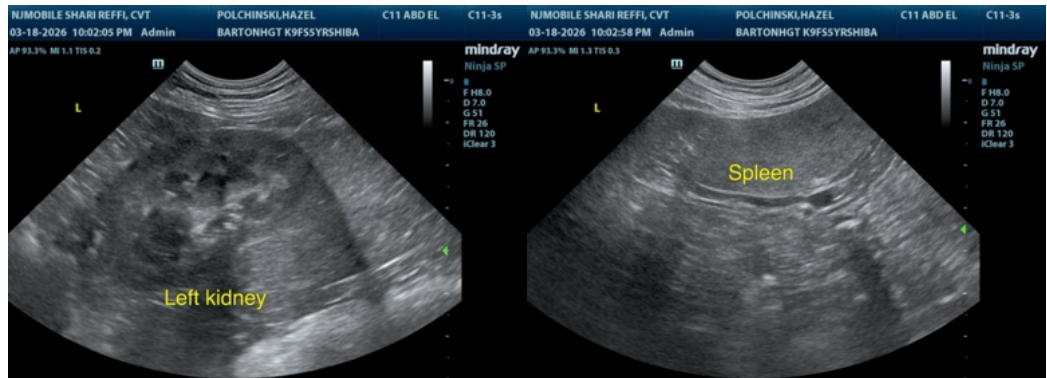
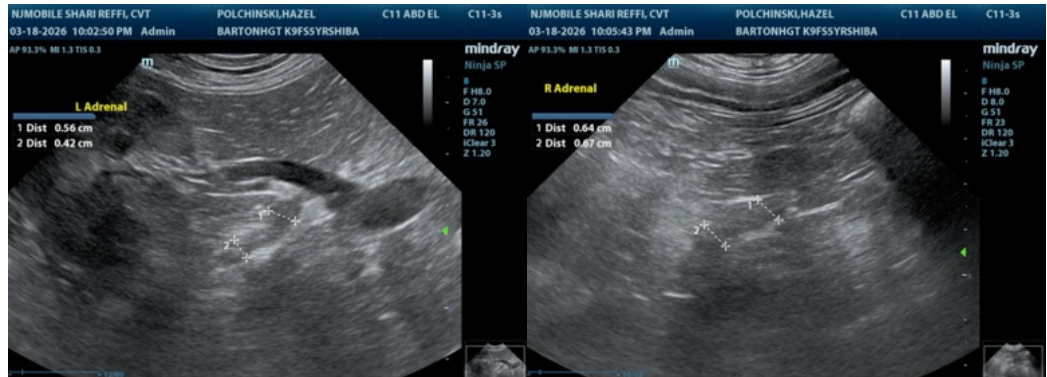
Dr. Candeleris

**INVOICE**

73604

**DATE**

3/19/26





## PATIENT

Hazel Polchinski

## SPECIES

Canine

## BREED

Shiba

## SEX

Spayed female

## AGE

5 years

## WEIGHT

32.5 lbs

## INTERPRETED BY

Remo Lobetti, BVSc,  
MMedVet (Med),  
PhD, Dipl. ECVIM

## IMAGING PERFORMED BY

Shari Reffi, CVT

## HOSPITAL NAME

Barton Heights VH

## REFERRING VET

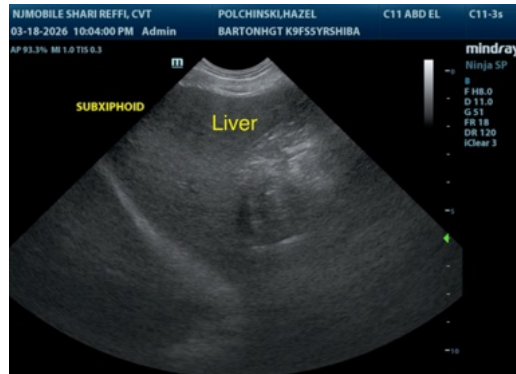Dr. Candelaris

## INVOICE

73604

## DATE

3/19/26



The information and recommendations provided are based on the images presented by the referring veterinarian/sonographer. No evaluation can be communicated regarding pathology that was not visible in the image/video clips provided.

Thank you for this referral. If the clinical or image interpretation does not parallel your findings or if I can be of any further assistance please contact me.

Remo Lobetti, BVSc, MMedVet (Med), PhD, Dipl. ECVIM (Internal Medicine)

[info@sonopath.com](mailto:info@sonopath.com)