



PATIENT

Winston Spencer

SPECIES

Feline

BREED

Domestic Longhair

SEX

Neutered male

AGE

7 months

WEIGHT

2.6 kgs

INTERPRETED BY

Remo Lobetti, BVSc,
MMedVet (Med),
PhD, Dipl. ECVIM

IMAGING PERFORMED BY

Vincent Ravancho, CVT

HOSPITAL NAME

Bondvet Edgewater

REFERRING VET

Dr. Friedman

INVOICE

73499

DATE

3/17/26

PRESENTING CLINICAL SIGNS

- Hx of singular testicle
- Full abdominal explore 1/7/26 - yielded no evidence of additional testicular tissue. Anti Mullerian Hormone testing confirmed lack of second testicle.
- Has been urinating inappropriately on horizontal surfaces in house.
- Gets long with older MN feline sibling (7y/o), has 2 litter boxes.
- O has tried OTC behavioral remedies, r/o medical causes on clinical signs.
- U/A, FIV/FELV, proBNP all pending

ULTRASONOGRAPHIC EXAMINATION OF THE ABDOMEN

Urinary System

The urinary bladder is full with a normal thickness and smooth appearance of the wall. Normal anechoic urine with no sediment or uroliths evident.

Normal appearance of the trigone area, proximal urethra, and iliac blood vessels.

Normal appearance and size of the iliac lymph nodes. Ureters not visualized, which can be considered a normal finding.

Normal renal size (left measured 3.7 cm, right measured 4.2 cm), architecture, echogenic appearance, cortico-medullary differentiation, which maintains a 1:3 cortex to medulla ratio, pelvis, and capsule. No infarcts, mineralization or renoliths evident. Normal color flow pattern is evident in both kidneys.

Adrenal Glands

Normal shape, echogenic appearance, size, position, and appearance of the visible peri-adrenal vasculature. Left adrenal gland measured 0.34 cm in width. The right adrenal gland measured 0.48 cm in width.

Spleen

Normal size and echogenic appearance. Smooth homogenous parenchyma and regular curvilinear capsule. Normal volume of the splenic vasculature without any overt congestion or thrombosis evident. No inflammatory, neoplastic, infarction, or infiltrative changes evident. The spleen measured 0.8 cm in width.

Liver

Normal size, echogenic appearance, portal markings, and regular curvilinear capsule. No nodules or masses evident. Normal appearance of the hepatic and portal vasculature.



PATIENT

Winston Spencer

SPECIES

Feline

BREED

Domestic Longhair

SEX

Neutered male

AGE

7 months

WEIGHT

2.6 kgs

INTERPRETED BY

Remo Lobetti, BVSc,
MMedVet (Med),
PhD, Dipl. ECVIM

IMAGING PERFORMED BY

Vincent Ravancho, CVT

HOSPITAL NAME

Bondvet Edgewater

REFERRING VET

Dr. Friedman

INVOICE

73499

DATE

3/17/26

Gallbladder

The gallbladder is small containing normal anechoic bile. Normal thickness and echogenic appearance of the wall. Normal size and appearance of the cystic and common bile duct.

Gastrointestinal

Normal appearance of the stomach, duodenum, small intestine, ileo-cecal junction, and colon with no loss of layering, 1:3 muscularis to mucosa ratio, normal wall thickness and peristaltic activity, and no distension of the lumen. A moderate amount of ingesta is present within the stomach compatible with a recent meal.

Pancreas

The visible sections of the pancreas are of normal size and echogenic appearance with a regular capsule. Normal echogenic appearance of the mesentery and fat surrounding the pancreas.

Free Abdomen

Normal mesenteric lymph nodes.

No ascites evident.

ULTRASONOGRAPHIC FINDINGS

- Normal ultrasound examination of the abdomen.

INTERPRETATION OF THE FINDINGS & FURTHER RECOMMENDATIONS

On this ultrasound there is no obvious etiology for the presenting clinical signs.

With the presenting clinical signs, the most likely etiology would be feline interstitial/idiopathic cystitis.

Low-grade bacterial cystitis would be a less likely differential diagnosis.

Further assessment if not already done would be urinalysis and urine culture.

Management of feline interstitial/idiopathic cystitis is environmental enrichment and feeding a urinary specific diet.



PATIENT

Winston Spencer

SPECIES

Feline

BREED

Domestic Longhair

SEX

Neutered male

AGE

7 months

WEIGHT

2.6 kgs

INTERPRETED BY

Remo Lobetti, BVSc,
MMedVet (Med),
PhD, Dipl. ECVIM

IMAGING PERFORMED BY

Vincent Ravancho, CVT

HOSPITAL NAME

Bondvet Edgewater

REFERRING VET

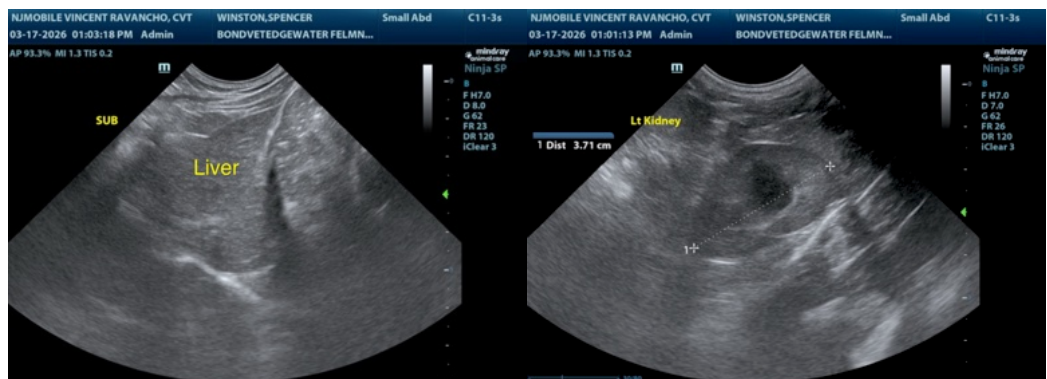
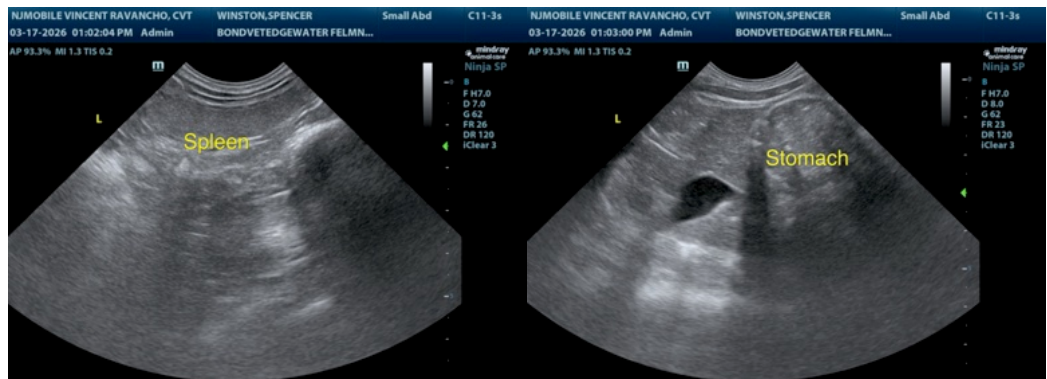
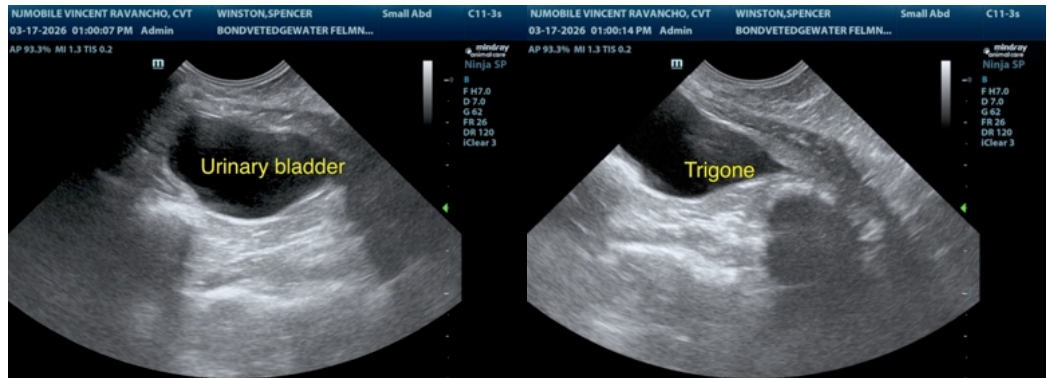
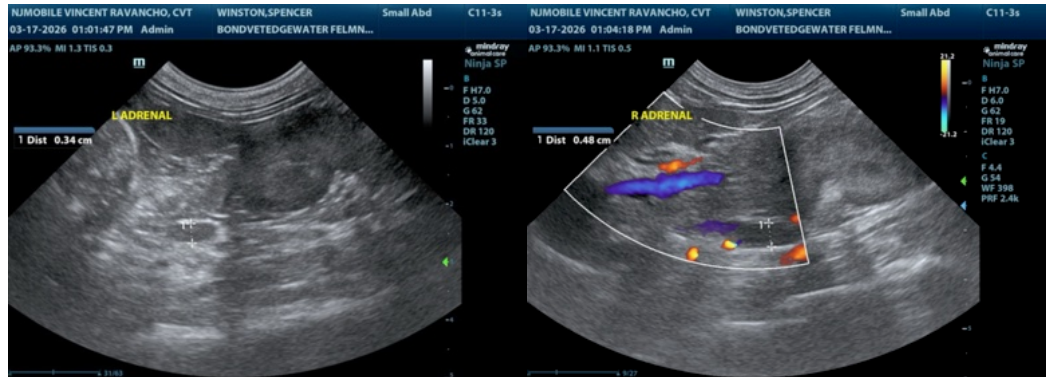
Dr. Friedman

INVOICE

73499

DATE

3/17/26





PATIENT

Winston Spencer

SPECIES

Feline

BREED

Domestic Longhair

SEX

Neutered male

AGE

7 months

WEIGHT

2.6 kgs

INTERPRETED BY

Remo Lobetti, BVSc,
MMedVet (Med),
PhD, Dipl. ECVIM

IMAGING PERFORMED BY

Vincent Ravancho, CVT

HOSPITAL NAME

Bondvet Edgewater

REFERRING VET

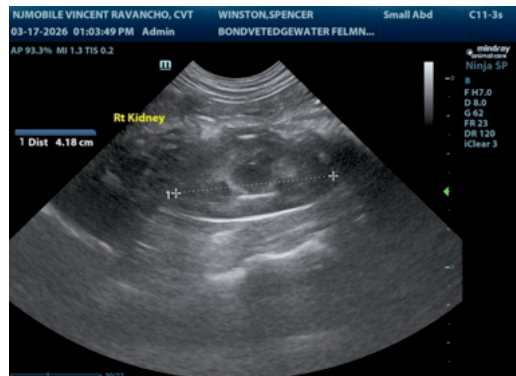Dr. Friedman

INVOICE

73499

DATE

3/17/26



The information and recommendations provided are based on the images presented by the referring veterinarian/sonographer. No evaluation can be communicated regarding pathology that was not visible in the image/video clips provided.

Thank you for this referral. If the clinical or image interpretation does not parallel your findings or if I can be of any further assistance please contact me.

Remo Lobetti, BVSc, MMedVet (Med), PhD, Dipl. ECVIM (Internal Medicine)

info@sonopath.com