



## PATIENT

Dorian DePasquale

## SPECIES

Feline

## BREED

Domestic Shorthair

## SEX

Neutered male

## AGE

14 years

## WEIGHT

11.49 lbs

## INTERPRETED BY

Remo Lobetti, BVSc,  
MMedVet (Med),  
PhD, Dipl. ECVIM

## IMAGING PERFORMED BY

Vincent Ravancho, CVT

## HOSPITAL NAME

All Creatures Great  
and Small Fairfield

## REFERRING VET

Dr. Perez

## INVOICE

73463

## DATE

3/16/26

## PRESENTING CLINICAL SIGNS

- Wt. Loss, Vomiting daily 2x
- WBC 25,000
- Current medications – Gabapentin
- WBC 25,000

## ULTRASONOGRAPHIC EXAMINATION OF THE ABDOMEN

### *Urinary System*

The urinary bladder is full with a normal thickness and smooth appearance of the wall. A small amount of floating, hyperechogenic sediment.

Normal appearance of the trigone area, proximal urethra, and iliac blood vessels.

Normal appearance and size of the iliac lymph nodes. Ureters not visualized, which can be considered a normal finding.

Normal renal size (left measured 4.2 cm, right measured 4.2), architecture, echogenic appearance, cortico-medullary differentiation, which maintains a 1:3 cortex to medulla ratio, pelvis, and capsule. No infarcts, mineralization or renoliths evident. The kidneys had a normal color flow pattern.

### *Adrenal Glands*

Normal shape, echogenic appearance, size, position, and appearance of the visible peri-adrenal vasculature. Left adrenal gland measured 0.34 cm in width. The right adrenal gland measured 0.33 cm in width.

### *Spleen*

Normal size and echogenic appearance. Smooth homogenous parenchyma and regular curvilinear capsule. Normal volume of the splenic vasculature without any overt congestion or thrombosis evident. Incidental myelolipoma is present. No inflammatory, neoplastic, infarction, or infiltrative changes evident. The spleen measured 0.8 cm in width.

### *Liver*

Normal size, echogenic appearance, portal markings, and regular curvilinear capsule. No nodules or masses evident. Normal appearance of the hepatic and portal vasculature.

### *Gallbladder*

The gallbladder is small containing normal anechoic bile. Normal thickness and echogenic appearance of the wall. Normal size and appearance of the cystic and common bile duct.



## PATIENT

Dorian DePasquale

## SPECIES

Feline

## BREED

Domestic Shorthair

## SEX

Neutered male

## AGE

14 years

## WEIGHT

11.49 lbs

## INTERPRETED BY

Remo Lobetti, BVSc,  
MMedVet (Med),  
PhD, Dipl. ECVIM

## IMAGING PERFORMED BY

Vincent Ravancho, CVT

## HOSPITAL NAME

All Creatures Great  
and Small Fairfield

## REFERRING VET

Dr. Perez

## INVOICE

73463

## DATE

3/16/26

## *Gastrointestinal*

Normal appearance of the stomach, duodenum, ileo-cecal junction, and colon with no loss of layering, 1:3 muscularis to mucosa ratio, normal wall thickness and peristaltic activity, and no distension of the lumen. Segmental thickening of the small intestine (up to 0.36 cm) with no loss of layering but with an increase in the muscularis to mucosa ratio, normal peristaltic activity and no distension of the lumen.

## *Pancreas*

The visible sections of the pancreas are of normal size and echogenic appearance with a regular capsule. Normal echogenic appearance of the mesentery and fat surrounding the pancreas.

## *Free Abdomen*

Normal mesenteric lymph nodes.

No ascites evident.

## ULTRASONOGRAPHIC FINDINGS

- Urinary bladder sediment.
- Enteropathy.

## INTERPRETATION OF THE FINDINGS & FURTHER RECOMMENDATIONS

Etiologies for the enteropathy would be parasitic enteritis, dietary hypersensitivity and inflammatory bowel disease with emerging lymphoma a possible differential diagnosis.

The most likely etiology for the urinary bladder sediment would be incidental debris with hematuria, crystalluria and bacterial cystitis a less likely differential diagnosis.

Further assessment would be fecal analysis, cobalamin and folate assay and endoscopy of the upper GI tract with biopsies.

Specific therapy would be dependent on an etiological diagnosis. Symptomatic management that can be considered would be feeding small frequent meals of a novel protein/hypoallergenic diet, course of Fenbendazole, cobalamin supplementation and if there is still not a satisfactory improvement, then a course of Prednisolone would then be indicated.



**PATIENT**

Dorian DePasquale

**SPECIES**

Feline

**BREED**

Domestic Shorthair

**SEX**

Neutered male

**AGE**

14 years

**WEIGHT**

11.49 lbs

**INTERPRETED BY**

Remo Lobetti, BVSc,  
MMedVet (Med),  
PhD, Dipl. ECVIM

**IMAGING PERFORMED BY**

Vincent Ravancho, CVT

**HOSPITAL NAME**

All Creatures Great  
and Small Fairfield

**REFERRING VET**

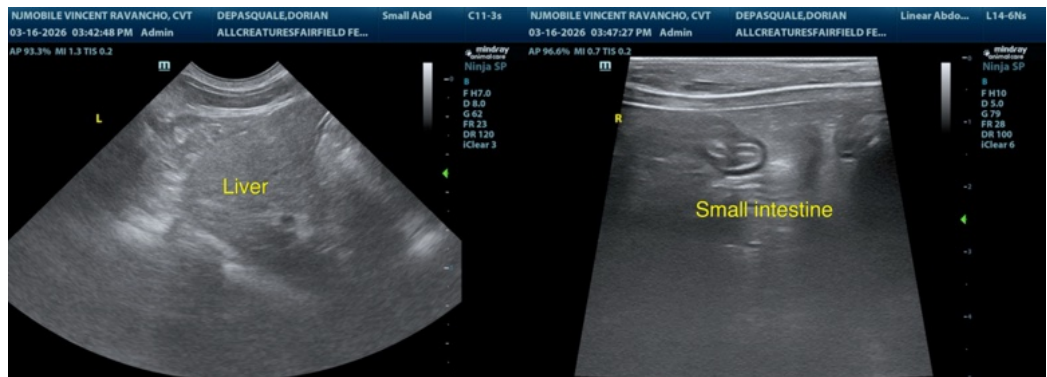
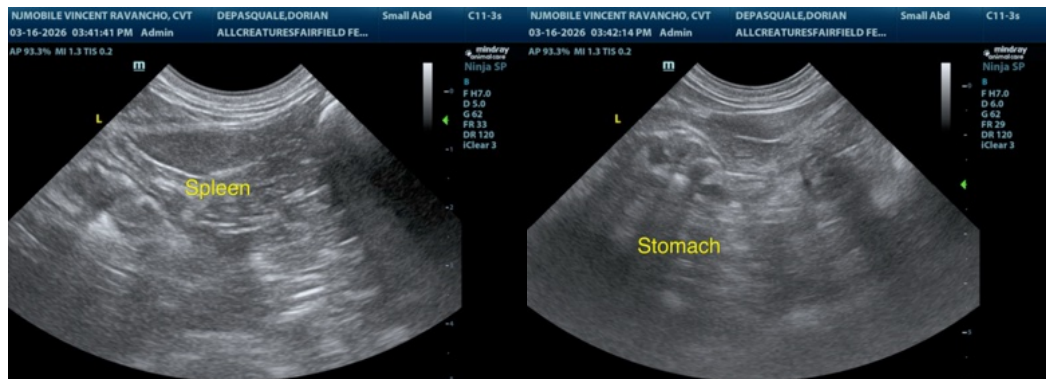
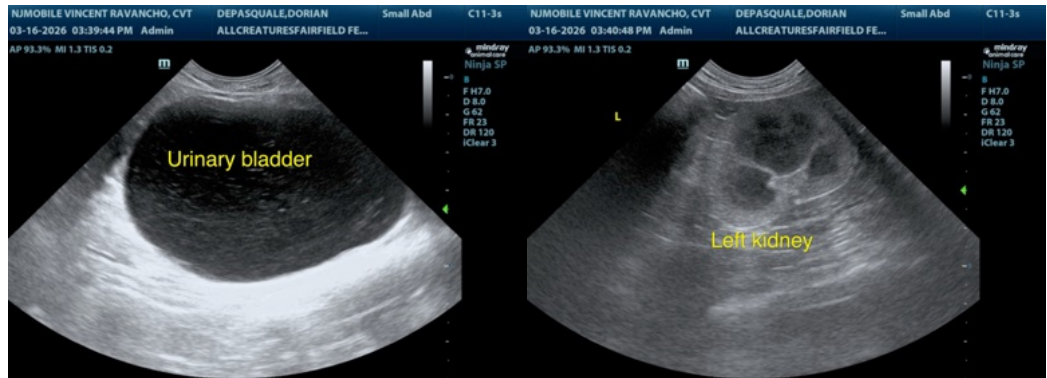
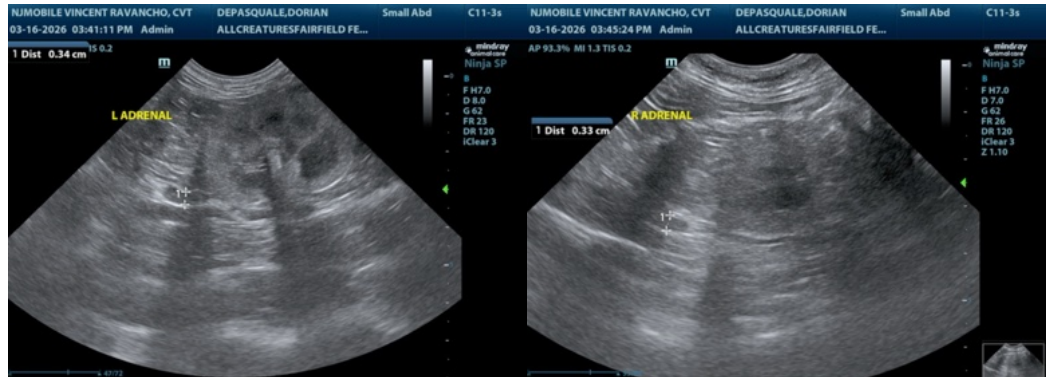
Dr. Perez

**INVOICE**

73463

**DATE**

3/16/26





## PATIENT

Dorian DePasquale

## SPECIES

Feline

## BREED

Domestic Shorthair

## SEX

Neutered male

## AGE

14 years

## WEIGHT

11.49 lbs

## INTERPRETED BY

Remo Lobetti, BVSc,  
MMedVet (Med),  
PhD, Dipl. ECVIM

## IMAGING PERFORMED BY

Vincent Ravancho, CVT

## HOSPITAL NAME

All Creatures Great  
and Small Fairfield

## REFERRING VET

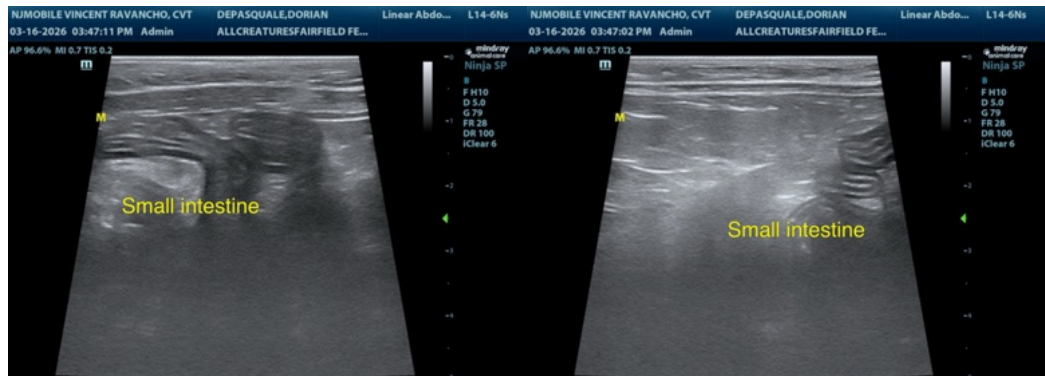Dr. Perez

## INVOICE

73463

## DATE

3/16/26



The information and recommendations provided are based on the images presented by the referring veterinarian/sonographer. No evaluation can be communicated regarding pathology that was not visible in the image/video clips provided.

Thank you for this referral. If the clinical or image interpretation does not parallel your findings or if I can be of any further assistance please contact me.

Remo Lobetti, BVSc, MMedVet (Med), PhD, Dipl. ECVIM (Internal Medicine)

[info@sonopath.com](mailto:info@sonopath.com)