



PATIENT

Brittany Small

SPECIES

Canine

BREED

Irish Terrier

SEX

Spayed female

AGE

9 years

WEIGHT

32 lbs

INTERPRETED BY

Remo Lobetti, BVSc,
MMedVet (Med),
PhD, Dipl. ECVIM

IMAGING PERFORMED BY

Kerri Becker

HOSPITAL NAME

VCA HoHoKus VH

REFERRING VET

Dr. Alipui

INVOICE

73451

DATE

3/12/26

PRESENTING CLINICAL SIGNS

- Increase in liver enzymes
- Moderate dental dz
- ALT-806 ALP-1205 GGT-21 Bile acids Sept 2025 pre-2.3 post-4.0

ULTRASONOGRAPHIC EXAMINATION OF THE ABDOMEN

Urinary System

The urinary bladder is small with a normal thickness and smooth appearance of the wall. Normal anechoic urine with no sediment or uroliths evident.

Normal appearance of the trigone area, proximal urethra, and iliac blood vessels.

Normal appearance and size of the iliac lymph nodes. Ureters not visualized, which can be considered a normal finding.

Normal renal size (left measured 5.3 cm, right measured 5.5 cm), architecture, echogenic appearance, cortico-medullary differentiation, which maintains a 1:3 cortex to medulla ratio, pelvis, and capsule. No infarcts, mineralization or renoliths evident. Normal color flow pattern is evident in both kidneys.

Adrenal Glands

Normal shape, echogenic appearance, size, position, and appearance of the visible peri-adrenal vasculature. Left adrenal gland measured 1.77 cm in length x 0.41 cm and 0.33 cm in width. The right adrenal gland measured 1.59 cm in length x 0.63 cm and 0.29 cm in width.

Spleen

Normal size and echogenic appearance. Smooth homogenous parenchyma and regular curvilinear capsule. Normal volume of the splenic vasculature without any overt congestion or thrombosis evident. No inflammatory, neoplastic, infarction, or infiltrative changes evident. The spleen measured 1.8 cm in width.

Liver

Normal size with a diffuse increased echogenic and coarse appearance, normal portal markings, and regular curvilinear capsule. No nodules or masses evident. Normal appearance of the hepatic and portal vasculature.

Gallbladder

The gallbladder is full containing normal anechoic bile. Normal thickness and echogenic appearance of the wall. Normal size and appearance of the cystic and common bile duct.



PATIENT

Brittany Small

SPECIES

Canine

BREED

Irish Terrier

SEX

Spayed female

AGE

9 years

WEIGHT

32 lbs

INTERPRETED BY

Remo Lobetti, BVSc,
MMedVet (Med),
PhD, Dipl. ECVIM

IMAGING PERFORMED BY

Kerri Becker

HOSPITAL NAME

VCA HoHoKus VH

REFERRING VET

Dr. Alipui

INVOICE

73451

DATE

3/12/26

Gastrointestinal

Normal appearance of the stomach, duodenum, small intestine, ileo-cecal junction, and colon with no loss of layering, 1:3 muscularis to mucosa ratio, normal wall thickness and peristaltic activity, and no distension of the lumen.

Pancreas

The visible sections of the pancreas are of normal size and echogenic appearance with a regular capsule. Normal echogenic appearance of the mesentery and fat surrounding the pancreas.

Free Abdomen

Normal mesenteric lymph nodes.

No ascites evident.

ULTRASONOGRAPHIC FINDINGS

- Hepatopathy.

INTERPRETATION OF THE FINDINGS & FURTHER RECOMMENDATIONS

Etiologies for the hepatopathy would be reactive hyperplasia, vacuolar and metabolic with hepatitis and infiltrative neoplasia highly unlikely differential diagnosis.

Although the adrenal glands appear ultrasonographically normal, with the elevated liver enzyme activity and appearance of the liver, Cushing's disease should still be considered and followed up if there are compatible clinical signs, low urine specific gravity and/or abnormal urine to cortisol to creatinine ratio.

Further assessment of the hepatopathy would be FNA cytology. However, a tru cut or wedge biopsy may be required for a final etiological diagnosis.

Symptomatic management of the hepatopathy would be the use of Ursodiol with regular monitoring of liver enzyme activity.



PATIENT

Brittany Small

SPECIES

Canine

BREED

Irish Terrier

SEX

Spayed female

AGE

9 years

WEIGHT

32 lbs

INTERPRETED BY

Remo Lobetti, BVSc,
 MMedVet (Med),
 PhD, Dipl. ECVIM

IMAGING PERFORMED BY

Kerri Becker

HOSPITAL NAME

VCA HoHoKus VH

REFERRING VET

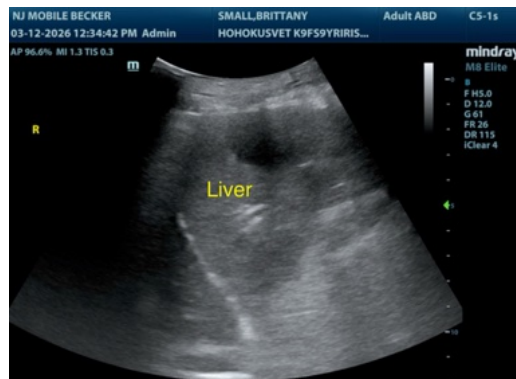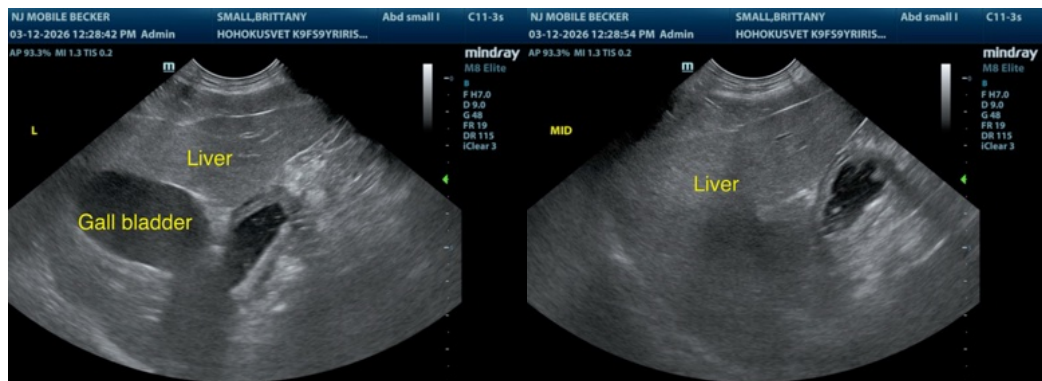
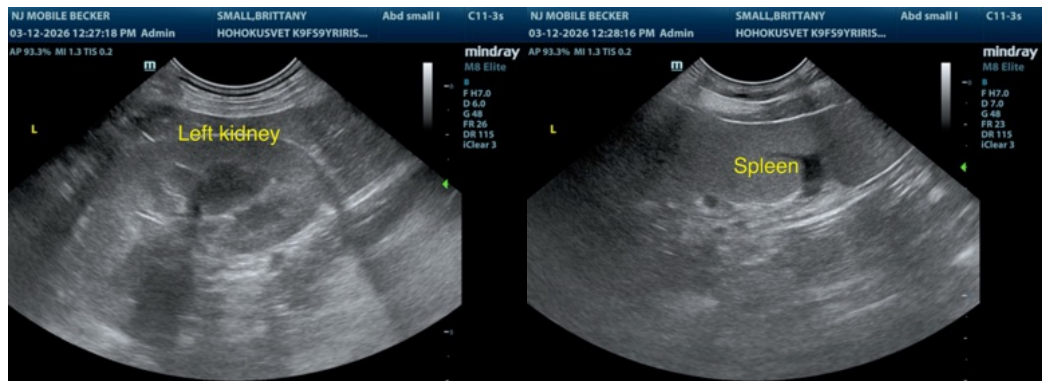
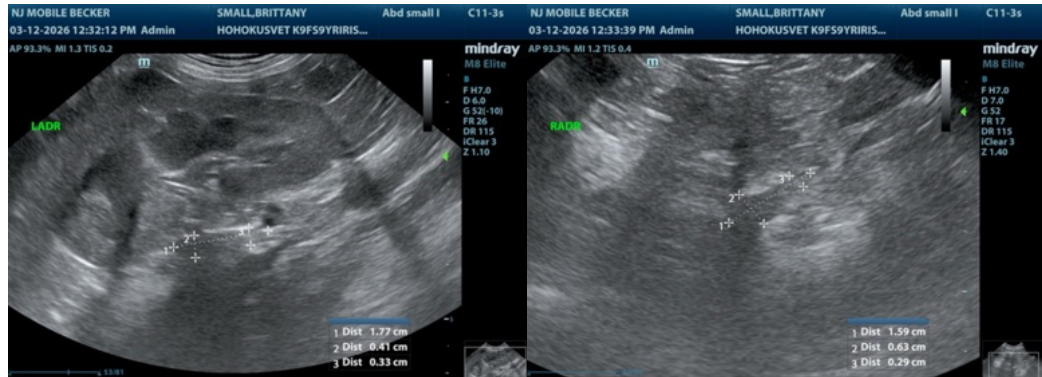
Dr. Alipui

INVOICE

73451

DATE

3/12/26





PATIENT

Brittany Small

SPECIES

Canine

BREED

Irish Terrier

SEX

Spayed female

AGE

9 years

WEIGHT

32 lbs

INTERPRETED BY

Remo Lobetti, BVSc,
MMedVet (Med),
PhD, Dipl. ECVIM

**IMAGING
PERFORMED BY**

Kerri Becker

HOSPITAL NAME

VCA HoHoKus VH

REFERRING VET

Dr. Alipui

INVOICE

73451

DATE

3/12/26

The information and recommendations provided are based on the images presented by the referring veterinarian/sonographer. No evaluation can be communicated regarding pathology that was not visible in the image/video clips provided.

Thank you for this referral. If the clinical or image interpretation does not parallel your findings or if I can be of any further assistance please contact me.

Remo Lobetti, BVSc, MMedVet (Med), PhD, Dipl. ECVIM (Internal Medicine)

info@sonopath.com