



PATIENT

Bailey Darwick

SPECIES

Canine

BREED

Yorkie

SEX

Neutered male

AGE

12 years

WEIGHT

15 lbs

INTERPRETED BY

Remo Lobetti, BVSc,
MMedVet (Med),
PhD, Dipl. ECVIM

IMAGING PERFORMED BY

Kerri Becker

HOSPITAL NAME

Farview AC

REFERRING VET

Dr. Mosaad

INVOICE

73450

DATE

3/12/26

PRESENTING CLINICAL SIGNS

- Cushing dz
- Cortisol sample 1- 7.1 sample 2-4.9

ULTRASONOGRAPHIC EXAMINATION OF THE ABDOMEN

Urinary System

The urinary bladder is small with a normal thickness and smooth appearance of the wall. Normal anechoic urine with no sediment or uroliths evident.

Normal appearance of the trigone area, proximal urethra, and iliac blood vessels.

Normal appearance and size of the iliac lymph nodes. Ureters not visualized, which can be considered a normal finding.

Normal renal size (left measured 4.7 cm, right measured 3.6 cm), increased echogenic appearance, some loss of cortico-medullary differentiation, which maintains a 1:3 cortex to medulla ratio, pelvis, and capsule. No infarcts, mineralization or renoliths evident. Normal color flow pattern is evident in both kidneys.

The prostate is small and hypoechogenic.

Adrenal Glands

Normal shape, echogenic appearance, size, position, and appearance of the visible peri-adrenal vasculature. Left adrenal gland measured 1.56 cm in length x 0.38 cm and 0.28 cm in width. The right adrenal gland measured 1.16 cm in length x 0.55 cm and 0.27 cm in width.

Spleen

Normal size and echogenic appearance. Smooth homogenous parenchyma and regular curvilinear capsule. Normal volume of the splenic vasculature without any overt congestion or thrombosis evident. No inflammatory, neoplastic, infarction, or infiltrative changes evident. The spleen measured 1.4 cm in width.

Liver

Normal size, echogenic appearance, portal markings, and regular curvilinear capsule. No nodules or masses evident. Normal appearance of the hepatic and portal vasculature.



PATIENT

Bailey Darwick

SPECIES

Canine

BREED

Yorkie

SEX

Neutered male

AGE

12 years

WEIGHT

15 lbs

INTERPRETED BY

Remo Lobetti, BVSc,
MMedVet (Med),
PhD, Dipl. ECVIM

IMAGING PERFORMED BY

Kerri Becker

HOSPITAL NAME

Farview AC

REFERRING VET

Dr. Mosaad

INVOICE

73450

DATE

3/12/26

Gallbladder

The gallbladder is small containing normal anechoic bile. Normal thickness and echogenic appearance of the wall. Normal size and appearance of the cystic and common bile duct.

Gastrointestinal

Normal appearance of the stomach, duodenum, small intestine, ileo-cecal junction, and colon with no loss of layering, 1:3 muscularis to mucosa ratio, normal wall thickness and peristaltic activity, and no distension of the lumen.

Pancreas

The visible sections of the pancreas are of normal size and echogenic appearance with a regular capsule. Normal echogenic appearance of the mesentery and fat surrounding the pancreas.

Free Abdomen

Normal mesenteric lymph nodes.

No ascites evident.

ULTRASONOGRAPHIC FINDINGS

- Age related renal changes versus early chronic kidney disease.

INTERPRETATION OF THE FINDINGS & FURTHER RECOMMENDATIONS

Dogs with Cushing's disease may have adrenal glands of normal size and shape on ultrasound, particularly in pituitary-dependent hyperadrenocorticism. This highlights the importance of functional testing over anatomical imaging alone in diagnosing Cushing's disease.

Treatment is not indicated if Cushing's is picked up as an incidental finding or there are minimal clinical signs. Generally, Cushing's is treated when the clinical signs affect or reduce quality of life. Important signs are PU/PD, possibly polyphagia, polynea, muscle weakness and lethargy and especially if the signs are progressive. Treatment should be started if there are associated complications such as hypertension, concurrent diabetes mellitus, thrombo-embolic disease, or recurrent infections.



PATIENT

Bailey Darwick

SPECIES

Canine

BREED

Yorkie

SEX

Neutered male

AGE

12 years

WEIGHT

15 lbs

INTERPRETED BY

Remo Lobetti, BVSc,
 MMedVet (Med),
 PhD, Dipl. ECVIM

IMAGING PERFORMED BY

Kerri Becker

HOSPITAL NAME

Farview AC

REFERRING VET

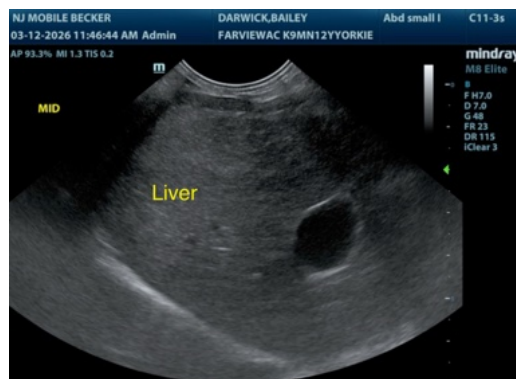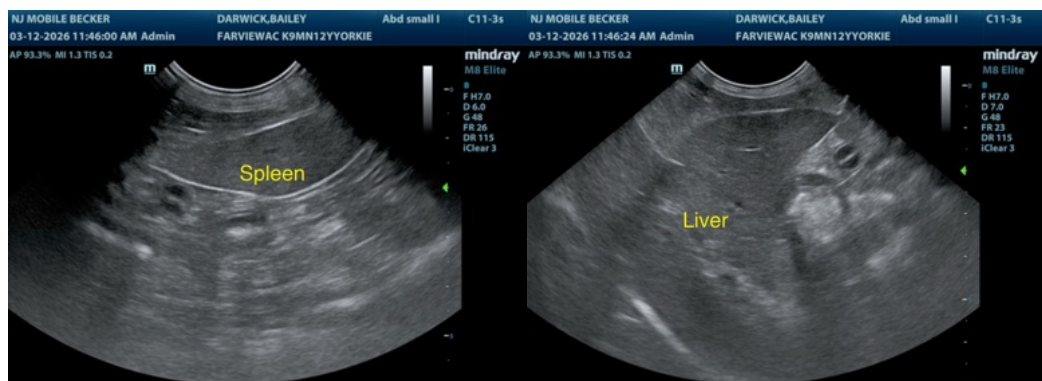
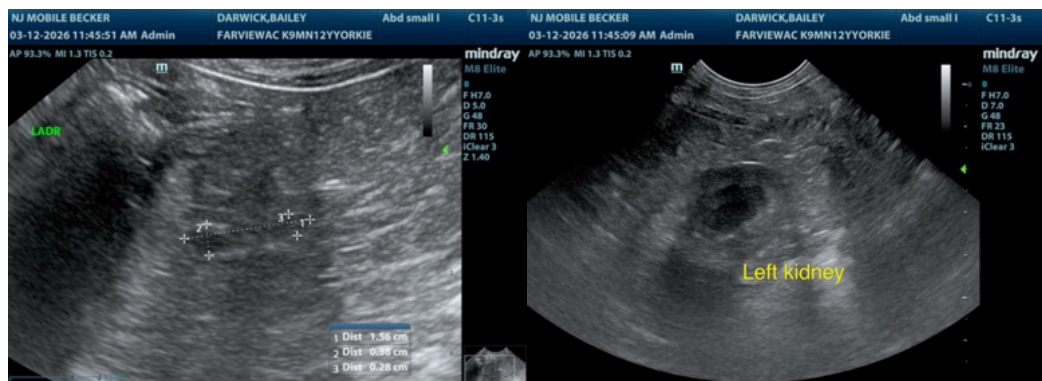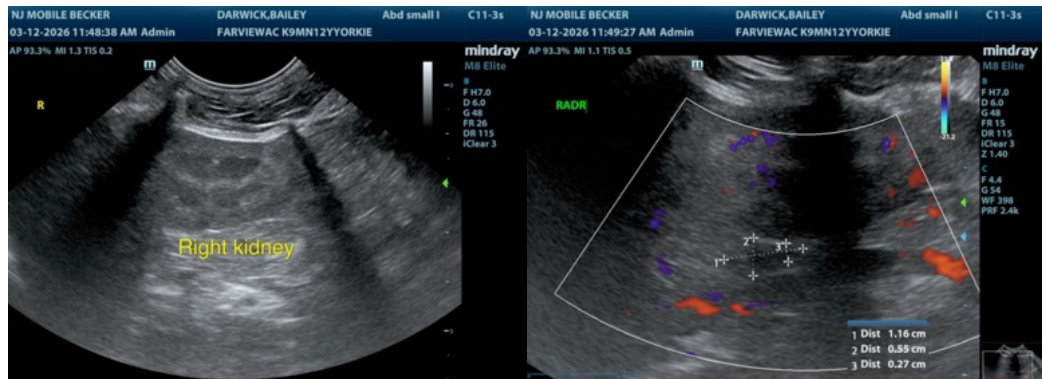
Dr. Mosaad

INVOICE

73450

DATE

3/12/26





PATIENT

Bailey Darwick

SPECIES

Canine

BREED

Yorkie

SEX

Neutered male

AGE

12 years

WEIGHT

15 lbs

INTERPRETED BY

Remo Lobetti, BVSc,
MMedVet (Med),
PhD, Dipl. ECVIM

**IMAGING
PERFORMED BY**

Kerri Becker

HOSPITAL NAME

Farview AC

REFERRING VET

Dr. Mosaad

INVOICE

73450

DATE

3/12/26

The information and recommendations provided are based on the images presented by the referring veterinarian/sonographer. No evaluation can be communicated regarding pathology that was not visible in the image/video clips provided.

Thank you for this referral. If the clinical or image interpretation does not parallel your findings or if I can be of any further assistance please contact me.

Remo Lobetti, BVSc, MMedVet (Med), PhD, Dipl. ECVIM (Internal Medicine)

info@sonopath.com